

PRIMARY SCHOOL (5 - 10 YEARS)

Skin infections constitute the bulk of dermatological problems encountered in primary school children, reflecting developing immunity, expanded contact with other children and vigorous exploration of the outside world.



NELLA GRILO

MB BCh

Registrar

Division of Dermatology

Department of Medicine

University of the Witwatersrand

Nella Grilo is in her final year as a registrar in the Department of Dermatology at the University of the Witwatersrand. Her main interest is in sarcoidosis and the skin.

These infections are much commoner in rural settings, but increasing urbanisation has changed demographic patterns recently. Atopic eczema is the predominant inflammatory dermatosis, and can be very troublesome at this age. Several other important conditions like vitiligo, albinism and trichotillomania might require involvement of school teachers and health care professionals to prevent stigmatisation or sequelae which can be very detrimental in the long run.

ACQUIRED MELANOCYTIC NAEVI

These are abnormal but benign proliferations of melanocytes in the skin (moles), and occur after the neonatal period as tiny brown macules which gradually grow to their final size in early childhood or adolescence. New moles can occur until adulthood, but then the tendency diminishes sharply (Fig. 1). These are generally only removed for cosmetic reasons. Histology should always be obtained, and naevi should never be treated with liquid nitrogen. Irregular and larger naevi could represent dysplastic naevi, and these warrant close follow-up or excision.

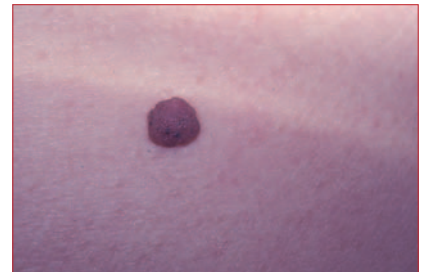

Fig. 1. Intra-dermal acquired melanocytic naevus.

ALBINISM

Albinism is an autosomal recessive congenital defect in the enzyme tyrosinase, which results in a lack of melanin in the skin, hair and eyes. Melanocytes are present, but they contain few, poorly formed melanosomes. Skin is pale and termed type 1 because it burns very easily on exposure to ultraviolet light. Ophthalmological problems like nystagmus and myopia are common in certain types of albinism. Albinism is very common in South Africa, with a carrier rate in the black population of 1:500 (Fig. 2). Cumulative sun damage predisposes to severe solar keratosis, and squamous and basal cell carcinoma in early adulthood: these can be mutilating and fatal. Extreme sun avoidance is critical in the first 18 years of life, with protective clothing and regular use of potent sunscreens on the uncovered parts. Regular skin examinations to detect early skin cancers are important. Schools can play a pivotal role here.

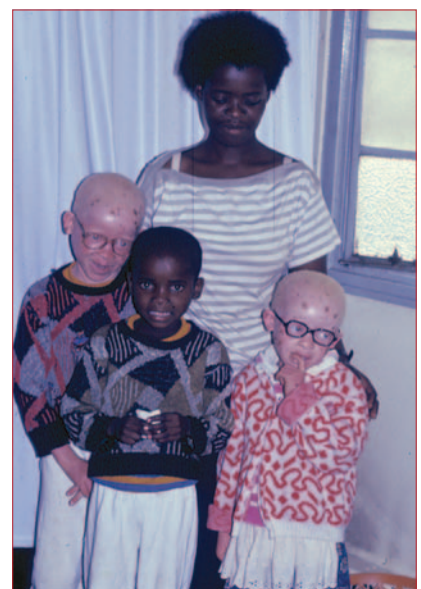

Fig. 2. Albino family.

ATOPIC DERMATITIS

This endogenous eczema often persists into the primary school age, or even occurs *de novo*. Ridicule from other children, or insensitivity on the part of teachers, can cause huge problems with self-esteem, and aggravate the symptoms as well. There might also be an association between atopic disorders and attention deficit. Aggressive treatment is warranted, as intellectual progress can be hampered by continual itching and scratching. The eczema increasingly affects flexural areas like the neck, elbow, knee, wrist and ankle flexures, and a chronic lichenified pattern is typical. Nummular (coin-shaped) eczema is also common (see the article on toddlers for details of treatment, pp. 496 - 498). More severe cases should be referred for azathioprine, cyclosporin or ultraviolet therapy.

ECTHYMA

Also known as veld sore, this is a bacterial infection of the skin which extends to a deeper level than impetigo. Ulcers and crusts are the hallmark of the condition, which heals with scarring (Fig. 3). Both *Staphylococcus aureus* and *Streptococcus pyogenes* cause ecthyma, which is much commoner in rural children, and also in the presence of HIV. Treatment includes an oral antibiotic suitable for both organisms, such as cloxacillin, flucloxacillin, co-amoxycloxacillin or a cephalosporin. Erythromycin and other macrolides are usually satisfactory, but there is increasing resistance by *S. aureus*. Mild cases can be successfully treated with topical antibiotics like mupirocin (Bactroban) or fusidic acid (Fucidin). The crusts should be removed by gentle washing with soap and water, and the ointments applied to the underlying ulcer base. Ecthyma in adults is highly suggestive of immune suppression.

GRANULOMA ANNULARE

Often confused with ringworm, this granulomatous condition of unknown aetiology is quite common in school-aged children. Asymptomatic papules

occur in a ring or annular distribution on the hands, feet, elbows or knees (Fig. 4). The papules are dermal and there is no scaling or surface change, which differentiates it from ringworm. It gradually remits spontaneously, and no treatment is required.

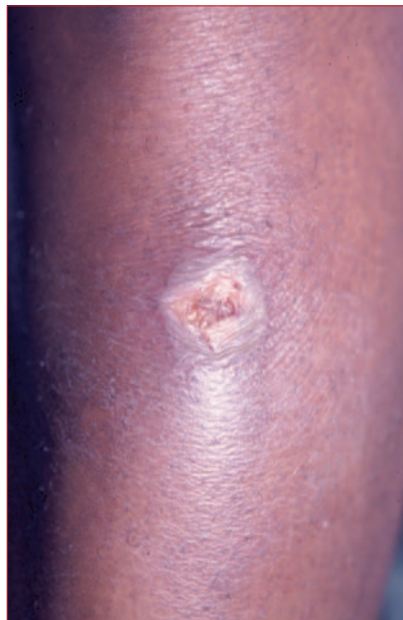

Fig. 3. Ecthyma.

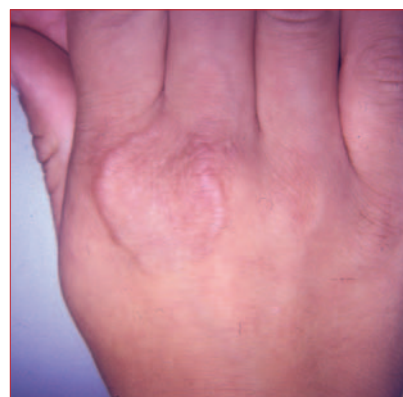

Fig. 4. Granuloma annulare.

HEAD LICE

Head lice, or pediculosis capitis, is caused by the louse *Pediculus humanus capitis*, and occurs in epidemics in schools and institutions regardless of socioeconomic status or hygiene. It is spread by direct contact or via fomites. Pruritus is an important symptom, and the diagnosis is confirmed by finding nits on the hair shafts (Fig. 5) or live adult lice. Secondary impetigo in the occipital region is common. Recommended

treatment is with permethrin (Lyclear crème rinse) which is applied to towel-dried washed hair, left on for 10 minutes, and rinsed. Applications can be repeated a few times. Alternatives include benzyl benzoate, and in adults gamma benzene hexachloride shampoo (Gambex). Nits are best removed with a fine-toothed comb, but do not imply active infection once treated.

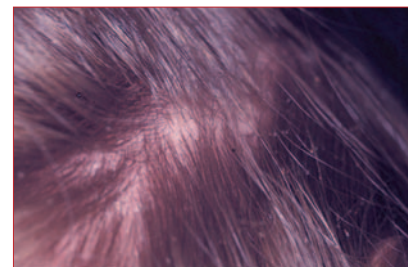


Fig. 5. Head lice.

ICHTHYOSIS VULGARIS

This is the commonest inherited form of ichthyosis, where the skin is very dry and has large fish-like scales. This autosomal dominant condition presents in early childhood with rough, dry, cracked skin (Fig. 6) involving the extensor aspects of the limbs, sparing the elbow and knee flexures. Ichthyosis vulgaris *per se* is not itchy or inflammatory, but can be associated with atopic dermatitis and pruritus. Ichthyosis is resistant to simple moisturisers, and urea (Eulactol, Epimax plus) or lactic acid-containing creams or lotions (Hydralac) are more effective.

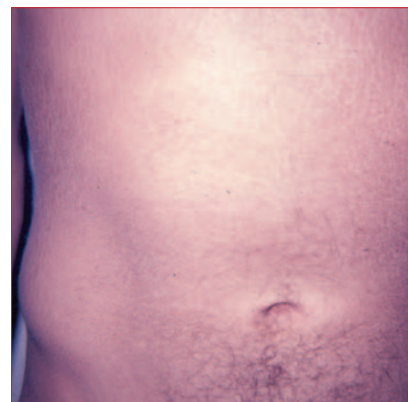


Fig. 6. Ichthyosis vulgaris.

IMPETIGO

Impetigo is a superficial infection of skin caused by either *S. aureus* or *S. pyogenes*. It may follow minor trauma or complicate surgical wounds, burns, eczema, scratches, scabies and insect bites. Not uncommonly the infection starts *de novo*. Flaccid vesicles and pustules rupture to leave erosions and honey-coloured crusts on an erythematous base (Fig. 7). Any site can be affected, but the face is especially prone. A bullous form is caused by certain strains of *S. aureus*, where large bullae rupture to leave annular desquamating patches. Impetigo heals without scarring, but temporary pigmentation change can occur. Streptococcal cases can be complicated by glomerulonephritis. Mild cases are treated with antibiotic ointments like mupirocin (Bactroban) or fusidic acid (Fucidin), after cleansing with soap and water. More extensive cases are treated with appropriate oral antibiotics like cloxacillin 250 mg qid, flucloxacillin 250 mg qid, co-amoxycilav, cephalixin or cefaclor.

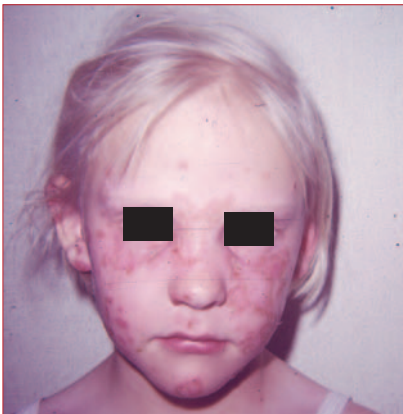

Fig. 7. Impetigo.

Macrolides like erythromycin, azithromycin, clarithromycin and roxithromycin are usually satisfactory but there is increasing resistance of *S. aureus*. MC+S (before therapy) will check whether the antibiotic was appropriate, and also aids the recognition of resistance patterns in the community.

KERATOSIS PILARIS

Keratosis pilaris is so common that there is some disagreement as to

whether it is a disorder, or a normal variant. Hair follicles on the upper arms, thighs and buttocks are plugged with a spicule of keratin, causing 'gooseflesh'. Some follicles are slightly inflamed, and tiny pustules accompany the condition, which is asymptomatic, and of cosmetic concern only. A variant affects the cheeks (Fig. 8). It may be associated with atopic dermatitis. Treatment is not very successful, but moisturisers with urea or lactic acid can be tried, and retinoid creams are helpful though irritating.

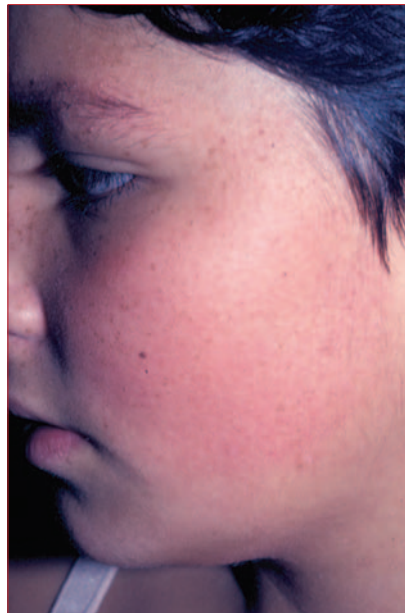

Fig. 8. Keratosis pilaris — facial.

LICHEN SCLEROSUS

This itchy, chronic, scarring disorder can occur at any age, but sometimes affects school children. Children present with itchy white papules on the genitalia, the glans and prepuce or the vulva. Initially there is some reddish or purplish inflammation around the white lesions, which become wrinkled, scaly and shiny due to epidermal atrophy (Fig. 9). Extragenital sites can be involved, and tend to be non-itchy. It is an important cause of phimosis in boys. Treatment is with potent topical steroid creams like clobetasol propionate (Dermovate), which helps the itching, and may reverse the physical signs, although it can be persistent. Circumcision can be curative when the prepuce alone is involved. An important differential diagnosis is vitiligo,

which also quite often affects the genitalia.

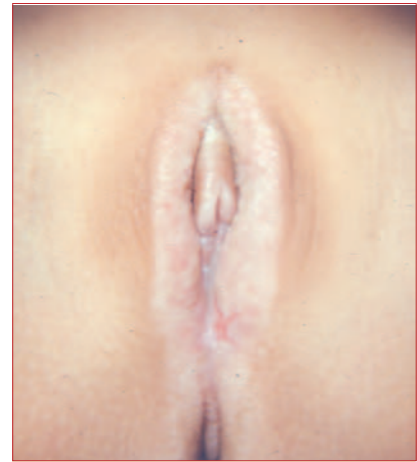

Fig. 9. Lichen sclerosus.

LICHEN STRIATUS

Lichen striatus is an idiopathic self-limited, linear dermatosis seen primarily in children. It begins suddenly with the eruption of small, flat-topped papules on a proximal extremity. Over a few weeks these coalesce into plaques in a linear band that progresses towards the distal end of the limb. This band is 1 - 3 cm wide, and from a few centimetres long to the entire length of the limb (Fig. 10). In time the lesion resolves spontaneously, but postinflammatory hypopigmentation is common for several months in dark-skinned children.

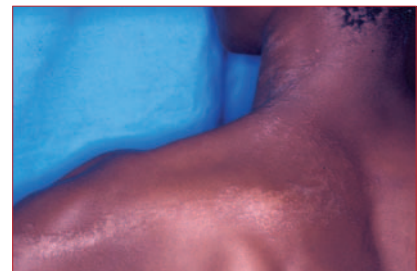

Fig. 10. Lichen striatus.

MILIA

Milia are miniature epidermal cysts which present as tiny, white, shiny papules on the face or eyelids (Fig. 11). They resemble closed comedones and can coexist with acne. They often disappear spontaneously, but can also be expressed after lancing with a needle. Milia also occur in the setting of recur-

rent blistering, or after surgical procedures like excisions.

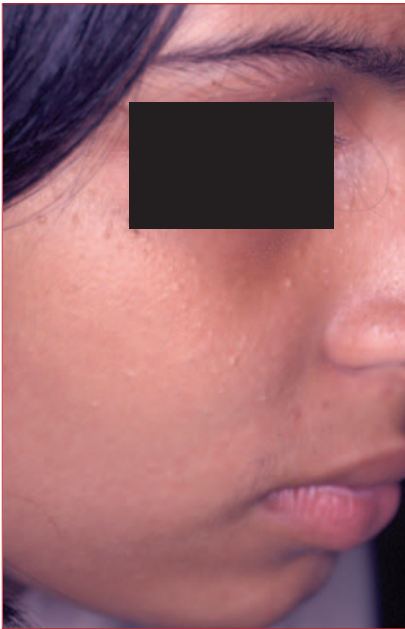

Fig. 11. Milia.

PITYRIASIS ALBA

Pityriasis alba is very common, and often confused with ringworm, occurring as asymptomatic round, dry, scaly, whitish patches on the face and upper arms (Fig. 12). It can coexist with atopic dermatitis, and is thought to be caused by dryness. There is no vitamin deficiency or malnutrition. Treatment with moisturisers like SBR Repair cream, Cream E45 or Epimax cream is often sufficient, but several months can elapse before the colour returns to normal, especially in dark-skinned individuals. A mild topical steroid cream like hydrocortisone is often added.

PLANT DERMATITIS

This is allergic contact dermatitis caused by plants; everything from trees, grasses, shrubs and weeds to flowers, vegetables, fruits and herbs. A common cause in South Africa is *Smodingium argutum* (African poison ivy). Others are primula, English ivy and fig trees. Sensitisation occurs over 1 - 2 weeks after first exposure and re-exposure elicits a severe, itchy, acute dermatitis comprising oedematous papules and vesicles (Fig. 13). Plant

dermatitis is very uncomfortable, and a short course of oral corticosteroids is usually required.

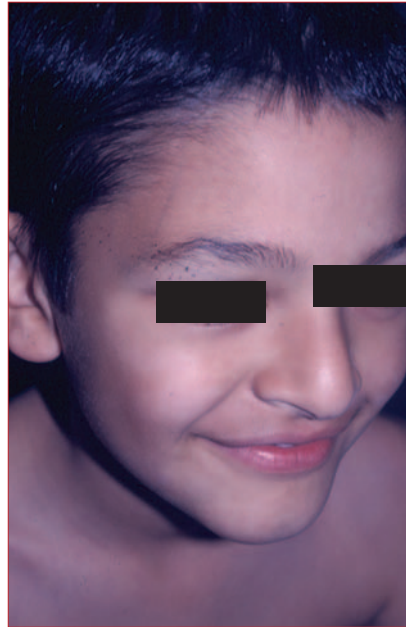

Fig. 12. Pityriasis alba.

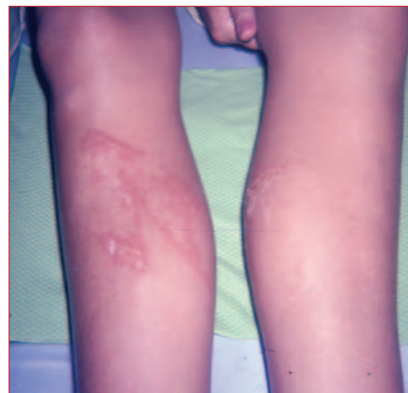

Fig. 13. Plant dermatitis.

SPIDER NAEVI

This form of telangiectasia is common on the face, hands and arms of young children and has no serious implications. The 'body' of the spider is the central red papule that represents a dilated dermal arteriole. Radiating vessels represent the 'legs'. The lesion can be blanched with firm pressure, but refills quickly. Sun exposure is thought to be important in their evolution. No treatment is required, but the lesions can be cauterised under local anaesthesia, or treated with Diolite laser. Multiple spider naevi in adults can be associated with pregnancy, cirrhosis and other liver disorders.

TINEA CAPITIS

Tinea capitis, or scalp ringworm, is common and contagious. In South Africa *Trichophyton violaceum* and *Microsporum canis* are the predominant organisms, the former from other infected children, and the latter from infected puppies and kittens. Round areas of scaling and hair loss are scattered over the scalp (Fig. 14). Pustules and nodules occur, particularly with *M. canis*, and do not signify secondary bacterial infection. Diagnosis is confirmed by mycological examination of hair and skin scrapings. The treatment of choice remains griseofulvin (Microcidal) 15 - 20 mg/kg/day in 2 divided doses for 3 months. Tablets should be crushed between 2 spoons and mixed with milk. In very mild cases imidazole shampoos like ketoconazole (Nizshampoo) are probably effective, and these can also be used prophylactically. More recently terbinafine (Lamisil) tablets have been successfully used in *T. violaceum* cases (125 mg daily for 1 month). Tinea capitis becomes much less prevalent in older children and teenagers, perhaps because the oily scalp acts as a barrier.

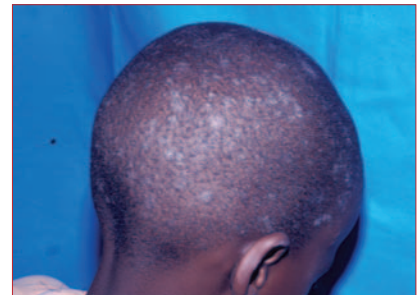

Fig. 14. Tinea capitis.

TINEA CORPORIS

Tinea corporis is ringworm of the body. Numerous dermatophyte fungus can cause this infection, but *Trichophyton rubrum* predominates. Annular, itchy, erythematous, scaly patches with central clearing are typical (Fig. 15). Tinea of the face sometimes loses the annular shape, and can easily be confused with eczema. Ideally the diagnosis should be supported by direct microscopy of skin scrapings. Nummular eczema and pityriasis alba are often erroneously

diagnosed as tinea. Tinea corporis responds well to antifungal creams like terbinafine (Lamisil), or one of the imidazoles like ketoconazole (Nizcreme), econazole (Pevaryl) or clotrimazole (Canesten). These should be applied twice daily until resolution, and then for a further 2 weeks. Tinea corporis in adults is unusual, and could signify underlying HIV infection. In these cases the tinea is unusually severe.

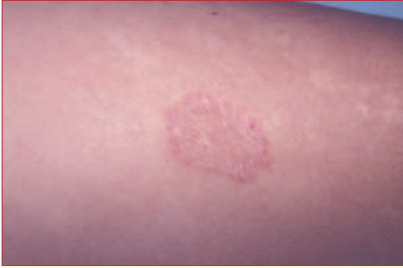

Fig. 15. Tinea corporis.

TRICHOTILLOMANIA

Trichotillomania is a condition where patients pull out their own hair, resulting in partially or completely bald patches on the scalp. Broken hairs of varying lengths are characteristically seen in the areas of alopecia (Fig. 16), a useful way to differentiate the condition from alopecia areata. When children develop trichotillomania it is usually a response to a stressful situation at school or home. An educational psychologist is recommended to address these real concerns. Trichotillomania in adults is more ominous, and implies a psychotic or obsessive-compulsive disorder.

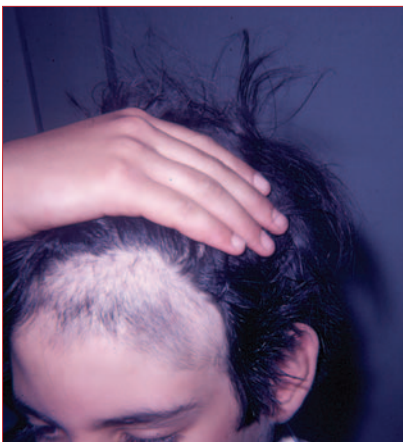

Fig. 16. Trichotillomania.

VITILIGO

Vitiligo is an acquired, localised loss of melanocytes, resulting in depigmentation of the skin. It quite often appears first in early childhood, and is very distressing. Most cases are sporadic. Well-circumscribed white macules and patches of otherwise normal skin occur symmetrically anywhere on the body, with a predilection for the face, eyelids, neck and genitalia (Fig. 17). The course is unpredictable; it may remain static, spread or resolve spontaneously. Certain sites remain chronic, whereas others have a better prognosis for repigmenting. Treatment is generally unsatisfactory. Potent topical steroid creams are the mainstay of therapy, and are worth trying for a few months. If there is repigmentation, milder steroid creams can be substituted as maintenance therapy. Calcipotriol (Dovonex) cream, primarily intended for psoriasis, has also shown some benefit. Ultraviolet phototherapy can be very effective, particularly in extensive cases.

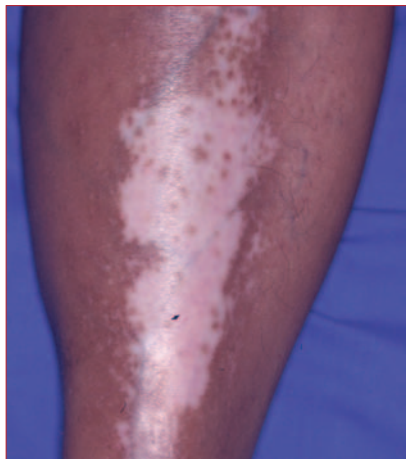


Fig. 17. Vitiligo.

WARTS

Warts are caused by human papillomavirus (HPV). Certain types of HPV are associated with certain clinical types of wart. Common warts represent approximately 70% of cutaneous warts, and occur in up to 20% of school-aged children. They present as flesh-coloured papules with a rough surface studded with tiny haemorrhag-

ic puncta (Fig. 18), commonly on the fingers, elbows and knees, but can occur anywhere. They are resistant to therapy, but most will regress spontaneously. Liquid nitrogen cryotherapy is a popular though painful treatment, and needs to be repeated every few weeks to achieve a cure. A relatively long freeze time is required, and blistering should follow. Other treatments include electrodesiccation or the regular application of caustics like salicylic/lactic acid paint (Duofilm),

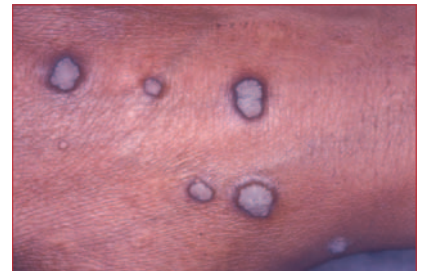

Fig. 18. Common warts.

trichloroacetic acid or lemon peel soaked in vinegar. Flat warts present as myriad tiny flesh-coloured or pink flat topped papules, typically on the dorsum of the hands, on the forearms or face. Most resolve spontaneously, but treatment with liquid nitrogen is successful. An alternative is the regular application of retinoid creams and gels like tretinoin (Retin-A). Plantar warts are painful, hard nodules on the soles. They must be differentiated from corns. Treatment is very difficult, and includes liquid nitrogen, electrodesiccation, monochloroacetic acid, or repeated application of salicylic/lactic acid paint (Duofilm).