

Technology in cardiology

Technology involves all aspects of cardiology which would hardly be the therapeutic specialty it is without it.

Technology is used in diagnosis and investigation of cardiac disease, in helping to interpret these results and in its treatment.

DIAGNOSTIC/INVESTIGATIVE TECHNOLOGY

Imaging

The accurate and detailed imaging of cardiac structure (chambers and their walls, valves, great vessels and coronary arteries) is a prerequisite for correct diagnosis and determining prognosis and also a *sine qua non* for applying the 'high-tech' treatment options increasingly available.


Echocardiography

The echocardiogram, with its moving and colour images, often forms the first noticeable link with advanced medical technology for the patient who is consulting a cardiologist. The dramatic improvements in resolution of cardiac images, and assessment of blood flow and wall movement using colour flow Doppler, tissue Doppler and 'harmonics' of the basic ultrasound frequencies, together with computational power previously only available to military installations, give information that would until recently have required invasive methods with increased risk, discomfort, delay and expense to the patient (Fig. 1). In most children with atrial septal defects (ASD) invasive diagnostic cardiac catheterisation is no longer needed and open heart surgery or other ASD closure techniques can be performed on the basis of the echocardiogram alone. With the echocardiogram, enhanced by contrast agents, it is possible to assess functional improvements in 'hibernating' segments of the left ventricle with wall motion abnormalities

during a dobutamine stress echocardiogram test to plan invasive procedures such as percutaneous transluminal coronary angiography (PTCA) or coronary artery bypass grafting (CABG). The ease of serial monitoring of ventricular size and function by echocardiography allows optimal timing of valve replacement in patients with, for example, aortic and mitral valve regurgitation. The transoesophageal echocardiogram (TEE or TOE) remains the most readily available and sensitive modality in the diagnosis of thoracic aortic dissections. TEE and the latest high-resolution conventional transthoracic echocardiograms also allow the visualisation of the origins of the coronary arteries. The remainder of the coronary tree still requires other imaging modalities. Future developments may change this. Also, 3D reconstruction of cardiac chambers, particularly useful in congenital heart disease and until now mainly a research tool, will find more clinical applications. The great advantage of the echocardiogram is ease of use, safety and availability in the doctor's rooms. Miniaturisation has resulted in portable echo machines being reduced to the size of laptops.

Contrast radiology

Even though cardiac catheterisation using X-rays and contrast has been employed for half a century, it still remains the 'gold standard' with regard to investigation of the heart. The digital video system has replaced cinefilm radiology. It is cheaper, easier to store and allows instant replay of images without the need for costly time-delaying chemical film processing that would have hindered the development of percutaneous coronary intervention (PCI). Improvement in resolution has not



ANDRZEJ OKREGICKI (AO)

MB ChB, MMed, Dip
PEC (SA), FCP (SA)

Senior Specialist

Cardiac Clinic and
Arrhythmia Service
Grootte Schuur
Hospital
University of Cape
Town

Dr AO graduated from UCT. He trained in internal medicine and cardiology at Grootte Schuur Hospital (GSH), with further experience in Newcastle, UK, and a fellowship in cardiac electrophysiology in Rochester, NY, USA.

He is currently a senior specialist in the Cardiac Clinic, GSH/UCT, and co-director of the electrophysiology laboratory. His interests are arrhythmias, devices and interventional cardiology.

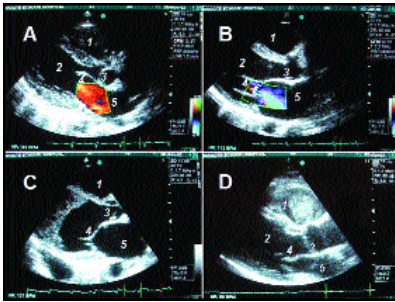


Fig. 1. Echocardiography. These snapshots of videos demonstrate the detail visible with transthoracic echocardiography. A: normal diastolic flow as demonstrated with colour Doppler through the open mitral valve. The aortic valve is closed. B: mitral regurgitation demonstrated by Doppler. The mitral valve chordae are visible. The aortic valve is open. C: enormous thrombus filling 2/3 of LV in patient with cardiomyopathy. D: metastatic tumour noted in RV in patient who presented with haemoptysis. (1 = right ventricle (RV); 2 = left ventricle (LV); 3 = aortic valve; 4; mitral valve; 5 = left atrium.)

only allowed the visualisation of blood vessels smaller than 1 mm in diameter, but also the accurate placement of devices such as stents. Digital systems with pulsed imaging have significantly reduced the radiation dose to the patient and the cardiologist. This is important because with advanced cardiology the duration of the radiology procedures has not shortened but actually increased, no longer being limited to a purely diagnostic procedure but often time-consuming, precision-requiring therapeutic interventions. Digital manipulation of images allows quantification of coronary artery stenoses, accurate measurement of lesions and road-mapping techniques that facilitate placement of PTCA wires, balloons and stents.

Magnetic resonance imaging (MRI) and angiography (MRA)

MRI and MRA are exciting technologies with increasing clinical applications. Unfortunately, their

applicability will remain limited by the availability and non-portability of the equipment and especially the prohibitive cost. Despite this, MRI is the test of choice for diagnosing aortic dissection. It is playing an increased role in congenital heart disease and cardiomyopathies. The ease of differentiation between fat and muscle makes MRI the definitive test for arrhythmogenic right ventricular dysplasia where myocytes are replaced by fat. With electrocardiographic (ECG) and respiratory gating to eliminate movement in MRA, visualisation and 3D reconstruction of coronary arteries are possible. This is particularly useful in determining the exact course of coronary arteries with anomalous origins, which may be compressed if they pass between the aorta and pulmonary trunk (Fig. 2). In the future, MR coronary angiography may replace radiological angiography for diagnosis, but is unlikely to be useful during PCI. 3D MRI reconstruction of the left atrium and pulmonary veins entering it is increasingly frequently being used to plan arrhythmia ablation for ‘focal’ atrial fibrillation.

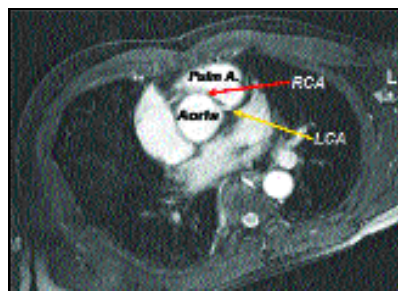


Fig. 2. Magnetic resonance angiography (MRA). This MRA was done in a patient who presented with chest pain and syncope. He was shown to have an anomalous origin of the right coronary artery (RCA) arising adjacent to the left coronary artery (LCA) and coursing between the aorta and pulmonary artery where it is at risk of compression. There was no coronary artery disease. The patient underwent bypass graft surgery.

Arrhythmia mapping

Ablation for the treatment and cure of arrhythmia usually involves application of a radiofrequency (RF) energy ‘burn’ 3 - 8 mm in diameter. The accurate placement of this burn requires localisation of an accessory or abnormal pathway or focus which is not visible with conventional imaging techniques. Localisation or mapping of the arrhythmia is most frequently performed using a roving deflectable electrical catheter inside the heart during electrophysiological studies and can be likened to searching with one’s hands all over the walls of a darkened room for the light switch, assuming that one can imagine the shape of the room from experience and that it is likely to be normal. Understandably, this conventional mapping is made more difficult by congenital heart anomalies and previous cardiac surgery.

Localisation or mapping of the arrhythmia is most frequently performed using a roving deflectable electrical catheter inside the heart during electrophysiological studies.

Electro-anatomical mapping as with the CARTO EP System (Biosense Webster, Diamond Bar, Calif., USA) allows 3D reconstruction of the cardiac chambers and analysis of arrhythmia generation or perpetuation. Using electro-magnets under the patient, a magnetic sensor in the tip of the roving catheter in the patient gives the exact position of the catheter in 3D

MAIN TOPIC

space. Using this positioning information and comparing the timing of the activation (depolarisation) of the myocardium which the catheter is touching, an activation map with colours representing the timing of the electrical signals in that chamber can be constructed. The RF ablation, likened to a spot welding, can then be targeted at the earliest site. Methods have been developed to obtain electrical signals from multiple sites simultaneously, as with the Constellation basket catheter (Boston Scientific, Sunnyvale, Calif., USA) which consists of 8 splines each with 8 electrodes giving 64 simultaneous signals. As with conventional electrophysiology, it is dependent on multiple channel (up to 128) amplifiers and displays of waveforms of multiple intracardiac signals together with the surface 12-lead ECG at various sweep speeds both in real-time and review modes. All current systems involve digitisation of the cardiac signals, usually as close to the patient as possible, to eliminate electrical noise and interference. Optical fibre cables between the amplifier and the central computer, often in a control room outside the catheterisation laboratory, ensure speed of transmission and fidelity of signal without the use of thick screened electrical cable.

The arrhythmia mapping described above may take 10 - 30 minutes to construct, during which the patient may need to be continuously in the arrhythmia. This technique cannot be used with certain arrhythmias such as ventricular tachycardias, which are not tolerated haemodynamically. The non-contact mapping EnSite system (Endocardial Solutions, Inc. St Paul, Minn., USA), using a special multiple-electrode balloon placed in the centre of the cardiac chamber, pro-

vides over 3 000 integrated virtual endocardial signal points with just one arrhythmic or ectopic beat (Fig. 3). This is like being in a dark room looking for the switch and suddenly the whole room is lit up by a flash of lightning, allowing instantaneous switch localisation. Therefore, a sustained tachycardia and a roving catheter along the walls are no longer necessary for accurate mapping to search for the source of the arrhythmia. These systems, which have been installed in fewer than 400 high patient-turnover, well-off electrophysiology laboratories around the world, are prohibitively expensive and will remain unavailable in South Africa with its single academic electrophysiology unit and limited availability of even the most basic electrophysiological service.

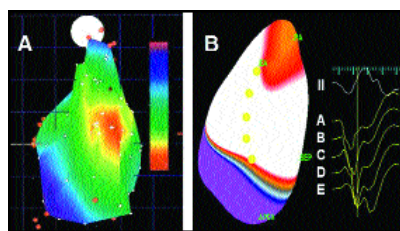


Fig. 3. Cardiac arrhythmia activation mapping. A: electro-anatomical mapping using the CARTO system with colour coding of the sequence of activation of the right atrium in a patient with a focal atrial tachycardia. The earliest region, in red, is along the posterior wall of the atrium and is the target for ablation. B: the activation map of the right ventricle (RV) as constructed by the non-contact EnSite system in a patient with RV outflow tract ventricular ectopics.

ECG

It is remarkable that the ECG, invented more than 100 years ago, has changed little. The 12-lead ECGs from the early part of the previous century are often technically as good and easily readable as those of today. What has changed is our understanding and our being

able to see or appreciate features on the ECG which were always there but to which we were 'blinded'. In an individual patient, comparison with previous ECG recordings is often valuable. Advanced hospital digital archiving systems of tens of thousands of downloaded ECGs with quick search facilities give prompt access to these old ECGs even in the emergency unit and can influence the acute management of patients with cardiac emergencies. Devices with digital memories are used for 24-hour ECG (Holter) recording and other event monitors.

THERAPEUTIC TECHNOLOGY

Less than 50 years ago, cardiology was a fascinating subject with the main interest the diagnosis of the pathology. There was little prospect of therapy or cure. This has changed dramatically to such an extent that there are few fields of medicine that can achieve so much treatment and are so dependent on technology.

Coronary artery disease (CAD)

With the high prevalence of CAD in urbanised societies, most people will be exposed to the technology that deals with this disease directly or through family members/acquaintances. In myocardial infarction, the mainstay of treatment is prompt revascularisation with thrombolysis or PCI (Fig. 4). The latter requires diagnostic technology (most frequently digital contrast radiology imaging), monitoring technology and sophisticated delicate technology used in the therapy — guiding coronary artery catheters, fine wires with exceptional torque properties and polymer coatings to pass through the coronary artery occlusion or stenosis, and PTCA balloons. The latter

are remarkable achievements of science, as in the deflated form they may have a profile of less than 1 mm and can expand to an accurately predetermined diameter of several millimetres with forces of up to 16 - 20 bars of pressure using non-compliant plastics. Despite the complexity of the manufacture of these devices, their use involves little more than a standard cardiac catheterisation laboratory, skill and a syringe-like insufflator. Other techniques such as rotational atherectomy to bore out chronic, often calcified, stenoses are expensive and require specialised equipment. Inflation of PTCA balloons may in certain situations, especially atherosclerotic stenoses in venous grafts, be associated with distal trashing of the vessel and flow disturbances in the microcirculation. Special filter nets can be deployed through the stenosis before balloon inflation to collect the debris that may be released at the time of balloon inflation and to protect the distal vessel.

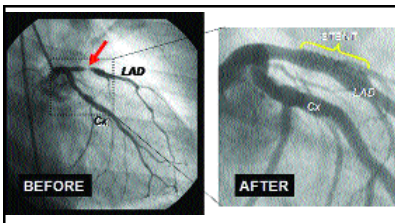


Fig. 4. Coronary angiography and intervention. A 35-year-old man presented with new-onset angina at rest. The left coronary angiogram showed a severe stenosis of the left anterior descending (LAD) artery and minor irregularity of the circumflex (Cx) artery. The LAD lesion was treated using primary stenting, with good result.

The gain in lumen diameter by PTCA balloon may be limited by vessel wall recoil or re-stenosis. Stents acting as a scaffold inside the dilated vessel significantly reduce this, but do not eliminate

the problem. Various methods have been tried to reduce in-stent stenosis, and almost all are aimed at reducing the inflammatory reaction and subsequent fibrosis — radioactive stents, irradiation of the lesion at the time of stent deployment by passing radioactive wires through them and, most recently and effectively, using cytotoxic drug-eluting stents. The stents are a feat of modern metallurgical micro-engineering, made from a tube of stainless steel, tantalum or nickel-titanium alloy with expandable hinges and struts carved by laser (Fig. 5). These stents may be covered with various coatings such as polymers, carbon and drugs, e.g. heparin, sirolimus or paclitaxel to reduce re-stenosis.

It appears that correct deployment of the stent struts against the vessel wall is crucial for long-term patency. To achieve this, accurate sizing and high-pressure inflation are needed. In some situations with irregular eccentric plaques, imaging the lumen alone as with the standard coronary angiography is inadequate. Intravascular ultrasound (IVUS) with passage of an ultrasound probe of 1 mm diameter into the coronary artery and lesion allows the demarcation of the true vessel diameter and can assess the adequacy of deployment of the stent by visualisation of the struts and vessel wall (Fig. 6).



Fig. 5. Coronary artery stent. This photo shows a stent that has been expanded to a diameter of 3 mm by the balloon on which it is mounted. This was a demonstration — the expanded stent can no longer be used and will be discarded.

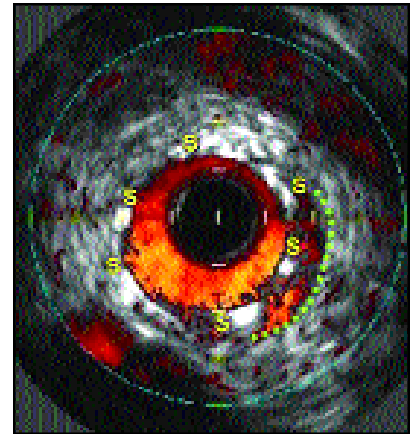


Fig. 6. Intravascular ultrasound (IVUS). IVUS with colour enhancement was done after stenting this coronary artery. This snapshot of the cross-section of the coronary artery shows the US catheter (1 mm diameter) in the centre (black), the echodense (white) struts (S) of the stent and the lumen of the vessel. Inadequate expansion of the stent is shown — a gap is noted between the struts and the edge of the lumen (green dotted line). Further high-pressure balloon inflation to optimise stent deployment is indicated.

Electrophysiology

There are few chronic medical/cardiac conditions other than arrhythmias that can be cured (permanently) by a percutaneous procedure. Ablation of accessory pathways in Wolff-Parkinson-White syndrome and other congenitally present pathways that are responsible for arrhythmias originally required open heart surgery. Now, 'spot welding' with a well-directed burn applied by a catheter passed percutaneously can achieve this cure, and do so cheaply. RF energy, causing resistive heating, forms the mainstay of treatment. The RF energy generator varies the delivered power to maintain a constant temperature at the catheter tip (approximately 65°). Other ablation techniques using cryoablation or microwave energy are expensive and have been used mainly experimentally.

Devices

Arrhythmia devices

Permanent pacemakers and implantable cardioverter defibrillators (ICD) are some of the most technologically sophisticated devices implanted into humans. These devices, which are getting smaller, do not just deliver pulses or shocks; using microprocessors (computer chip technology) they constantly monitor the cardiac rhythm, make adjustments according to complex, programmable algorithms and store selected arrhythmias in memories that can be accessed later. Pacemaker programmers are external computers that communicate percutaneously by radio with the devices and allow interrogation of battery, pacing lead status, counters and memories and in some cases download software upgrades into the pacemaker. Unfortunately there is no uniformity among the pacemaker manufacturers and each make requires its own external programmer. Throughout the life of the device, programme adjustments may be indicated. This is especially the case in ICDs where the appropriateness of shock therapy needs to be confirmed. Until recently, only pacemaker battery status could be checked remotely transtelephonically without the patient physically having to attend the pacemaker clinic. New developments allow all data in the device to be accessed and even changes in pacing programmes to be made at long-distance, usually via the Internet with the patient at home. It is possible that the arrhythmia devices could automatically contact cell phone and Internet networks, relaying data and warnings directly to the cardiac clinic.

Since the majority of sudden cardiac arrests occur in the general population rather than in cardiac patients and resuscitation is dependent on the speed of defibrillation

(with success decreasing to less than 10% after a delay of 9 minutes), increasingly, automated external defibrillators (AEDs) are being placed at airports, stations, sport stadiums and gyms. They have been shown to be effective even when used by non-medically trained persons because the AED 'talks' to the resuscitator, instructing what to do, and automatically interprets the cardiac rhythm and advises or gives the shock. Therefore, in a situation where time determines success, frequently the patient is resuscitated before emergency medical services arrive on the scene. AEDs are relatively cheap, small, compact, easily portable devices that most doctors should probably invest in and keep in their rooms or car boot.

There are few chronic medical/cardiac conditions other than arrhythmias that can be cured (permanently) by a percutaneous procedure.

Closure devices

Non-surgical closure options are now available for conditions such as atrial and ventricular septal defects. Advances in metal alloys have resulted in the manufacture of low-profile and effective occlusion devices that spring into shape after being deployed via a catheter.

Artificial hearts/ventricular assist devices (VAD)/pumps

Since the first heart transplant operation and with the recognition of limited donor organ supply and problems with rejection, there has been pressure to develop an artifi-

cial heart. The many attempts have been hampered by size, power supply, risk of infection and thromboembolism, poor durability and expense, that place this technology beyond the use of the general patient. VAD are used temporarily perioperatively while waiting for cardiac function to improve. The continuous flow left ventricular (LV) pump has been an interesting development. This small axial-flow impeller electric pump weighing 90 g and providing continuous non-pulsatile flow at 12 000 rpm fits inside the left ventricle and is attached to the descending aorta. The power supply is a portable external battery pack with a cable and plug on the side of the skull behind the ear. Some patients with end-stage cardiomyopathy and fitted with the LV pump have been able to return to work. This pump, which works synergistically with the left ventricle, may promote its recovery, similarly to the heterotopic (piggy-back) heart transplants that were once performed.

INTERPRETATIONAL TECHNOLOGY

ECG and arrhythmia devices

The Achilles heel of the dramatic advances in data technology is the reliance on the automated interpretation of the findings. An example is the 12-lead ECG where the computer analysis with regard to simple measurements such as heart rate, PR and QT interval, QRS duration and axis is usually reliable; yet in the computer-generated interpretation of the arrhythmia or morphological abnormalities one may be given so many possible options, some totally incorrect, that it is not only useless but potentially dangerous to the unwary physician (Fig. 7). All computer interpretations upon which clinical decisions need to be made, e.g. myocardial infarction and arrhythmias such as

MAIN TOPIC

ventricular tachycardia (VT), need to be checked by the physician, who will also consider patient history and examination. Algorithms used by ICDs and AEDs to diagnose VT or ventricular fibrillation have improved, but are always set to give therapy if in doubt, i.e. over-interpret. Therefore all automatic device therapies need to be reviewed for appropriateness.

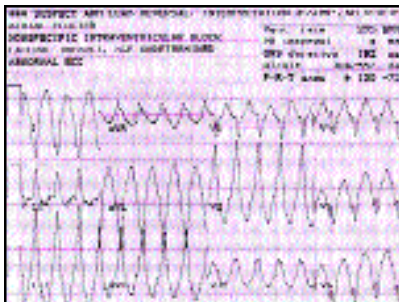


Fig. 7. ECG computer interpretation. This 12-lead ECG was interpreted by the computer incorrectly as showing atrial flutter, probably because of a poorly programmed algorithm. It shows a regular, monomorphic, wide QRS complex, ventricular tachycardia at 205 beats per minute. Management of this patient based on the incorrect ECG computer interpretation could have been life-threatening.

MANAGEMENT TECHNOLOGY

Data

Information technology has changed the storage of patient data. No longer are cardiac angiograms recorded on bulky cine films and viewed with special projectors. Compact disks are a cheap and compact storage system and easily viewed on most computers.

Networking

Networks in the hospital allow immediate viewing of investigations such as angiograms, MRI, and echocardiograms by the patient's physician. Digitally archived data are also available to emergency room doctors. The easy and convenient accessibility of these data needs to be balanced against patient confidentiality. Many insti-

tutions monitor access even by those authorised to view these data to prevent abuse.

Telemedicine

The widespread availability of the Internet and image telecommunication allows the sharing of knowledge and the tapping of expertise at remote specialist centres.

Experts thousands of miles away can comment and give advice in live cases, e.g. of cardiac intervention, and can immediately observe the results, thereby avoiding the transfer of ill, unstable patients.

All automatic device therapies need to be reviewed for appropriateness.

IMPLICATIONS AND ETHICS

The inextricable link between cardiology and technology affects the following:

Cardiologists

On the one hand a cardiologist without technology is almost useless, yet on the other hand there is the risk of over-reliance on fancy investigations used as a substitute for the good clinical skills of history taking and examination, or even worse as a mask for clinical incompetence and slovenliness or over-servicing. Doctors may feel apprehensive about clinical decisions without the crutch of technology, resulting in overuse of tests and relying on automated interpretations which can be both expensive and dangerous.

Technologists/personnel

With the ever-expanding machines and technology, there is a need for those who can operate them competently. Such clinical technologists with all-round skills are in great demand. This is an exciting, chal-

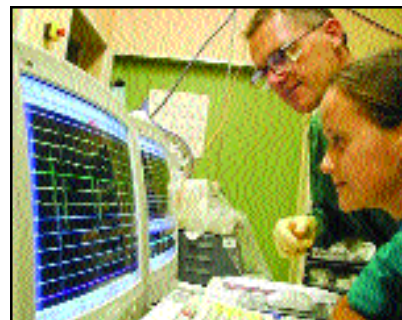

Fig. 8. Cardiac clinical technology. The cardiologist and clinical technologist working as a team in the cardiac 'cath lab', analysing the waveforms on the computer monitor during an electrophysiological study in a patient with palpitations.

lenging profession symbiotic with that of the cardiologist (Fig. 8). There is often pressure to obtain the latest equipment in the same way that most have experienced with new computer software. Both cardiologist and technologist need training to use the full potential offered by the new technology and to know its limitations. Having it does not equal knowing how to use it; something that is often forgotten by well-meaning overseas charity organisations that may donate equipment inappropriate to the hospital and its capabilities. Also, without adequate servicing, after-sales customer support and knowledgeable servicing personnel, technology cannot be depended on, leading to frustration and likely abandonment in a dusty corner!

Patients

Technology in cardiology has made investigation and treatment expensive for patients. Situations arise where the best treatment is not possible because it cannot be afforded. Conversely, patients frequently are aware of the latest technology through the media and Internet, and are dissatisfied with a mere history and examination, regarding such a consultation incomplete or even incompetent. They often demand further unnecessary investigations such as an

echocardiogram. It is difficult for doctors not to surrender to such pressures.

There is no doubt that cardiology and its patients have benefited from the advancement in technology; it needs to be carefully evaluated and embraced.

FURTHER READING

- Braunwald E, Zipes DP, Libby P. *Cardiovascular Medicine*. 6th ed. Philadelphia, Penns., USA: WB Saunders, 2001.
- Serrys PW, Kutryk MJB. *Handbook of Coronary Stents*. 2nd ed. London: Martin Dunitz, 1998.
- Strickberger SA, Knight BP, Michaud GF *et al*. Mapping and ablation of ventricular tachycardia guided by virtual electrograms using a non-contact, computerized mapping system. *J Am Coll Cardiol*. 2000; **35**: 414.
- Topol EJ, Califf RM, Isner JM. *Textbook of Cardiovascular Medicine*. 2nd ed. Philadelphia, Penns., USA: Lippincott, Williams & Wilkins, 2002.
- Westaby S, Baning AP, Saito S, *et al*. Circulatory support for long-term treatment of heart failure. *Circulation* 2002; **105**: 2588.

IN A NUTSHELL

Clinical technology and cardiology have a synergistic relationship with regard to investigation and intervention.

Echocardiography complements clinical cardiology, but does not replace competent history taking and clinical examination.

Cardiac catheterisation and angiography still remain the 'gold standard' for most complex cardiac conditions.

Digital radiology systems allow image manipulation, measurement, instant replay and easy storage with less radiation.

Magnetic resonance imaging is the investigation of choice for aortic dissection and certain cardiomyopathies.

Conventional intracardiac contact arrhythmia mapping is adequate for the majority of arrhythmias that can be ablated. 3D mapping systems are useful in abnormal hearts or after surgery.

Most percutaneous cardiac intervention can be done using PTCA balloons and stents. Complex lesions occasionally may require other expensive techniques that are generally not needed; such as atherectomy and intravascular ultrasound.

Arrhythmia devices (pacemakers and ICDs) need careful follow-up with monitoring and interrogation, as adjustments after implantation may be necessary.

Great care must be taken with computer-generated interpretation of investigations (e.g. ECG), as reliance on this could potentially be dangerous.

Cardiac technology and information management have important associated ethical issues.