



HAROLD BLOCH

MB ChB, FCP (SA), FRCP
(UK)

Gastroenterologist

*Vergelegen Medi-Clinic
Somerset West*

Harold Bloch qualified cum laude from the University of Pretoria in 1972. He specialised in medicine at the

HF Verwoerd Hospital and the Bristol Royal Infirmary. After returning to Johannesburg, he was appointed as Head of the Gastroenterology Unit until he left to commence private practice. He subsequently relocated to Somerset West where he continues in private practice, with a part-time appointment at Groote Schuur Hospital, Cape Town.

Technology in gastroenterology

Both diagnostic and therapeutic aspects of gastroenterology have benefited from technological advances.

The digestive tract has long been regarded as an ideal organ system for innovative investigation. Although digestive diseases were known to Greek medicine, modern gastroenterology was probably born in 1882 when William Beaumont evaluated Alexis St Martin, a soldier who had developed an external gastric fistula following a gunshot wound.

In 1961 Basil Hirschowitz, a South African doctor, published the first flexible endoscopic examination of the stomach and duodenal bulb.

Endoscopy has revolutionised clinical gastroenterology. In 1961 Basil Hirschowitz, a South African doctor, published the first flexible endoscopic examination of the stomach and duodenal bulb. With the introduction of fiberoptic endoscopy commercially in the 1970s it became possible to evaluate the digestive organs easily, greatly advancing the pathophysiological approach. Fiberoptic and video endoscopy has also spawned laparoscopic surgery, not to mention arthroscopic and other forms of minimally invasive surgery.

Fiberoptics were perfected and then overtaken by newer generation video endoscopes incorporating either a black and white or colour chip at their tip, which transforms the visual image into an electronic signal. The resolution and quality

are improving, and images captured by the latest magnifying video-endoscopes prove that the image quality of the video-endoscopy (VE) is approaching the diagnostic capability of the stereomicroscope.¹ Endoscopes are now used to examine the entire gastrointestinal tract, including the biliary and pancreatic system. Targeted biopsies offer rapid and precise diagnosis.

Barium studies were always regarded as the optimal method of investigation of the GI tract until they were replaced by endoscopy. Recently we have seen a resurgence of CT- and MRI-based imaging techniques using virtual colonography, and with time this may acquire new status as a non-invasive mass screening technique for colon cancer. Endoscopic ultrasonography is accurate in staging gastrointestinal tumours, and assessing disorders of the biliary and pancreatic ducts as well as ano-rectum. Using endoscopic endosonography we are able to perform targeted biopsy and cytological assessment of the intestinal wall and perintestinal lymph nodes.

Oesophageal manometry and 24-hour pH studies have been valuable in research and therapeutic gastroenterology. The Bravo pH system uses a remote pH sensor, temporarily attached to the oesophageal mucosa, to record and transmit minute pH changes via telemetry to an external receiver. The technique is now more acceptable to patients who previously had to put up with a nasogastric wire pH recorder for a 24-hour period.

Telemetry has also made small-bowel studies possible. The Given capsule incorporating a video chip is swallowed and as it transits the bowel it transmits video

MAIN TOPIC

data allowing a precise study of the entire visualised small bowel. The data are captured by a recording system worn externally by the patient. The resulting video can be viewed at the examiner's leisure.

What has not changed, is the clinical usefulness and need for **therapeutic** endoscopy. Treatment of bleeding lesions (varices and ulcers), endoscopic polypectomy, endoscopic photodynamic therapy, endoscopic sphincterotomy for stone extraction, insertion of drainage prostheses in blocked biliary or pancreatic ducts, application of Nd, Yag and argon laser, and the delivery of balloon dilatation systems all currently rely on therapeutic endoscopy.

Gastroenterology has produced amazing technological advances in the past four or five decades and hopefully this will continue in the future.

VE has been remarkably enhanced by using a charge coupled device (CCD) as an image sensor.

HIGH-RESOLUTION VIDEO-ENDOSCOPES

VE has been remarkably enhanced by using a charge coupled device (CCD) as an image sensor. The latest CCDs have higher pixel counts than those in VE systems currently in use. The development of high-resolution magnifying video-endoscopes with high pixel counts has advanced the VE to the level of a stereomicroscope. The latest CCD (with an image format of 1/3" with 850K pixels), is incorporated in the scope tip and because of its small size scope diameter remains acceptable. They also incorporate variable focusing

and electronic magnification allowing in-focus observation ranges equivalent to normal video-endoscopes for any given object located 7 - 100 mm away from the scope tip. When they are moved closer to the area of interest (up to 3 mm away), it is possible to focus by moving part of their objective lens elements, resulting in a magnified image of approximately X 35 when displayed on a 14" TV monitor. Because the resulting instrument has almost the same diameter as current slim endoscopes they can be used for routine examination with good manoeuvrability (Figs 1-3).¹




Fig. 1. A Fujinon high-resolution endoscope.

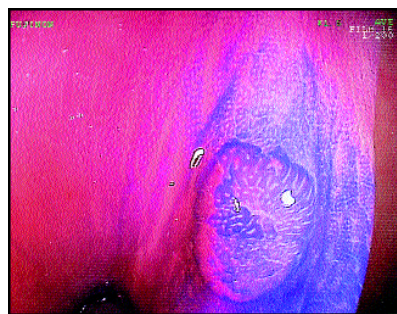


Fig. 2. X35 view of an early adenoma as seen with a high-resolution endoscope.

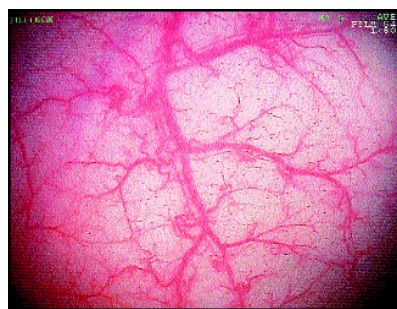


Fig. 3. Exquisite detail as seen with high-resolution endoscopy.

GASTROINTESTINAL BLEEDING

Although the techniques briefly outlined below are not new, the therapeutic impact they have had deserves a brief mention. Studies have shown that endoscopic intervention resulted in a lowering of the mortality from gastrointestinal bleeding, but it is still high at 10%.² Mortality is related to the age and co-morbid pathology in these patients. This article does not discuss the management of gastrointestinal bleeding but highlights the advances in technology to control the bleeding.

A NIH Consensus Conference on therapeutic endoscopy and bleeding ulcers concluded that 'endoscopic haemostatic therapy should only be used in patients at risk for persistent or recurrent bleeding and death, those with clinical evidence of a large initial blood loss and endoscopic evidence of active bleeding or a non-bleeding visible vessel'.³

Endoscopic haemostatic techniques

Thermal methods

Thermal methods rely on heating tissue with resulting protein denaturation, collagen contraction and tissue dehydration. The main risk is overheating (above 250°C) with unnecessary tissue damage and perforation.

• **Laser coagulation using Argon or ND: YAG.**

Both methods employ pulsed laser light around a bleeding site, inducing oedema and vessel coagulation. Meta-analysis of prospective trials reveals significant benefit in terms of reduction in urgent surgery. The cost of the units and relative lack of portability limit its use in South Africa.

• **Electrocoagulation with mono and bipolar probes (BICAP).**

With this technique the bleeding site can be compressed. However

the probe may adhere to the tissue ('welding'). BICAP has been shown to decrease bleeding and transfusion requirements, shorten hospital stay and lower the need for urgent surgery at low monetary cost.⁴ Both mono and bipolar electrocoagulation are performed using mobile units which can be used at the bedside.

• **Heater probe.** This has an irrigation channel which permits flushing and prevents tissue adherence, but retains the advantage of allowing compression of the bleeding site. It is a relatively safe method because it cannot exceed the critical 250°C. Two controlled European studies did not however show significant benefit over the other methods.⁵

Injection sclerotherapy

Injection sclerotherapy of varices and bleeding peptic ulcers has proved effective at low cost, and in most institutions this method is still the first choice of therapy.⁶

Haemostatic clipping method

The haemoclip is a metal clip delivered endoscopically which mechanically closes the bleeding vessel. This technique does not cause much tissue damage and stops bleeding immediately. However in practice, application of the clip is often difficult, time consuming and at times impossible.⁷

Banding of oesophageal varices

Banding using the same principles applied to haemorrhoids is a very successful technique to prevent bleeding from varices. This may be used in conjunction with injection sclerotherapy when visibility is poor. Numerous studies confirm the value of this technique.

Non-endoscopic angiographic therapy

This has developed rapidly. Embolisation of bleeding arteries

with absorbable gelatine sponge (Gelfoam), an autologous clot tissue adhesive or coils, is regularly used by the interventional radiologist. This may control bleeding in approximately 75 - 80% of cases although rebleeding may occur. This will not be discussed further in this short review.

ENDOSCOPIC STENTING

1980 marked the beginning of a new approach to the treatment of biliary and pancreatic disease with the introduction of endoscopic transpapillary stenting. Initially employed as a palliative measure for patients with malignant biliary obstruction, this technique has been increasingly applied to manage complications of laparoscopic cholecystectomy and other benign disorders of the biliary and pancreatic ducts. The improvement in endoscopic equipment, stents and guidewire technology has made dramatic strides in the past few years allowing conservative management of cases, which in the past would have been impossible.

Integrating endoscopy and ultrasonography in one instrument has created a useful diagnostic tool.

Although the closely fitting assembly of guidewire, catheter and stent is usually all that is required, a variety of new dilating devices have become available for the more difficult cases. The Soehendra dilating catheters and a variety of balloon-tipped catheters have greatly facilitated stenting of difficult cases, which previously would have been impossible.⁸

ENDOSONOGRAPHY (ES)

Integrating endoscopy and ultrasonography in one instrument has created a useful diagnostic tool. Endosonography is the most accurate technique for imaging the wall of the gastrointestinal tract and its immediate surroundings. Because benign and malignant disease can appear similar ultrasonically, it may be difficult to differentiate between the two. It does allow one to view the abnormality in relation to the layers of the gastrointestinal wall, and in good hands it is an accurate method to stage malignancies.

The most commonly used endosonoscopes are equipped with a mechanical rotating sector scanner operating at 5, 7.5 or 12 MHz frequency. They can be equipped with a balloon around the transducer which when filled with de-aerated water assures good acoustic coupling between transducer and organ. With certain models one is able to perform targeted biopsies with great accuracy.

Endosonography is a difficult endoscopic examination and a huge learning curve exists especially when studying the pancreatic-biliary system. The instruments are expensive.

The locoregional staging of oesophageal and gastric carcinoma is greatly facilitated by endosonography. In oesophageal carcinoma accurate T staging of 85% can be obtained, which compares favourably with 58% for CT scanning. For N staging the accuracy of endosonography was 75% v. 54% for CT scanning. In gastric cancer the results are similar. ES is also of value in staging non-Hodgkin's lymphoma of the stomach, and evaluating the nature of large gastric folds.

Because the entire pancreas can be well visualised, ES is an ideal means of diagnosing chronic pan-

MAIN TOPIC

creatitis, and staging pancreatic tumours.⁹

The assessment of ano-rectal incontinence is greatly facilitated by endo-anal ultrasound. The integrity of the muscle layers can be evaluated in detail and a surgical approach planned in advance.

COLONOGRAPHY

Over 140 peer-reviewed articles have appeared on this subject in the past 5 years. As MRI and CT technology improves, virtual colonoscopy, now commonly referred to as colonography, is fast becoming an attractive alternative for mass screening of colorectal disease. Colorectal cancer is the third most common cancer in the Western world and continues to be the second leading cause of cancer-related deaths in the USA.

Although the majority of cases of colorectal cancer can be prevented with colonoscopic removal of precursor adenomatous polyps, compliance with full structural examination by either barium enema or colonoscopy is abysmal. In the search for an adequate screening method, colonography has emerged relatively quickly. It possesses unique advantages over existing screening tests in that it is quick, non-invasive, and a full structural colon investigation. It is highly accurate, reproducible and acceptable to the majority of patients; in addition it may display extracolonic findings of medical significance. Increasingly in the USA and other countries reimbursement for screening colonoscopy is not allowed. Although it is hoped that this attitude will change colonography may become a suitable substitute at the right price (not yet!). However it must be remembered that it is only a diagnostic and not a therapeutic investigation.

Currently the most widely accept-

ed application for CT colonography is following incomplete colonoscopy. These examinations can be performed on the same day without additional preparation, as bowel cleansing for both procedures is the same. However as bowel preparation is an important factor influencing compliance, faecal tagging has been proposed as a method to replace standard bowel preparation. Instead of lavage cleansing regimes, barium or iodinated oral contrast is ingested with meals in order to label stool before colonography. Once labelled, stool can be subtracted automatically using thresholding techniques. MR colonography using tagging techniques to avoid bowel preparation is also being developed.

MR colonography takes 10 minutes and most patients can tolerate the insufflation of the gaseous or liquid enema prior to the investigation. Antispasmodics are usually administered to prevent artifacts.

Multiple large studies have documented that CT colonography can detect polyps of 10 mm or less with a sensitivity from 51 - 100%. This wide range is due to different techniques currently in use but hopefully this will improve as techniques become standardised. With faster computer platforms increasing spatial resolution and more experience the results will improve. Nonetheless most investigators report a sensitivity of greater than 85% and specificity greater than or equal to 90%. At this stage ionising radiation from CT colonography is a problem but with newer machines this will be reduced. MR colonography is not subject to this problem but is more expensive.¹⁰

The technological revolution in medicine and gastroenterology is far from over. Do we view the development of newer pharmaceuticals and other therapeutic modalities as technological advances or

do we restrict the use of this terminology to new gadgets and gimmicks? Ideally all developments are in the interest of better, safer and cheaper medicine and long may this continue.

References available on request.

IN A NUTSHELL

Endoscopy has revolutionised clinical gastroenterology.

Fibreoptic and video-endoscopy are developments which have improved endoscopic examinations even further. They allow examination of the entire gastrointestinal tract.

Telemetry has made small-bowel studies possible.

A need for therapeutic endoscopy still exists.

New techniques for treating gastrointestinal bleeding include thermal methods by laser or electrical probes, injection sclerotherapy, haemostatic clips, banding of oesophageal varices and embolisation of bleeding vessels.

Endosonography, the combination of endoscopy and ultrasonography in one instrument, has created a useful diagnostic tool. It can be used for targeted biopsies, and staging of oesophageal and gastric cancer, and non-Hodgkin's lymphoma.

Colonography is another new technology which is still too costly for general application and may provide a screening tool for colonic cancer.

Visit our
website

www.samedical.org