

**WF MOLLENTZE**  
MD, FCP (SA)

Department of  
Internal Medicine  
University of the Free  
State  
Bloemfontein

Dr Mollentze's current fields of interest are the epidemiology of diabetes mellitus and its macro- and microvascular complications, multiple endocrine neoplasia syndromes, osteoporosis and medical education.

# Screening for microvascular complications of diabetes mellitus: missed opportunities

**The microvascular complications of diabetes are common and largely preventable by good primary health care.**

A small minority of patients with diabetes mellitus are examined appropriately at primary health care level to detect the presence of microvascular complications. Yet, diabetic retinopathy is the most common cause of blindness in adults between 30 and 65 years of age in developed countries. Diabetic nephropathy is now among the most common causes of end-stage renal failure (ESRF) in developed countries; and neuropathy affects up to 50% of diabetic patients.

## DIABETIC RETINOPATHY

The prevalence of diabetic retinopathy in the Wisconsin Epidemiological Study of Diabetic Retinopathy (WESDR) according to type of diabetes and treatment is shown in Fig. 1. It is important to realise that the probability of a patient with type 1 diabetes having any form of retinopathy is 71%, with type 2 diabetes on insulin therapy it is 70% and with type 2 diabetes not on insulin therapy it is 39%.

The prevalence of diabetic retinopathy varies with the

duration of diabetes. Newly diagnosed patients with type 1 diabetes are very unlikely to have diabetic retinopathy, but 10 years later almost 70% will have evidence of retinopathy. Twenty years later this figure rises to almost 100%. However, in newly diagnosed patients with type 2 diabetes more than 25% will have evidence of retinopathy. After 10 years this figure rises to 50% in patients not taking insulin and to 65% in patients on insulin therapy. After 20 years the respective rates are 50% and 90%. The clinical features of diabetic retinopathy are listed in Table I.

### Microaneurysms

These are usually the earliest clinical abnormality detected and appear as tiny, discrete, circular, dark red spots, near to but separate from the retinal vessels.

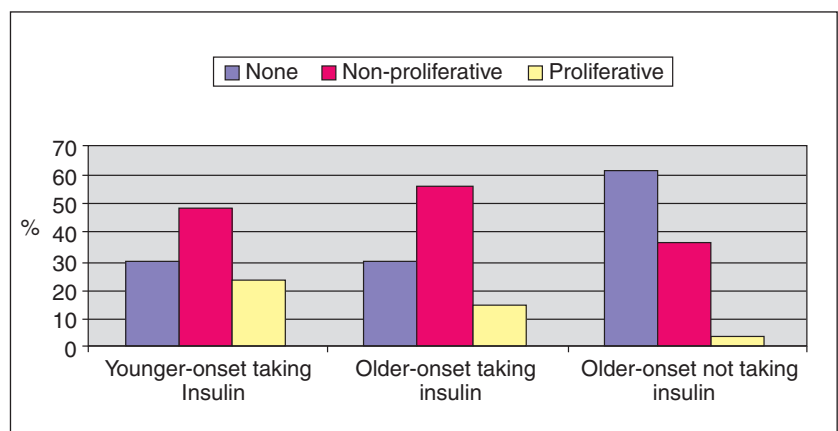


Fig. 1. The prevalence and severity of retinopathy in the WESDR (younger-onset taking insulin = mostly type 1 diabetes, older-onset = mainly type 2 diabetes).

## Table 1. Clinical features of diabetic retinopathy

- Microaneurysms
- Retinal haemorrhages
- Hard exudates
- Cotton-wool spots
- Intraretinal microvascular abnormalities (IRMA)
- Venous changes
- Neovascularisation
- Pre-retinal haemorrhage
- Vitreous haemorrhage
- Fibrosis

### Haemorrhages

Haemorrhages in the deeper layers of the retina are round and regular in shape and described as 'dot haemorrhages'. Sometimes these haemorrhages are larger, so-called 'blot haemorrhages' (Fig. 2). More superficial haemorrhages in the nerve layer of the retina are characteristically flame-shaped.

Subhyaloid haemorrhages may also be seen. These occur just beneath the inner limiting membrane of the retina.

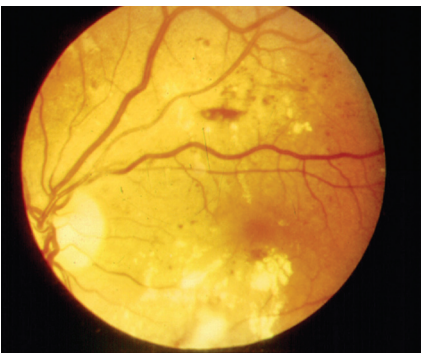


Fig. 2. Non-proliferative retinopathy: Venous tortuosity, microaneurysms, blot and dot haemorrhages, small subhyaloid haemorrhage, and hard exudates.

### Hard exudates

These are characteristic of diabetic retinopathy and consist of deposits of extravasated plasma proteins, especially lipoproteins, together with an associated macrophage response. They are most significant when they are laid down at the macula. Hard exudates appear as

off-white to yellow dots, flecks or plaques, often with a shiny appearance (Fig. 2).

### Cotton-wool spots

Cotton-wool spots occur as localised whitish elevations of the retinal nerve-fibre layer. They are associated with microvascular infarction and represent intracellular axoplasmic material. They are most often seen in rapidly advancing retinopathy or in association with uncontrolled hypertension.

### Intraretinal microvascular abnormalities (IRMAs)

IRMAs consist of vascular elements within the retina that branch with a frequency, number and angulation unlike that of normal retinal vessels. They lie entirely within the retina and therefore do not overlie retinal vessels or give rise to preretinal or vitreous haemorrhage. IRMAs represent attempts to revascularise ischaemic retina.

### Venous changes

These include venous dilatation (an early feature probably representing increased blood flow), 'beading' (sausage-like changes in calibre) and increased tortuosity (Fig. 2). Venous beading is an indicator of severe capillary non-perfusion, and its extent reflects the proportion of the fundus affected.

### Preproliferative retinopathy

Several features, collectively referred to as preproliferative diabetic retinopathy, have been identified that confer a significantly increased risk of proliferative retinopathy. These include:

- venous beading, looping or reduplication
- multiple (especially more than five) cotton-wool spots
- IRMAs
- multiple haemorrhages.

When these changes are present, follow-up by a specialist is mandatory.

**Several features, collectively referred to as preproliferative diabetic retinopathy, have been identified that confer a significantly increased risk of proliferative retinopathy.**

### Neovascularisation (proliferative retinopathy)

Ischaemic changes in the retina stimulate the proliferation of retinal vascular endothelial cells. The earliest appearance is that of fine tufts of delicate vessels forming arcades on the surface of the retina. As they grow, they may extend forwards through the internal limiting membrane of the retina to enter the preretinal (subhyaloid) space approaching the vitreous (Fig. 3). They are fragile and leaky and are liable to rupture, causing haemorrhage that may be intraretinal, pre-retinal (subhyaloid) or into the vitreous. The neovascular complexes and haemorrhages associated with proliferative retinopathy therefore lie in front of the retina and overlie retinal blood vessels. Serous products leaking from these new vessel systems stimulate a connective tissue reaction, retinitis proliferans. As it extends, the new vessels may be obliterated and the surrounding retina covered by a dense white sheet (Fig. 4).

### Maculopathy

Central vision may be lost or threatened as a result of microvascular leakage or occlusion at the macula. Macular oedema may be focal or diffuse and may be difficult to diagnose by direct ophthalmoscopy in the absence of hard

exudates, typically arranged in a complete or incomplete circle around the leaking microvascular abnormality (circinate maculopathy).

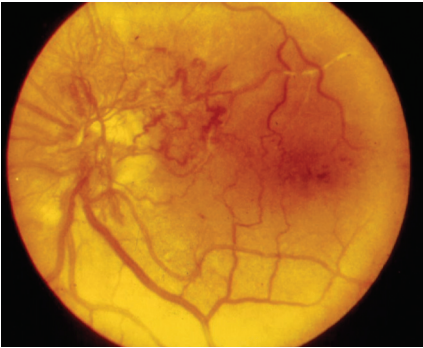


Fig. 3. Neovascularisation, capillary closure, venous dilatation and haemorrhages.

### Screening for diabetic retinopathy

Diabetic retinopathy is not only largely preventable, but timely laser therapy may preserve vision in most patients with retinopathy. All diabetic patients older than 12 years should have their visual acuity tested and retina examined at least annually. Vision-threatening retinopathy rarely occurs in type 1 diabetes in the first 5 years after diagnosis or before puberty. However, more than a quarter of patients with type 2 diabetes have been found to have retinopathy at diagnosis, and screening should start immediately. Pregnant patients require more frequent follow-up as retinopathy can progress rapidly during pregnancy.

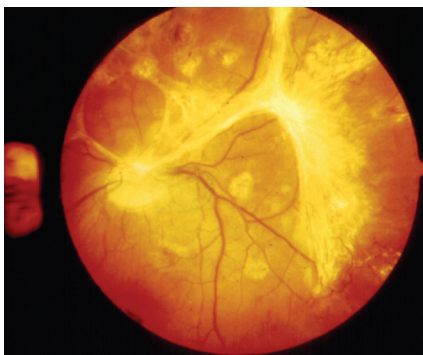


Fig. 4. Fibrous proliferation and scars from previous laser treatment.

### Pregnant patients require more frequent follow-up as retinopathy can progress rapidly during pregnancy.

Visual acuity should be tested with a Snellen chart or an E-chart. This should be done with patients wearing their spectacles or through a pinhole. Fundoscopy should be performed through dilated pupils in a darkened room. Tropicamide 1% eye drops are recommended since they are short-acting. Closed angle glaucoma is a contraindication for dilatation of the pupils but this condition is sufficiently rare not to avoid dilatation. Ideally, all patients with changes suggestive of diabetic retinopathy should be referred to an ophthalmologist. If not possible, at least patients with abnormalities listed in Table II should be referred.

#### Table II. Indications for referral to an ophthalmologist

- Reduced visual acuity from any cause
- Proliferative or preproliferative changes
- Clinically significant macular oedema
- Any form of progressing or extensive diabetic retinopathy especially when the lesions are near the macula

### DIABETIC NEPHROPATHY

About 30% of patients with both type 1 and type 2 diabetes develop diabetic nephropathy after 20 years, but the risk after this time falls to less than 1% per year. The risk for diabetic nephropathy is also not equal in all patients. The main risk factors associated with

the development of diabetic nephropathy are shown in Table III.

#### Table III. Risk factors for the development of diabetic nephropathy

- Poor control of glucose
- Long duration of diabetes
- Presence of other microvascular complications
- Ethnicity, e.g. black Africans, Asians
- Pre-existing hypertension
- Family history of diabetic nephropathy
- Family history of hypertension

Most of the data on the natural history of diabetic nephropathy come from the study of patients with type 1 diabetes. Diabetic nephropathy progresses from normoalbuminuria, through a sub-clinical stage of urinary albumin excretion called microalbuminuria to overt proteinuria and eventually end-stage renal disease (ESRD). However, renal disease may stop at any of these stages, regress, or be terminated by death. Microalbuminuria is also a strong risk factor for macrovascular disease in patients with type 2 diabetes. The limits of normo-, micro- and macroalbuminuria are shown in Table IV.

#### Screening for microalbuminuria

Microalbuminuria is an important indicator of risk for developing overt diabetic nephropathy. It is therefore most reliable as an indicator of diabetic nephropathy within the first 10 years of type 1 diabetes (the majority will progress to overt nephropathy within a further 10 years), and less reliable in older patients with type 2 diabetes, in whom other diseases may account for it. Vigorous efforts to improve control of blood glucose and to reduce blood pressure by instituting angiotensin-converting enzyme

**Table IV. The limits of normo-, micro- and macroalbuminuria**

| Normal range  | Microalbuminuria | Macroalbuminuria<br>(overt proteinuria) | Nephrotic syndrome<br>(proteinuria > 3.5 g/24 h) |
|---|------------------|---|--|
|   |                  |   |  |
| <b>Urinary albumin excretion rate:</b>                        |                  |   |  |
| Random sample:  |                  |   |  |
| < 30 µg/min   | 30 - 300 g/min   | > 300 g/min                             |  |
| Overnight sample:   |                  |   |  |
| < 20 µg/min   | 20 - 200 g/min   | > 200 g/min                             |  |
| <b>Urine albumin to creatinine ratio (spot urine sample):</b> |                  |   |  |
| <b>Men</b>  |                  |   |  |
| < 1.9 mg/mmol   | 1.9 - 28 mg/mmol | > 28 mg/mmol                            |  |
| <b>Women</b>  |                  |   |  |
| < 2.8 mg/mmol   | 2.8 - 40 mg/mmol | > 40 mg/mmol                            |  |

inhibitors or angiotensin II receptor antagonists may reduce the risk of progression of nephropathy in diabetic patients.

Screening for microalbuminuria in patients with type 1 diabetes should start 5 years after diagnosis and be done annually thereafter, while in type 2 diabetes it should

## **Microalbuminuria is an important indicator of risk for developing overt diabetic nephropathy.**

commence immediately after diagnosis and then be done at least annually. Although a semi-quantitative method for detecting microalbuminuria in spot or timed urine samples is available (Micral Test), using a specific assay for albumin is a more sensitive tech-

nique. A 24-hour urine collection is the gold standard for the detection of microalbuminuria. The result may, however, be affected by volume. The albumin-to-creatinine ratio in a spot urine sample has been recommended as the preferred screening strategy for all diabetic patients since it eliminates the effect of volume on the result. Three important caveats must be considered to maximise the reliability of this test:

- vigorous exercise can cause a transient increase in albumin excretion — patients should refrain from vigorous exercise in the 24 hours prior to the test
- the correlation is best if samples are taken in the mid-morning; mid-afternoon specimens are also relatively accurate
- albumin excretion will be underestimated in a muscular man with a high rate of creatinine excretion and overestimated in a cachectic patient in whom mus-

cle mass and creatinine excretion may be markedly reduced.

## **DIABETIC NEUROPATHY**

Diabetic neuropathy is a frequent long-term complication of diabetes. It eventually affects approximately 50% of patients with both type 1 and type 2 diabetes. Both the duration of diabetes as well as poor metabolic control contribute significantly to the development of diabetic neuropathy.

### **Classification**

Distinct clinical syndromes occur according to the neurological distribution but overlap syndromes are common (Table V).

### **Clinical features of distal symmetrical diabetic polyneuropathy**

This type of predominantly sensory neuropathy is the 'classic' diabetic neuropathy and is frequently associated with subclinical auto-



**Table V. Classification of diabetic neuropathy**

- Distal symmetrical polyneuropathy (sensory motor neuropathy)
- Focal mononeuropathies involving individual cranial (e.g. cranial nerve III) and peripheral nerves (e.g. median nerve)
- Mononeuritis multiplex or multiple mononeuropathies in the same patient (also called asymmetrical polyneuropathy)
- Autonomic neuropathy
- Polyradiculopathy caused by thoracic or lumbar nerve root disease

onomic neuropathy. Clinically apparent motor deficits develop only in rare, severe cases.

Apart from the severity and duration of diabetes other risk factors for this type of neuropathy include male sex, smoking, height, age and microalbuminuria. Up to 10% of newly diagnosed patients with type 2 diabetes may already have this type of neuropathy. The characteristic functional abnormality is a reduction in nerve conduction velocity resulting in increases in vibration perception threshold (served by large myelinated fibres) and in thermal discrimination threshold (served by fine unmyelinated fibres). Nerve damage worsens distally and with increasing length of the nerve, suggesting a cumulative effect of multiple 'hits', which could be either vascular or biochemical. Interestingly, acute lowering of blood glucose levels in patients whose control was very poor may transiently worsen peripheral nerve function often with pain and dyesthesiae ('insulin neuritis').

**Diabetic neuropathy is a frequent long-term complication of diabetes. It eventually affects approximately 50% of patients with both type 1 and type 2 diabetes.**

This diffuse symmetrical disorder generally affects the feet in a stocking distribution; symptomatic involvement of the hands is rare. Neuropathy in the legs is often symptomless initially with eventual complete loss of sensation in the feet accompanied by a numb feeling. Neuropathic patients may sometimes experience pain of varying severity in a stocking distribution. The pain is usually unrelated to the measurable severity of neuropathy. The most serious consequence of distal symmetrical neuropathy is the development of diabetic foot problems such as ulceration and infection. Neuropathic oedema may also occur as a result of increased blood flow due to autonomic neuropathy and loss of sympathetic innervation.

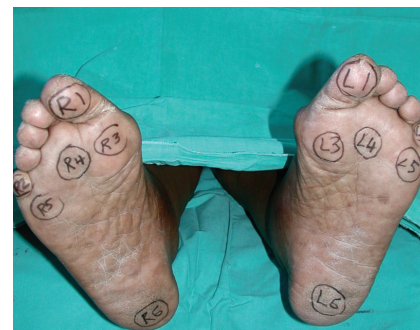### Screening for distal symmetrical diabetic neuropathy

Foot problems due to vascular and neurological disease are a common and important source of morbidity in diabetic patients. Systematic screening examinations for neuropathic and vascular involvement of the lower extremities and careful inspection of feet may substantially reduce morbidity from foot problems. It is recommended that the feet be examined at least annually in patients with type 2 diabetes and in those with type 1 diabetes for more than 5 years. Examination (Table VI, Figs 5 and 6) may reveal typical distal and symmetrical loss of pinprick and temperature sensation, progressing to loss of light touch and vibration. Clinical signs may often be much less impressive

than the patient's complaints would suggest. A subset of patients, usually young women with type 1 diabetes, may develop a distinct syndrome in which selective damage to small fibres causes severe sensory and autonomic loss. They develop symptomatic autonomic neuropathy, increased blood flow in the feet, and gastroparesis and/or diarrhoea, together with Charcot arthropathy and foot ulceration. These patients do not experience numbness of the feet and retain normal light touch and nearly normal vibration perception (large-fibre sensory modalities), while they are pain- and temperature-insensitive (small-fibre functions). This syndrome can be very destructive, and frequently results in ulceration of the feet and Charcot arthropathy.

### Clinical features of autonomic neuropathy

Autonomic neuropathy can affect virtually all bodily systems in any one patient (Table VII). Involvement tends to be patchy and either parasympathetic or sympathetic nerves may be predominantly affected in any one system



*Fig. 5. Six common areas of foot ulceration in patients with symmetrical diabetic polyneuropathy.*

or more. Overt autonomic neuropathy carries a poor prognosis: within 10 years of developing overt symptoms, 30 - 50% of patients die — many from sudden cardiorespiratory arrest.

**Table VI. A scheme for the evaluation of a diabetic patient's feet**

## Inspection

- Shoes: look inside for foreign bodies and inspect soles for uneven wear
- Skin: look for signs of atrophy, decreased sweating, callus formation, cracks, infection, macerated areas between the toes and trophic nail changes
- Shape: look for clawing of the toes, hallux valgus, Charcot deformity, wasting – motor neuropathy, previous surgery

## Palpation

- Abnormally warm feet may indicate infection, increased blood flow due to sympathetic denervation or acute Charcot foot
- Cold feet may indicate ischaemia
- Oedema may be due to neuropathy, infection, heavy proteinuria, heart failure, insulin therapy, calcium antagonists
- Decrease in power may be due to motor neuropathy
- Absence of both pulses in a foot indicates ischaemia

## Percussion

Record whether ankle reflexes are:

- absent
- present with reinforcement
- present without reinforcement

## Perception

- 5.07 U nylon monofilament (Semmes-Weinstein)
  - apply to the six most common sites for ulceration (Fig. 5)
  - apply until buckle ( $\approx$  10 gramme force) (Fig. 6)
  - failure to detect pressure at any site has a sensitivity of  $> 90\%$  to predict ulceration
- Pin prick – Dorsum of big toe (painful or not)
- Vibration – use a 128-Hz tuning fork

Apply tuning fork to bony prominence at the dorsum of the first big toe, just proximal to the nail bed or to the medial malleolus

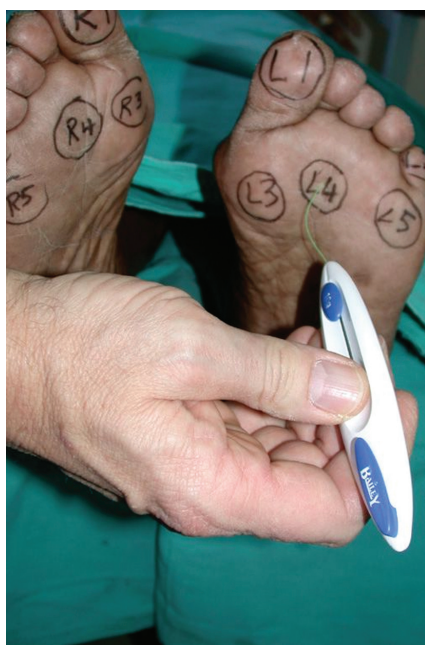

Fig. 6. 5.07 U Semmes-Weinstein nylon monofilament buckling under a force of 10 g.

## Screening for diabetic autonomic neuropathy

The hallmark of cardiovascular autonomic neuropathy is exercise intolerance and orthostatic hypotension. Exercise intolerance is due to impaired augmentation of cardiac output resulting from inadequate sympathetic modulation. Cardiac denervation can also occur in diabetic patients with advanced autonomic neuropathy. It is characterised by a fixed heart rate, in the range of 80 - 90 beats per minute, and is associated with painless myocardial infarction and sudden death. Postural hypotension is defined as an orthostatic fall in systolic blood pressure in excess of 20 mmHg. It results from a combination of central and peripheral cardiovascular sympathetic denervation. Loss of the diurnal variation in blood pressure and supine hypertension occurring at

**At primary health care level diabetic autonomic neuropathy may be suspected by taking a careful history and by careful bedside recording of pulse rate and rhythm, followed by measuring supine and standing blood pressure.**

night frequently accompany orthostasis. Insulin therapy and meals may exacerbate symptoms of orthostatic hypotension. At primary health care level diabetic autonomic neuropathy may be suspect-

**Table VII. Clinical features of diabetic autonomic neuropathy**

|  |  |
|--|--|
| <p><b>Cardiovascular</b></p> <ul style="list-style-type: none"> <li>• Postural hypotension</li> <li>• Resting tachycardia</li> <li>• Fixed heart rate</li> </ul> <p><b>Gastrointestinal</b></p> <ul style="list-style-type: none"> <li>• Dysphagia, due to oesophageal atony</li> <li>• Abdominal fullness, nausea and vomiting, unstable diabetes due to delayed gastric emptying ('gastroparesis')</li> <li>• Nocturnal diarrhoea</li> <li>• Constipation, due to colonic atony</li> </ul> <p><b>Genitourinary</b></p> <ul style="list-style-type: none"> <li>• Difficulty in micturition, urinary incontinence, recurrent infection, due to atonic bladder</li> <li>• Impotence and retrograde ejaculation</li> </ul> | <p><b>Sudomotor</b></p> <ul style="list-style-type: none"> <li>• Gustatory sweating</li> <li>• Nocturnal sweats without hypoglycaemia</li> <li>• Anhidrosis: fissures in the feet</li> </ul> <p><b>Vasomotor</b></p> <ul style="list-style-type: none"> <li>• Feet feel cold, due to loss of skin vasomotor responses</li> <li>• Dependent oedema, due to loss of vasomotor tone and increased vascular permeability</li> <li>• Bullous formation</li> </ul> <p><b>Pupillary</b></p> <ul style="list-style-type: none"> <li>• Decreased pupil size</li> <li>• Resistance to mydriatics</li> <li>• Delayed or absent reflexes to light</li> </ul> |
|--|--|

ed by taking a careful history and by careful bedside recording of pulse rate and rhythm, followed by measuring supine and standing blood pressure.

#### FURTHER READING

- UpToDate* Vol. 2003; **11**(1).  
 Pickup JC, Williams G, eds. *Textbook of Diabetes*. Blackwell Science, 1997.  
 Haslet C, Chilver ER, Boon NA, Colledge NR, eds. *Davidson's Principles and Practice of Medicine*. 19th ed. Churchill Livingstone, 2002.

### IN A NUTSHELL

The overall prevalence of diabetic retinopathy and neuropathy exceeds 50%.

Preproliferative diabetic retinopathy includes venous beading, multiple cotton wool spots, IRMAs, and multiple haemorrhages.

Annual screening for diabetic retinopathy through dilated pupils should start immediately after diagnosis in patients with type 2 diabetes and after 5 years in patients with type 1 diabetes.

Diabetic nephropathy is the most common cause of end-stage renal failure in developed countries.

Diabetic nephropathy progresses from normoalbuminuria, through a stage of microalbuminuria to overt proteinuria and eventually to end-stage renal disease.

Annual screening for microalbuminuria and distal symmetrical diabetic neuropathy should commence immediately after the diagnosis of type 2 diabetes and 5 years after the diagnosis of type 1 diabetes.

Failure to detect pressure by a 5.07 U nylon monofilament at selected areas on the plantar aspects of the feet in a diabetic patient has a sensitivity of > 90% to predict ulceration.

Overt autonomic neuropathy carries a poor prognosis and patients may die from sudden cardiorespiratory arrest.

Optimal glycaemic (HbA1c  $\leq$  7.0%) and blood pressure control ( $\leq$  130/80 mmHg) significantly reduce the development of microvascular complications.