



JACQUES
VILJOEN

MB ChB, MMed ORL

**Private ENT
Surgeon**

Linmed Hospital
Benoni and
Brooklyn Surgical
Centre and
Montana Hospital
Pretoria

Dr Jacques Viljoen is an ear, nose and throat surgeon in private practice at the Linmed Hospital, Benoni and Montana Hospital and the Brooklyn Surgical Centre in Pretoria. He takes a keen interest in rhinology, especially aesthetic nose surgery and the management of rhino-sinusal condition, as well as microscopic ear surgery.

Epistaxis in children: approach and management

Nose bleeds can be intimidating for the child, the parents and the doctor alike.

Epistaxis (Greek for nose bleed) has been with humans from the earliest times, often causing ill-founded anxiety in patients. The majority of epistaxis episodes in children is from local origin and rarely requires resuscitation. Although it may be intimidating to the attending physician, it can be managed effectively with a few acquired skills. Recurrent nose bleeds are an irritating, sometimes embarrassing problem to both the child and parent, as they often occur unexpectedly.

EPIDEMIOLOGY

In the USA, 5 - 14% of patients will have at least one episode of epistaxis per year; only 10% of these patients will see a physician, only 10% of whom will be referred to an otolaryngologist.

Epistaxis is rarely seen in infants under 2 years of age. Approximately 40% of children will have presented with at least one episode of epistaxis by the age of 5 years. In the age group 6 - 10 years the incidence increases to 56%.

Although very little data is available, epistaxis

seems to be more prevalent in young males.

Epistaxis is commonly encountered during autumn and winter when a lower environmental humidity and frequently alternating temperatures prevail. The higher incidence of upper respiratory tract infections (URTIs) in children during winter months also contributes to nose bleeds.

ANATOMY

The nasal mucosa has a rich vascular supply originating from the internal and external high-pressure carotid systems.¹⁻³ The internal carotid artery's first intracranial branch is the ophthalmic artery which eventually gives rise to the anterior and posterior ethmoid arteries. The external carotid artery supplies blood to the nose via the internal maxillary and facial arteries (Fig. 1).

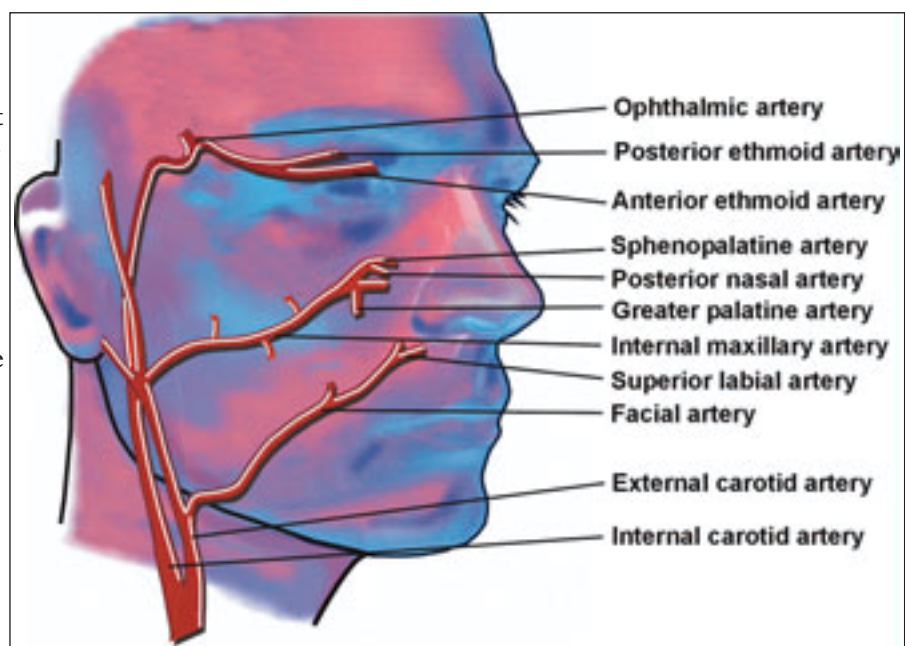


Fig. 1. Branches of the internal and external carotid artery supplying the nose.

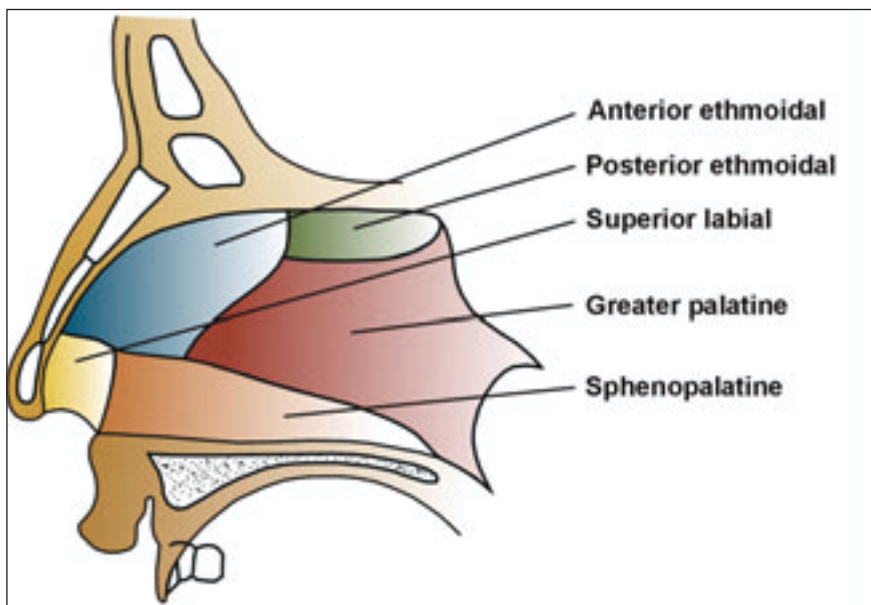


Fig. 2. Blood supply of the nasal septum.

There are two important areas in the nose that play a role in epistaxis:

- Kiesselbach's plexus (anterior bleeds), also known as Little's area; located on the anterior nasal septum, formed by an anastomosis between the vessels illustrated in Fig. 2.
- Woodruff's plexus (posterior bleeds); located over the posterior or middle turbinate, formed by an anastomosis between the vessels illustrated in Fig. 3.

AETIOLOGY OF EPISTAXIS

Ninety per cent of epistaxis in children originates from Little's area in the anterior part of the nose, often being either idiopathic or the result of trauma. Idiopathic epistaxis forms the most common aetiological category (Table I).

Although bleeding may occur spontaneously, it often results from forceful nose blowing and sneezing which increases arterial and venous pressure in the vascularised nasal septum, which usually accompanies allergic rhinitis, viral/bacterial URIs and trauma/sepsis secondary to foreign bodies.

Posterior epistaxis is uncommon in children and is usually the result of

bleeding disorders, inflammatory disorders or neoplasms. Persistent or recurrent epistaxis should raise the suspicion of bleeding disorders or neoplasms, necessitating further investigation.

The most common causes of epistaxis in children are outlined in Table I.

APPROACH AND MANAGEMENT

Taking a proper history and performing a thorough systemic examination are imperative to rule out the possibility of the bleeding being the result of systemic disease or

bleeding disorders (petechiae, purpura, ecchymosis, hepatosplenomegaly), which will necessitate further investigations. Up to one-third of habitual nose bleeds in children may be due to a blood dyscrasia.⁵ A positive family history and prolonged partial thromboplastin time (PPT) are useful predictive criteria. Resuscitation is seldom required in children and always signifies more complex cases.

A. Non-surgical management

As the majority of epistaxis in children originates from the anterior or caudal septum, venous bleeding will often cease with pinching of the nostrils in an upright position. Fresh blood and clots should be removed with suction. Topical vasoconstrictors, packing and cauterisation will stop the bleeding effectively in 85% of cases. It is often difficult to locate the source of the bleeding and there is little gain in random cautery of Kiesselbach's plexus on the nasal septum. Chemical cautery and diathermy have proved to be equally effective,⁶ and uncomplicated idiopathic epistaxis can be successfully managed with topical application of mupirocin (Bactroban), fusidic acid (Fucidin) or neomycin (Naseptin) for 30 days.⁷⁻⁹ Systemic and topical oestrogens are reserved for the

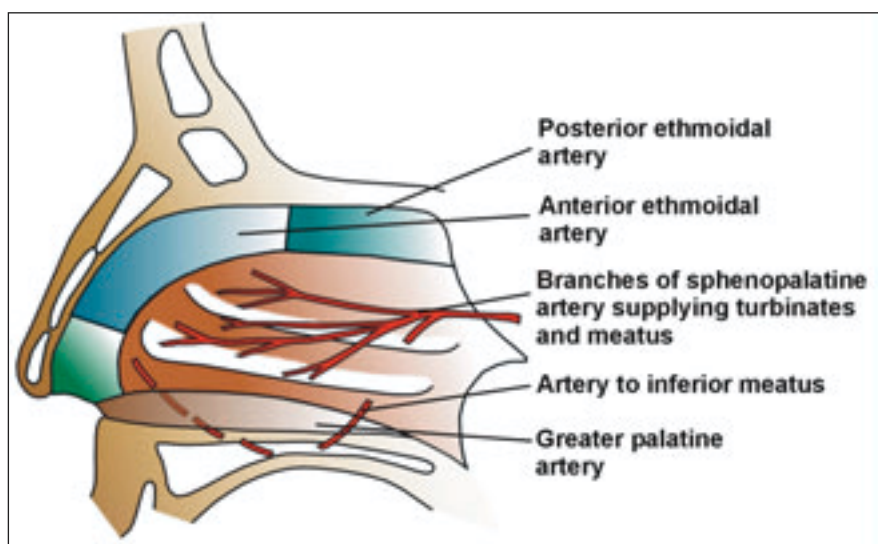


Fig. 3. Blood supply of the lateral wall of the nose.

MAIN TOPIC

Table 1. Most common causes of epistaxis in children

Local
Acquired
Infective
Acute
Viral
Bacterial
Fungal
Chronic
Specific
Tuberculosis
Inflammatory
Rhinosinusitis (allergic/vasomotor)
Nasal polyposis (cystic fibrosis, allergies)
Trauma
Iatrogenic
Facial
Digital (nose picking)
Foreign body/ rhinolith
Surgery (carotid aneurysm)
Idiopathic (refer to mild recurrent nose bleeds)
Little's area
Superior part of nose
Middle meatus
Woodruff's plexus
Neoplastic
Benign
Haemangioma
Malignant
Lymphoma
Drug-induced
Rhinitis medicamentosa (topical decongestants/cocaine)
Inhalants
Tobacco
Environmental
High altitude
Rapid temperature alterations
Dry conditions
General
1. Bleeding disorders
A. Coagulopathies
Inherited: coagulation factor deficiencies, i.e. factor VII (haemophilia A, B) and factor IX deficiency
Acquired: anticoagulants, chronic liver disease, vitamin K deficiency
B. Platelet disorders
Thrombocytopenia: congenital acquired – marrow failure; aplasia, drugs, infiltration, hypersplenism, massive blood loss
Platelet dysfunction: congenital – Von Willebrand's disease
acquired – myeloproliferative disease/leukaemia
C. Blood vessel disorders: congenital – hereditary haemorrhagic telangiectasis
acquired – vitamin C deficiency
D. Hyperfibrinolysis: congenital – alpha-2 antiplasmin deficiency
2. Drugs (see 1B)
Aspirin
Anticoagulants
Chloramphenicol
Methotrexate
Immunosuppression
Dipyrimadole
3. Neoplasms (see 1B)
4. Idiopathic
Inflammatory disorders
Wegener's
5. Others
HIV

Adapted from Scott-Brown's Otolaryngology 6th ed., volume 4, chapter 18.¹⁴

management of hereditary haemorrhagic telangiectasis and should not be used routinely in the management of general epistaxis.¹⁰ Diathermy under local anaesthesia can be a traumatic experience to a child and is generally not recommended, at least not without sedation. Simultaneous diathermy of both sides of the nasal septum is not recommended as it may result in septal perforation.

Since posterior epistaxis is uncommon, it is seldom necessary to utilise balloon tamponade in children, although the relative ease of insertion renders it useful. Any patient receiving a posterior pack should be hospitalised. Posterior packing is left in the nose for 2 - 3 days, constantly reducing the volume of the balloon to avoid local tissue necrosis.

It is most important to be adequately equipped to manage epistaxis effectively and with confidence, and the following items will prove useful (Fig. 4):

- Headlamp
- Cocaine — 5% solution
- Gloves, gown, mask
- 14F Foley's catheter
- Suction apparatus
- K-Y gel
- McGill sucker
- Elastoplast (25 mm wide)
- Nasal speculum
- 5 ml syringe
- Tongue depressor
- Bismuth iodoform paraffin paste (BIPP)
- Tilley's forceps/bayonet forceps
- 20 mm ribbon gauze
- Cotton patties (Codman patties)
- Merocel
- Gauze
- Balloon tampon
- Scissors
- Kidney dish.

The method of anteroposterior packing is as follows (Fig. 5):

- Suction the nose.

MAIN TOPIC

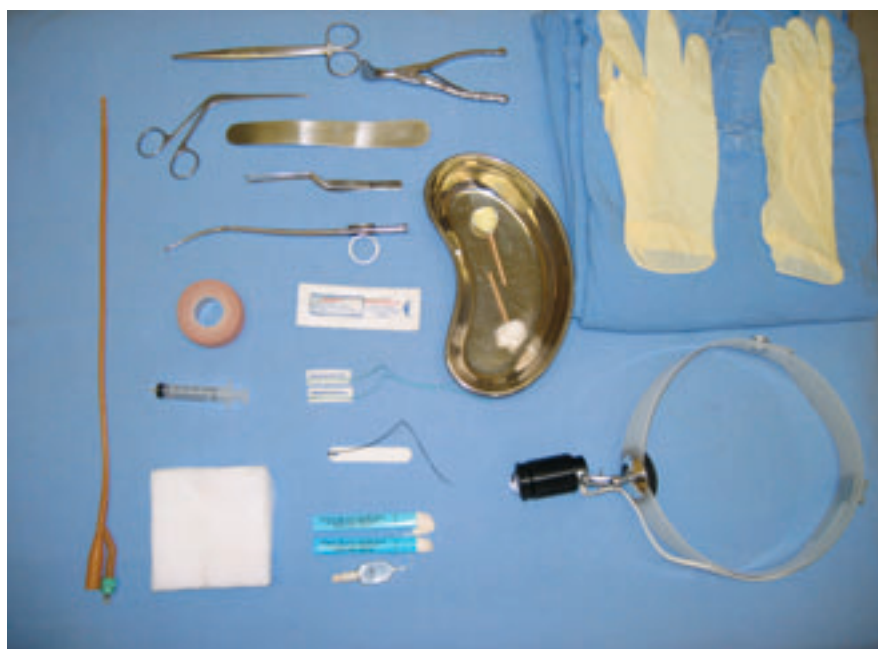

Fig. 4. Useful items with which to manage epistaxis effectively.

- Remove the tip of the Foley's catheter distal to the balloon, as it irritates the throat.
- Advance the Foley's catheter through the bleeding nasal passage, until it is visible in the oropharynx.
- Fill the balloon with 4 ml of water, and pull it into the nasopharynx.
- Insert BIPP/Vaseline ribbon gauze in layers in the nasal passage around the catheter.
- While maintaining slight traction on the catheter, wrap the 25 mm Elastoplast around the catheter at the nostril to create a plug.

The concurrent use of either laser therapy or diathermy with endoscopy, has certainly enhanced the management of epistaxis.^{11,12} Surgical intervention (arterial ligation, submucosal resection) and embolisation are reserved as a last resort and are seldom necessary in children.¹³

Patients with the following conditions require referral to an ENT specialist:

- Recurrent, troublesome epistaxis
- Uncontrollable epistaxis
- Posterior epistaxis
 - haemotympanum
 - bleeding in nasopharynx/mouth
- Identifiable causes requiring specialist management
 - facial trauma
 - polyps
 - tumours.

B. Surgical management

Indications for surgery are as follows:

- Failure of medical management after 48 hours
- Patient refusal of medical management
- Need for blood transfusion.

Surgical management includes the following:

- Arterial ligation
 - Transmaxillary internal maxillary artery ligation
 - Anterior/posterior ethmoid artery ligation
 - External carotid artery ligation
 - Transnasal endoscopic sphenopalatine artery ligation.¹⁴
- Submucosal resection (SMR)/septoplasty.

C. Embolisation

Embolisation of the internal maxillary artery is effective and safe. It was initially reserved for patients in whom surgery failed, although recent literature supports embolisation as first-line treatment in *specified* cases because of safer procedures and increased experience.¹⁵

References available on request.

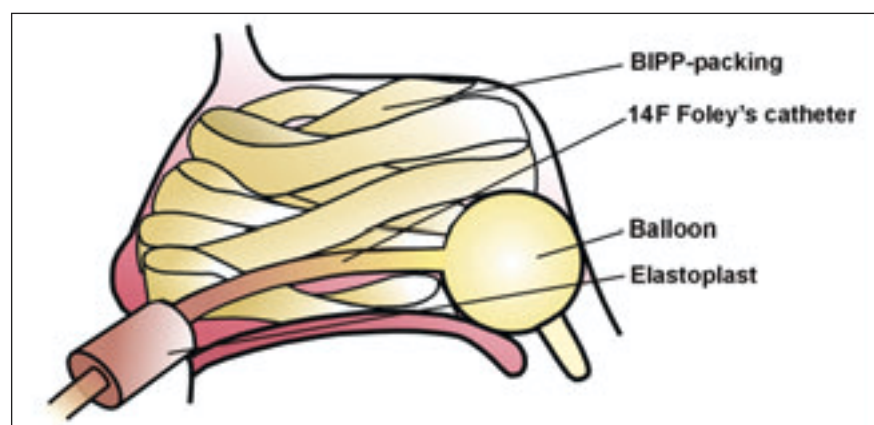


Fig. 5. Method of anteroposterior nasal packing.

