

# More about...Vascular surgery

## What's new in varicose veins?

MARTIN V FORLEE, MB ChB, FCS (SA),  
Cert Vasc Surg (SA)

Vascular Surgeon, Kingsbury Hospital,  
Cape Town, and Honorary Senior Lecturer,  
Department of Surgery, University of Cape  
Town and Groote Schuur Hospital

E-mail: martin@suricare.co.za

The fundamentals of varicose vein surgery have not changed for many decades and conventional open surgery remains the gold standard against which other treatment modalities are measured. Conventional open surgery is, however, not without problems. The recurrence rate is 10 - 15% at 2 years and as high as 60 - 70% after 20 years.<sup>1</sup> Approximately 25% of patients require further surgery and recurrent disease accounts for 20% of all varicose vein surgery.<sup>1</sup> Despite being a relatively minor procedure for a non-life-threatening condition, varicose vein surgery is a common reason for litigation, accounting for 17% of settled claims in general/vascular surgery. Complications include cutaneous nerve injury (5 - 7%), haematoma (10%), deep vein thrombosis (DVT) (<2%), pulmonary embolism (0.2 - 0.5%), wound infection and pain.

Endovascular techniques have revolutionised arterial vascular surgery, and a number of techniques in venous surgery are challenging the role of open surgery. These include radiofrequency ablation (RFA), endovenous laser therapy (EVLT), and foam-injection sclerotherapy (FS). Radiofrequency and laser ablation are alternatives to stripping of the greater saphenous vein (GSV). Peripheral varicosities still need treatment with hook phlebectomy or FS. The latter can be used to treat truncal incompetence and peripheral varicosities. These procedures have the advantages that they are minimally invasive and can be performed under local anaesthesia (as a hospital outpatient) or in the consulting room, with similar overall outcomes compared with surgery. All three techniques rely fairly heavily on duplex ultrasound technology.

The problem for the surgeon considering these techniques is the relative lack of controlled trials, particularly with regard to long-term follow-up. This is despite the

fact that all the new modalities have been available for some years.

### Radiofrequency ablation (RFA)

RFA uses thermal energy to cause collagen contraction and destruction of the vein wall. The radiofrequency catheter is placed percutaneously into the vein and positioned using ultrasound duplex for guidance. A layer of fluid containing local anaesthetic is infiltrated along the entire length of the vein to be treated. This is known as tumescent anaesthesia and provides excellent analgesia as well as causing contraction of the vein. Furthermore, the 'pool' of fluid around the vein absorbs heat and prevents damage to the skin and surrounding tissues.

There are a number of case series documenting the efficacy and safety of RFA. A large, prospective, multicentre registry involving over 1 000 patients showed an immediate success rate of 91%.<sup>2</sup> This was sustained over time, with a vein occlusion rate of 88% at 4 years. The EVOLVEs Trial, although the numbers were small, was able to demonstrate a similar early efficacy and complication rate to surgery, with an earlier return to work and normal activity. Although the procedure is more costly than a traditional surgical procedure, it is ultimately more cost efficient if one takes into account the work days lost.<sup>3</sup>

Complications of RFA treatment include focal paraesthesia (12% at 1 week), DVT (0.5%), pulmonary embolus (PE), phlebitis, infection, and skin burns (0.5%).

### Endovenous laser therapy (EVLT)

Although the technique of endovenous laser is almost identical to that of RFA, the mechanism of action is very different. Laser energy causes the blood in the vein to boil and the steam bubbles generated cause thermal damage to the vein wall. There are many case series that document the efficacy and safety of laser. A large case series involving almost 500 patients showed a 99.3% immediate technical success rate. There was a 7% recurrence rate at 2 years.<sup>4</sup> All recurrences were evident by 9 months and the majority before 3 months. Two small randomised controlled trials comparing EVLT to surgery show similar early efficacy with earlier return to work in favour of laser.<sup>5,6</sup> The most common side-effect of laser is a feeling of 'tightness' or 'pulling' along the treated vein (90%). Pigmentation or bruising (24%) and

thrombophlebitis (5%) are the next most common complications. These are fairly minor, do not need intervention and usually resolve spontaneously.

### Foam-injection sclerotherapy (FS)

Ultrasound-guided FS has rejuvenated the use of sclerotherapy in the treatment of major truncal varices. In FS the sclerosant is mixed with air or CO<sub>2</sub> in a 1:3 or 1:4 ratio to form a mousse. When injected into the vein, the air displaces blood and this, together with the larger surface area of the sclerosant in the wall of the air bubble, results in greater endothelial exposure to the sclerosant and increased efficacy. The foam bubbles are echo-dense, and with a combination of elevation and massage can be manipulated into the desired branch varicosities.<sup>7</sup>

The evidence for FS is again in the form of large case series. A recent systematic review for the National Institute of Clinical Excellence in the UK showed an immediate technical success with an overall occlusion rate of 84% (67 - 94%). Long-term results are not yet known.

Most adverse events are fairly minor, the commonest being skin pigmentation in up to 40% of patients. There has been concern with regard to the potential consequences of micro-embolisation of foam particles. Transient visual disturbance and cough after the procedure are fairly common.

### Conclusion

All three endovenous techniques have been shown to have short and intermediate results at least equivalent to surgery, while offering decreased recovery times. It will be a number of years before long-term data (>10 years) are available. Randomised controlled trials are necessary to compare the newer techniques with surgery and with each other.

### References

1. Perrin MR, Guex JJ, Ruckley CV, *et al*. Recurrent varices after surgery (REVAS), a consensus document. REVAS group. *Cardiovasc Surg* 2000; 8(4): 233-245.
2. Merchant RF, Pichot O, for the Closure Study Group. Long-term outcomes of endovenous radiofrequency obliteration of saphenous reflux as a treatment for superficial venous insufficiency. *J Vasc Surg* 2005; 42: 502-509.
3. Lurie F, Cretton D, Eklof B, *et al*. Prospective randomised study of Endovenous Radiofrequency Obliteration (Closure) Versus Ligation and Vein Stripping (EVOLVEs):

## More about...

- Two-year follow-up. *Eur J Vasc Endovasc Surg* 2005; 29: 67-73.
- Min RJ, Khilnani N, Zimmet SE. Endovenous laser treatment of saphenous vein reflux: long-term results. *J Vasc Interv Radiol* 2003; 14: 991-996.
  - Rautio T, Ohinmaa A, Perala J, *et al.* Endovenous obliteration versus conventional stripping operation in the treatment of primary varicose veins: a randomized controlled trial with comparison of the costs. *J Vasc Surg* 2002; 35: 958-965.
  - Rasmussen LH, Bjoern L, Lawaetz M, Blemings A, Lawaetz B, Eklof B. Randomized trial comparing endovenous laser ablation of the great saphenous vein with high ligation and stripping in patients with varicose veins: short-term results. *J Vasc Surg* 2007; 46: 308-315.
  - Breu FX, Guggenbichler S, Wollmann JC. 2nd European Consensus Meeting on Foam Sclerotherapy, 28 - 30 April 2006, Tegernsee, Germany. *Vasa* 2008; 37(Suppl. 71): 1-32.

## Endovascular intervention in arterial trauma

**NISHEN PARUK, MB ChB, FCS (SA),  
Certificate Vascular Surgery**

*Senior Specialist, Department of Vascular Surgery, Inkosi Albert Luthuli Central Hospital, Nelson R Mandela School of Medicine, and Durban Metropolitan Vascular Service*

E-mail: nparuk@worldonline.co.za

Endovascular intervention in the management of arterial trauma is a new frontier in medicine. Endovascular techniques have been successful in the treatment of chronic peripheral vascular occlusive and aneurysmal arterial disease. A natural progression has been the use of such technology in the management of arterial trauma. Conventional open surgical repair, although still the gold standard, is being rapidly overtaken by endovascular techniques. Numerous reports are now showing this technology to be effective and safe. South African vascular surgeons and interventionists continue to be at the forefront of developing techniques in the management of civilian arterial vascular trauma and have already published extensively on the use of endovascular techniques.

The major attraction of endovascular techniques is their minimally invasive nature compared with open surgery. The benefits of endovascular techniques include the avoidance of a median sternotomy or thoracotomy, less blood loss and fluid shifts, avoidance of an aortic cross clamp with its complications of reperfusion

injury and the fact that extracorporeal bypass is not required.

Disadvantages of endovascular repair include:<sup>1</sup>

- device-related complications, such as migration, stent fracture, occlusion and endoleaks
- the need for ongoing surveillance (clinical examination and radiological follow-up)
- that the trauma patient is often young with a normal lifespan
- that the long-term durability of this technology is yet to be defined
- inappropriate sizing of devices – aortic endovascular stent grafts are designed for older patients with ectatic and aneurysmal vessels and not for the relatively narrow aorta of a young trauma patient.

The aetiology, common pathology encountered with arterial trauma, diagnosis and well-established investigation protocols in vascular trauma remain unchanged.

### Aetiology of vascular trauma<sup>2</sup>

Stab wounds remain the commonest cause of vascular trauma managed by the Durban Metropolitan Vascular Service, followed by gunshot wounds and blunt trauma (usually motor vehicle accidents). Blast injury has been identified as a less common cause of arterial trauma. Iatrogenic vascular injury is increasing owing to the burgeoning use of vascular technology in all fields of medicine. Injuries include groin access-site vessel thrombosis and false aneurysm formation during cardiac catheterisation and during the use of aortic balloon pumps, inadvertent arterial trauma at haemodialysis catheter insertion and arterial dissection, and thrombosis with diagnostic catheter-based procedures.

### Pathology

- Complete arterial transection.
- Partial laceration.
- False aneurysm.

- Arteriovenous fistula.
- Intimal thrombosis.

The diagnosis of arterial trauma is given in Table I.

Hard signs of a vascular injury leave no doubt that the arterial circulation has been compromised. Soft signs, however, demand further investigation to exclude a vascular injury. Haemodynamically unstable patients with hard signs of a vascular injury are usually transported immediately to theatre for open surgical management. In stable patients there is time for imaging and planning of an endovascular intervention or appropriate incision for open surgical exposure.

### Materials and method for a successful endovascular intervention

- Catheter-based skills are required.
- Angiographic facilities – ideally an endovascular operating suite with facilities for both angiography and open surgery.
- Vascular access sheaths, diagnostic catheters and guide wires to select the vessel of interest (Figs 1 - 3).




Fig. 1. Vascular access sheath.

**Table I. Diagnosis of arterial trauma<sup>3</sup>**

Hard signs	Soft signs
Active bleed	History of bleed or shock
Expanding pulsatile haematoma	Stable haematoma
Absent pulses	Pulse discrepancy
Ischaemic limb	Associated nerve injury
Machinery murmur	
Bruit	




Fig. 2. Diagnostic catheters.



Fig. 3. Guide wires.

**Tools used to achieve haemostasis**

- covered stent grafts – fluency (Bard Peripheral Vascular, New Jersey, USA), Gore Viabahn (WL Gore and associates, Flagstaff, Arizona), Jostent (Abbott Laboratories, Santa Clara, California)
- embolisation – coils (stainless steel and platinum), gel foam, embospheres
- balloon occlusion devices
- bare metal stents (nitinol or stainless steel).

Figs 4 and 5 are images showing a bare metal stent and covered stent grafts (Viabahn), respectively.




Fig. 4. Bare metal stent.




Fig. 5. Covered stent grafts.

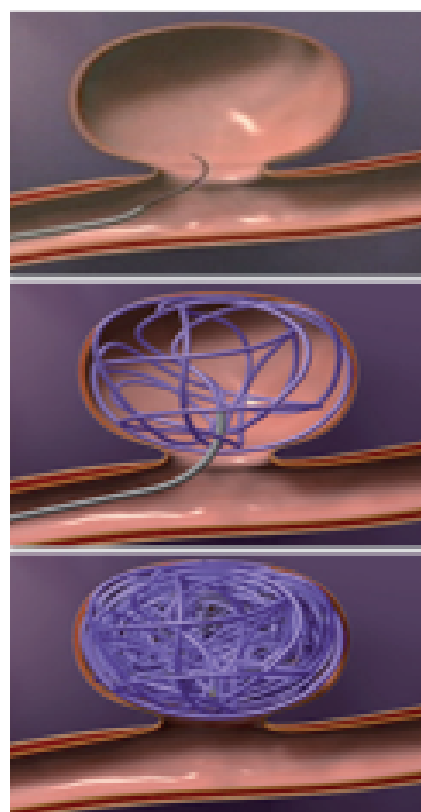


Fig. 6. Coil embolisation technique.



Fig. 7. The Tornado coil.

Figs 6 and 7 depict the coil embolisation technique and the Tornado coil (Cook, Bloomington, Indiana), respectively.

**Carotid artery injury**

Open surgical repair remains the gold standard. The use of covered stent technology is attractive, especially in areas that are difficult to access, including zone 1 and zone 3 of the neck (Appendix A). Covered and bare metal stents have been used successfully<sup>4</sup> to treat false aneurysms, arteriovenous fistulas<sup>5</sup> and carotid artery dissections. Balloon occlusion techniques have also been used to sacrifice surgically inaccessible segments of the internal carotid artery beyond the base of the skull. However, caution is warranted as the risk of distal cerebral embolisation is high with manipulation of catheters and guide wires, resulting in stroke.

**Vertebral artery injury**

Injury to the vertebral artery remains underreported and undiagnosed. The natural history of injury to this vessel is yet to be determined. Most vascular surgeons manage these injuries (false aneurysms, arteriovenous fistulas) aggressively in view of the risk of distal embolisation, with resultant posterior cerebral circulation infarcts. With vertebral artery ligation, the incidence of brain stem ischaemia remains relatively low – 3.1% for the left and 1.8% for the right.<sup>6</sup> The technical difficulty associated with open vertebral artery exposure within the bony canal or at the base of the skull and accompanying risks of injury to the vertebral venous plexus and adjacent spinal nerve roots have resulted in endovascular techniques being the standard of care for vertebral artery trauma. The affected vertebral artery is often sacrificed using embolisation techniques. Mwipatayi *et al.*, in their experience of 101 vertebral artery injuries over 15 years, with 33 radiological interventions performed, concluded that angiography and intervention are of great benefit in the management of such injuries.<sup>7</sup>



## More about...

The Durban Metropolitan Vascular Service, with its experience of 17 vertebral artery injuries managed endovascularly (embolisation and covered stent), yielded a technical success rate of 94%.<sup>2,8</sup>

### Axillo-subclavian artery injuries

Pre-hospital mortality rates with subclavian artery injury remain high at 75%.<sup>9</sup> Surgical management of these often complicated and poorly accessible vessels is accompanied by high peri-operative mortality rates of 12 - 30%. Embolisation of branch vessel injury (e.g. thyrocervical trunk, costocervical and internal mammary artery) has proved successful.<sup>2,8</sup>

The use of covered stent technology is extremely attractive for first-part subclavian artery injuries as a median sternotomy or left thoracotomy, as proximal control is avoided.<sup>10</sup> Stent graft occlusion due to compression at the level of the 1st rib in the management of 2nd- and 3rd-part subclavian artery injury is a realistic concern. The excellent collateral supply of the upper limb however allows one to correct this occlusion in an elective setting via open surgery in a now stable patient.

The use of these techniques in axillo-subclavian trauma has allowed the Durban Metropolitan Vascular Service to reduce its peri-operative major complication rate (death/stroke/limb loss) of 12% (1994 - 1997) to 2.3% (2004 - 2008).<sup>2</sup>

Fig. 8 (a and b) shows a false aneurysm of a branch of the thyrocervical trunk managed successfully with coil embolisation.

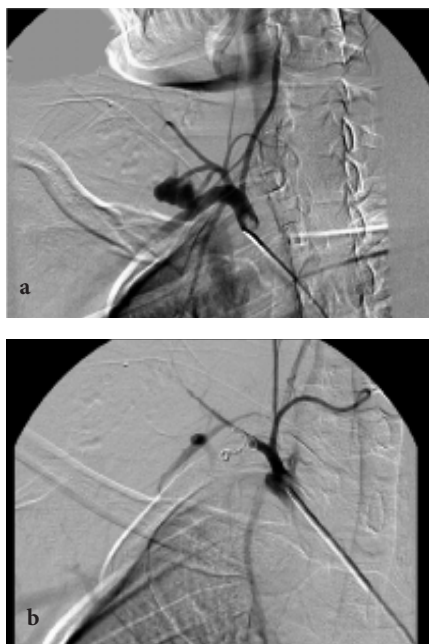

Fig. 8 (a and b). False aneurysm of a branch of the thyrocervical trunk managed successfully with coil embolisation.

Fig. 9 (a and b) shows a 2nd-part subclavian artery arteriovenous fistula managed successfully with a Gore Viabahn stent.

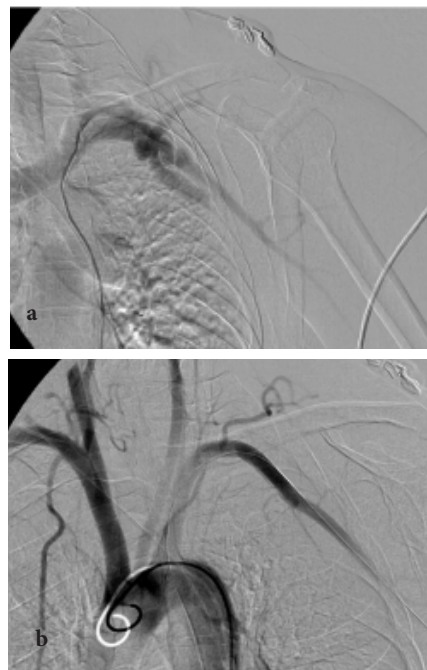


Fig. 9 (a and b). Second-part subclavian artery arteriovenous fistula managed successfully with a Gore Viabahn stent.

### Iliac artery and its branches

Internal iliac artery catheterisation and embolisation of its actively bleeding branches is now commonplace in the acute management of blunt abdominal and pelvic trauma. Exploring a pelvic haematoma often results in uncontrolled venous bleeding as the tamponade effect of the retroperitoneal tissue is lost. Catheter-based angiography allows diagnosis of injury to branches of the internal iliac artery and therapeutic embolisation with coils, gel foam or embospheres to isolate a transected vessel or false aneurysm. This is often a life-saving intervention in a severely injured patient.

### Peripheral lower limb vessel injury

Injury to the superficial femoral artery and popliteal and infrapopliteal (crural) arteries may also be managed endovascularly. The superficial femoral artery however is easily accessible surgically and is best managed via open techniques. The popliteal artery is subject to flexion and compression forces, which place any covered stent graft at risk of thrombosis. Improved technology means that more flexible stents are available but the perfect stent for this area has yet to be developed. As the devastating consequences of stent graft occlusion in the popliteal artery are loss of the limb, these injuries are best managed by traditional open surgical techniques using reverse saphenous vein graft interposition.

Injury to a single infrapopliteal artery (anterior and posterior tibial and peroneal artery) may be managed by open surgical repair, sacrifice of the vessel with use of embolisation or use of covered stents to preserve vessel continuity.

### Thoracic aortic injury

Endovascular management of a thoracic aortic injury deserves special mention. A common mechanism of injury is acceleration/deceleration-type motor vehicle accidents with subsequent 'tearing' of the thoracic aorta just distal to the left subclavian artery origin. Eighty-five per cent of such patients will die at the accident scene. Of those patients reaching hospital, common mortality figures quoted are 30% at 6 hours and 50% at 24 hours.<sup>11</sup> Institution of B blockade has reduced rupture risk.

Conventional open surgery carried a high mortality rate with the need for a left thoracotomy, aortic clamping, and heparinisation with extracorporeal bypass in a patient with multi-system injury, including head and abdominal trauma and associated long bone fractures.

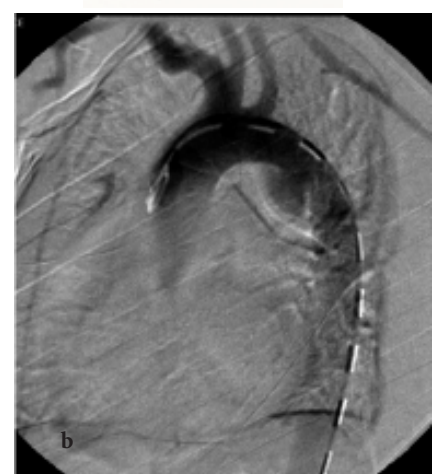

Fig. 10 (a and b). An aortic stent graft and angiogram with a proximal thoracic aortic transection.

The significant reduction in both peri-procedural mortality and paraplegia rates with endovascular repair has greatly contributed to endovascular stent grafts replacing open repair.<sup>12</sup>

Fig. 10 (a and b) shows an aortic stent graft and angiogram with a proximal thoracic aortic transection.

Table II lists the general recommendations for the use of endovascular techniques in arterial trauma.

**Table II. General recommendations for use of endovascular techniques in arterial trauma<sup>2</sup>**

**Indications**

False aneurysm  
Arteriovenous fistula  
Branch vessel injury  
Arterial intimal flap

**Contraindications**

Long segmental arterial occlusion  
Insufficient proximal neck  
Complete arterial transection

**Relative contraindications**

Complex arteriovenous injury  
Covering of vertebral artery origin  
Associated nerve compression by adjacent false aneurysm

**Conclusion**

Despite the lack of systematic trials comparing endovascular techniques with the gold standard of open vascular surgical repair, endovascular management of arterial

trauma is now common practice. Durability of the device in a young patient remains a concern. Future studies will be necessary to confirm findings of improved survival and to characterise the long-term performance of endovascular repair. However, the benefits of the endovascular technology delineated will no doubt provide further justification for the widespread use of such minimally invasive techniques.

**Appendix A**

Monson classification of zones of the neck:

Zone 1 – suprasternal notch to 1 cm above the sternoclavicular joint.

Zone 2 – as above, to the angle of the mandible.

Zone 3 – above the angle of the mandible.

**Appendix B**

Definitions in context of this article:

Embolisation – deliberate occlusion of a blood vessel using coils, gel foam or balloons.

Covered stent grafts – metal stents with a PTFE or Dacron lining.

Bare metal stents – no PTFE or Dacron lining.

Balloon occlusion – detachable balloons left within an injured artery, thus occluding the vessel.

Endoleak – blood leaking around a fully deployed covered stent resulting in either an ongoing bleed from the arterial injury or a persistent filling of a false aneurysm.

**References**

1. Reuben B, Whitten M, Sarfati M, *et al.* Increasing use of endovascular therapy in acute arterial injuries: Analysis of the National Trauma Data Bank. *J Vasc Surg* 2007; 26(6): 1222-1226.
2. Paruk N, Mulaudzi T, Pillay B, Robbs JV. Endovascular intervention in arterial trauma. VASSA 2008 Abstracts.
3. Robbs JV. Penetrating vascular injuries: principles of diagnosis and management. *Gefasschirurgie* 2002; 7: 195-201.
4. Duane TM, Parker F. Endovascular carotid stenting after trauma. *J Trauma* 2002; 52:149-153.
5. Du Toit DF, Leith JG, Strauss DC, *et al.* Endovascular management of traumatic cervicothoracic arteriovenous fistula. *Br J Surg* 2003; 90(12): 1516-1521.
6. Thomas GI, Anderson KN. The significance of anomalous vertebral-basilar artery communications in operations on the heart and great vessels. *Surgery* 1959; 46: 747-757.
7. Mwitpatayi BP, Jeffery P, Beningfield SJ, *et al.* Management of extracranial vertebral artery injuries. *Eur J Vasc Endovasc Surg* 2004; 27(2): 157-162.
8. Naidoo NM, Corr PD, Robbs JV, *et al.* Angiographic embolisation in arterial trauma. *Eur J Vasc Endovasc Surg* 2000; 19: 77-81.
9. McKinley AG, Abdool-Carrim ATO, Robbs JV. Management of proximal axillary and subclavian artery injuries. *Br J Surg* 2000; 87: 79-85.
10. Du Toit DF, Lambrechts AV, Stark H, *et al.* Long-term results of stent graft treatment of subclavian artery injuries: management of choice for stable patients. *J Vasc Surg* 2008; 47(4): 739-743.
11. Jamieson WRE, Janusz MT, Gudas VM, *et al.* Traumatic rupture of the thoracic aorta: third decade of experience. *Am J Surg* 2002; 183: 571-575.
12. Demetriades D, Velmahos GC, Scalea TM, *et al.* Diagnosis and treatment of blunt thoracic aortic injuries: changing perspectives. *J Trauma* 2008; 64(6): 1415-1419.

