

# Common parasitic infections in the HIV-infected patient

**The three most common parasites found in HIV-infected patients are those causing toxoplasmosis, malaria, and diarrhoea.**

GARY MAARTENS, MB ChB, MMed (Int Med), FCP (SA), DTM&H

Division of Clinical Pharmacology, Department of Medicine, University of Cape Town

Gary Maartens is an infectious diseases physician and clinical pharmacologist. His main research interest is the clinical features and treatment of HIV infection.

E-mail: Gary.Maartens@uct.ac.za

This article focuses on the three groups of disorders due to parasites that are commonly seen in HIV-infected patients in South Africa – parasites causing diarrhoea, toxoplasmosis and malaria. All of these parasites are unicellular organisms.

Several other parasites are important pathogens in HIV-infected patients in other geographical regions: visceral leishmaniasis (Mediterranean, East Africa and Brazil), strongyloides hyperinfection (many tropical areas), and Chaga's disease (Central and South America).

**The diarrhoea caused by these parasites is often severe and debilitating, causing dehydration, severe weight loss, and malabsorption.**

*Parasites causing diarrhoea: cryptosporidiosis, microsporidiosis and isosporiasis*

All 3 of these parasites present with diarrhoea in patients with CD4+ counts usually below 200 cells/μl. The diarrhoea originates in the small bowel, is chronic, and is non-inflammatory (in other words there is no blood or mucus macroscopically, and there are no pus cells microscopically). The diarrhoea caused by these parasites is often severe and debilitating, causing dehydration, severe weight loss, and malabsorption. Extra-intestinal manifestations of these parasites have been described, particularly with microsporidiosis. The commonest extra-intestinal manifestation is acalculous cholecystitis.

The prevalence of these parasites varies geographically. They are collectively very common in African AIDS patients. Microsporidiosis in particular is linked to unsafe drinking water. Microsporidiosis is relatively uncommon in urban South Africa, where cryptosporidiosis most commonly causes chronic diarrhoea, but was the commonest cause of diarrhoea in HIV-infected patients in Zimbabwe.

Making a specific diagnosis is important in order to give the correct therapy. At least two stool specimens should be sent for

staining for parasites. *Cryptosporidium parvum* and *Isospora belli* are relatively easily identified with simple stains (Figs 1 and 2), but excretion in the stools is often intermittent. Microsporidiosis is due to a number of related organisms, which have a unique internal coiled organelle (called the polar tubule, Fig. 3) that facilitates invasion. The commonest organism causing microsporidiosis is *Enterocytozoon bieneusi*. Microsporidiosis is difficult to diagnose on stool samples using a trichrome stain. Molecular diagnostic tests using nucleic acid amplification (usually by the polymerase chain reaction) are far more sensitive, but are not widely available. The diagnosis of microsporidiosis is often made on microscopy of small intestinal biopsies.

**Microsporidiosis is relatively uncommon in urban South Africa, where cryptosporidiosis most commonly causes chronic diarrhoea, but was the commonest cause of diarrhoea in HIV-infected patients in Zimbabwe.**

With the exception of isosporiasis, there are limited treatment options for these parasites. Isosporiasis responds well to co-trimoxazole treatment – the usual dose is 2 single-strength tablets 6 hourly for 10 days, but intravenous therapy is recommended for severe cases, who often have malabsorption. We have encountered a number of patients with isosporiasis who have failed to respond to co-trimoxazole, or only responded partially. These cases are difficult to manage. Ciprofloxacin is sometimes effective. Co-trimoxazole is effective prophylaxis against isosporiasis. There is no effective specific therapy for cryptosporidiosis. Albendazole is effective against some species causing microsporidiosis, but is ineffective against the commonest cause, *Enterocytozoon bieneusi*. Fortunately, almost all AIDS patients with cryptosporidiosis and microsporidiosis respond well to antiretroviral therapy. Antimotility agents are helpful in milder cases. As with all causes of diarrhoea, fluid and electrolyte replacement is essential. Nutritional support is mandatory for all patients with wasting and diarrhoea from these parasites.

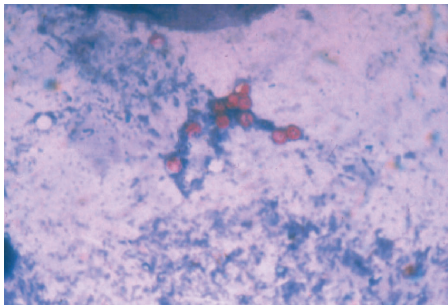


Fig. 1. Modified acid-fast stain of stool specimen showing oocysts of *Cryptosporidium parvum*.

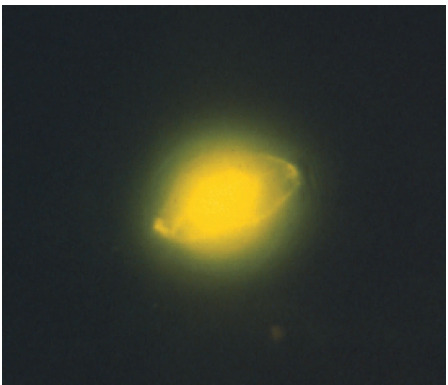


Fig. 2. Auramine stain of stool specimen showing oocyst of *Isospora belli*.

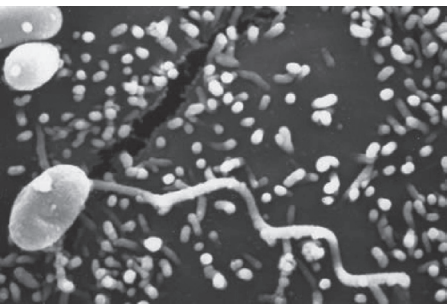


Fig. 3. Scanning electron micrograph of a microsporidian spore with an extruded polar tubule inserted into a eukaryotic cell. The spore injects the infective sporoplasms through its polar tubule. (Source: CDC parasite images library. [http://www.dpd.cdc.gov/DPDx/HTML/Image-Library/M-R/Microsporidiosis/body\\_Microsporidiosis\\_il5.htm](http://www.dpd.cdc.gov/DPDx/HTML/Image-Library/M-R/Microsporidiosis/body_Microsporidiosis_il5.htm))

## Toxoplasmosis

In immunocompromised patients toxoplasmosis is a recrudescence of prior infection with *Toxoplasma gondii*. Serological tests therefore show evidence of previous infection, with positive IgG rather than IgM antibodies against *T. gondii*. A negative serological test for *T. gondii* virtually rules out toxoplasmosis, but a positive test is not very specific, as about 30 - 40% of adult South Africans are seropositive. The classic clinical presentation of toxoplasmosis in AIDS patients is with cerebral mass lesions (Fig. 4). Toxoplasmosis is the commonest cause of intracranial mass lesions in South African HIV-infected patients. Pulmonary toxoplasmosis presents with nonspecific bilateral patchy infiltrates, but is seldom

## Toxoplasmosis is the commonest cause of intracranial mass lesions in South African HIV-infected patients.

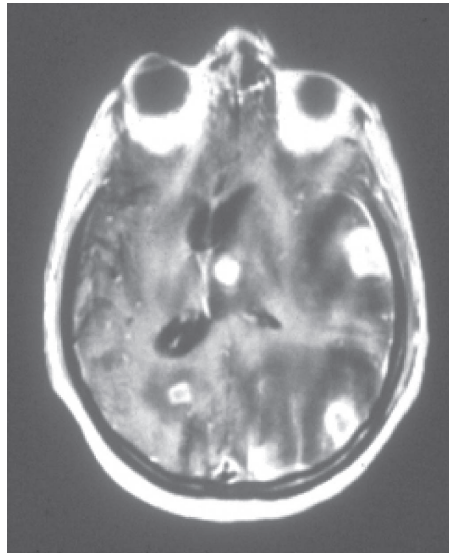


Fig. 4. MRI scan of the brain showing multiple mass lesions with surrounding oedema and midline shift. The mass lesions show ring enhancement with contrast. Typical appearance of cerebral toxoplasmosis.

diagnosed. The CD4+ count in patients with toxoplasmosis is usually <100 cells/ $\mu$ l; counts above 200 cells/ $\mu$ l virtually rule out cerebral toxoplasmosis.

Co-trimoxazole is effective treatment for toxoplasmosis. The recommended regimen is 4 single-strength co-trimoxazole tablets 12 hourly for 4 weeks, followed by 2 single-strength tablets for 12 weeks. Clinical response to co-trimoxazole is diagnostic of toxoplasmosis, and occurs after 5 - 10 days, with MRI/CT scans improving within 2 - 4 weeks. Co-trimoxazole is effective prophylaxis against toxoplasmosis. There are no controlled data on the role of adjunctive glucocorticoids in cerebral toxoplasmosis, but many clinicians routinely prescribe them as the MRI/CT scan appearance is usually alarming. However, it is better to avoid glucocorticoids if possible, as this will reduce cerebral oedema around the mass lesions irrespective of the cause, making the diagnosis difficult. I reserve adjunctive glucocorticoids for patients with life-threatening lesions, e.g. those in the brain stem.

**Adults with immunity to malaria experience more frequent symptomatic episodes and higher rates of parasitaemia, particularly as their CD4 counts drop.**

## Malaria

Initial reports failed to find important associations between HIV and malaria, but subsequent studies have shown interactions that are significant. In South Africa malaria is only present seasonally in the north-eastern parts of the country. Therefore immunity to malaria, which is partial and only occurs in adults in areas experiencing year-round malaria, does not develop in South Africa. However, HIV-infected patients from many of our neighbouring countries will have partial immunity.

Adults with immunity to malaria experience more frequent symptomatic episodes and higher rates of parasitaemia, particularly as their CD4 counts drop. Adults without immunity experience a higher risk of severe malaria and death from malaria. Because of the size of the HIV pandemic and the malaria burden in southern Africa, it is estimated that there has been at least a 50% increase in malaria deaths in the region due to HIV infection (Fig. 5).

Combination artemisinin-based therapy (in South Africa artemether-lumefantrine is the only preparation available) is the current standard of care for treating *Plasmodium falciparum* malaria in Africa. This is equally effective in patients with and without HIV co-infection. On theoretical grounds there are likely to be drug interactions between certain antiretroviral drugs and artemether-lumefantrine, but the magnitude of the interactions and their clinical relevance remains to be determined. Co-trimoxazole prophylaxis has been shown to reduce the incidence of malaria.

### Recommended reading

- Cohen C. Prevention and treatment of malaria in HIV-infected patients. *CME* 2008; 26(6): 280-282.
- Gumbo T, Sarbah S, Gangaidzo IT, *et al*. Intestinal parasites in patients with diarrhea and human immunodeficiency virus infection in Zimbabwe. *AIDS* 1999; 13(7): 819-821.
- Hunter PR, Nichols G. Epidemiology and clinical features of *Cryptosporidium* infection in immunocompromised patients. *Clin Microbiol Rev* 2002; 15: 145-154.

## HIV patients

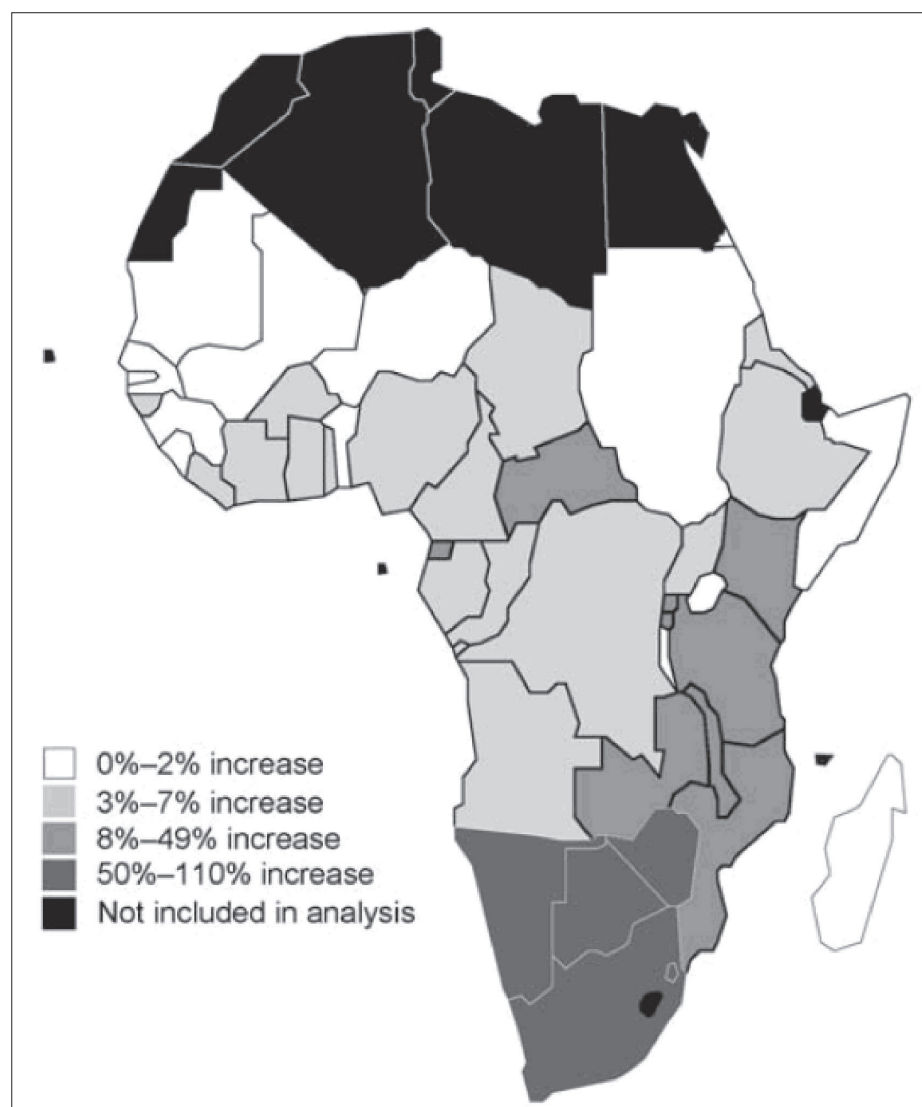


Fig. 5. Estimated increases in malaria deaths attributable to HIV infection in Africa, 2004. (From: Korenromp EL, Williams BG, de Vlas SJ, et al. *Malaria attributable to the HIV-1 epidemic, sub-Saharan Africa. Emerg Infect Dis* 2005; 11(9): 1410-1419.)

Korenromp EL, Williams BG, de Vlas SJ, et al. Malaria attributable to the HIV-1 epidemic, sub-Saharan Africa. *Emerg Infect Dis* 2005; 11(9): 1410-1419.

Recommendations of the National Institutes of Health (NIH), the Centers for Disease Control and Prevention (CDC), and the HIV Medicine Association of the Infectious Diseases Society of America (HIVMA/IDSA). Guidelines for Prevention and Treatment of Opportunistic Infections in HIV-Infected Adults and Adolescents, June 18, 2008. [http://aidsinfo.nih.gov/contentfiles/Adult\\_OI.pdf](http://aidsinfo.nih.gov/contentfiles/Adult_OI.pdf)

Wilson D, Bekker L-G, Cotton M, Meyers T, Venter F, Maartens G. *Handbook of HIV Medicine*. 2nd ed. Cape Town: Oxford University Press Southern Africa, 2008.

### *In a nutshell*

- Cryptosporidiosis, isosporiasis and microsporidiosis collectively cause a considerable amount of chronic diarrhoea in HIV infection.
- Isosporiasis is effectively treated and prevented with co-trimoxazole.
- There is no specific therapy for either cryptosporidiosis or microsporidiosis, but immune restoration from combination antiretroviral therapy is almost always successful.
- Toxoplasmosis is the commonest cause of intracranial mass lesions in AIDS patients.
- Treatment response to co-trimoxazole is diagnostic of toxoplasmosis.
- Malaria deaths have dramatically increased in southern Africa as a result of the HIV pandemic.

## *Single suture*

### ***Fat aids memory***

Next time you are cramming for an exam, eat a fatty meal after you have finished studying. Research on rats shows that eating a certain type of fat produces a hormone that helps the brain cement short-term memories into long-term ones.

Daniele Piomelli and colleagues at the University of California trained rats to avoid an area that gave them a shock and to find a platform in a pool of water. Immediately after the training period they injected some of the rats with oleoylethanolamide (OEA) – a chemical produced in the small intestine of vertebrates and which creates a sense of fullness after eating fat. When the rats were re-tested one or two days later, the ones that received OEA performed better, suggesting that they had stronger memories of their training.

Further experiments with the rats showed that OEA activates the same areas of the brain that mediate the formation of emotionally charged memories in humans – these are more vivid than typical memories.

OEA is only produced after eating the unsaturated fat – oleic acid – so a cheesburger won't do it!

*New Scientist* 2009; 2 May.