

Aortic stentgrafts and endovascular abdominal aortic aneurysm repair

Techniques using endovascular repair of major vascular pathology are advancing rapidly.

N G NAIDOO, MB ChB, FCS (SA)

Head, Vascular Surgery, Department of Surgery, Groote Schuur Hospital, Cape Town

Nadraj Naidoo graduated from the University of Natal, Durban. He did his surgical training at King Edward VIII Hospital and post-fellowship training in renal transplantation and vascular surgery in Durban. His interests include HIV-associated vasculopathy, Takayasu's disease and aorto-iliac disease.

STEVE BENINGFIELD, MB ChB, FFRad (D) SA

Professor, Radiology Division, Groote Schuur Hospital and University of Cape Town

Steve Beningfield is a graduate from the University of Cape Town. He joined the Department of Radiology at Groote Schuur Hospital in 1983 and obtained the FFRad (D) SA in 1986. His special interests include interventional radiology, particularly hepatobiliary and vascular.

Endovascular treatment of aortic pathologies has obvious appeal: avoiding large surgical incisions, reduced blood loss, eliminating the need for cardiac bypass in complex aortic repairs, reduced intensive care unit (ICU) stay, less perioperative morbidity, earlier ambulation and shorter hospital stay. The last 10 - 15 years can be considered as heralding the 'endovascular revolution', and at the forefront of this evolving stent/stentgraft technology was endovascular abdominal aortic aneurysm repair (EVAR).

Since the first descriptions by Balko and the initial clinical experience of Parodi in the early 1990s, stentgraft ('endograft') repair of abdominal aortic aneurysms (AAA) has evolved through irrational enthusiasm, followed by cynicism ('endoseptism') for a new technology, to being currently the widely accepted alternative treatment option for AAA repair. Originally conceived as a less invasive alternative to open repair (OR) of AAA in patients with significant medical co-morbidities, EVAR has also been used to treat conventional ('good') risk patients with AAA, despite the lack of proof of long-term efficacy and durability compared with the current gold standard of OR.

Currently, on average over half (range 20 - 80%) of AAAs are being treated using endovascular techniques worldwide. Evolving stentgraft technology and numerous reports in the last decade have shifted the focus from device safety and efficacy to proof of long-term durability, together with expanding applicability and indications. Despite a 2.5-fold reduction in 30-day mortality rate, EVAR is still plagued by a 3-fold risk of reintervention, 30% greater overall cost and similar overall mortality rates compared with OR.

Aortic stentgrafts: materials and configurations

Aortic stentgrafts are available in various configurations: tube stentgrafts, tapered stentgrafts (aorto-uniiliac), bifurcated stentgrafts ('Y' or trouser graft), fenestrated stentgrafts (with a scallop for the superior mesenteric artery and two reinforced fenestrations for renal artery stents), and branched stentgrafts (with side-arm/s for additional endografting to the mesenteric, renal and supra-aortic vessels) (Fig. 1).

First-generation aortic stentgrafts were unsupported tube grafts, with initially only proximal and later additional distal fixation




Fig. 1. Branched stentgraft showing a scallop (thin black arrow), fenestration (thick black arrow) and side-arm (red arrow). (Muhs BE, et al. J Vasc Surg 2006; 44: 9-15.)

stents. Currently these are limited for use only in saccular or para-anastomotic AAAs (following previous aorto-iliac surgery), and other rare indications. Thoracic stentgrafts (in tube configuration) are available in bigger diameters and in different lengths.

Aorto-uniiliac stentgrafts require a contralateral common iliac 'occluder' cuff and a femoro-femoral crossover bypass graft to preserve flow to the contralateral limb. Current indications include repair of ruptured AAA and associated iliac disease.

The current preferred configuration for EVAR is a bifurcated stentgraft. These are produced either as complete single units ('one-piece' or 'uni-body' device) (Fig. 2) or, more commonly, as a modular device (Fig. 3), consisting of two components (a main body with contiguous ipsilateral iliac limb and contralateral iliac

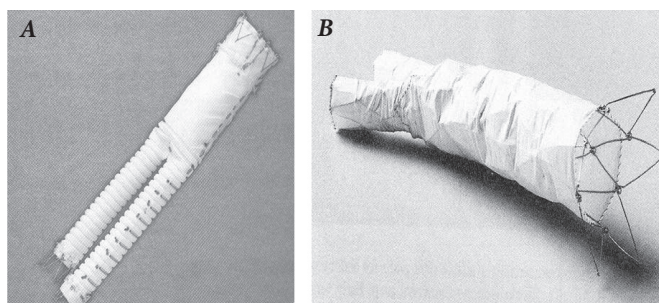


Fig. 2. Uni-body 'one-piece' stentgrafts. A= Ancure, B= Enlogix Powerlink devices.¹

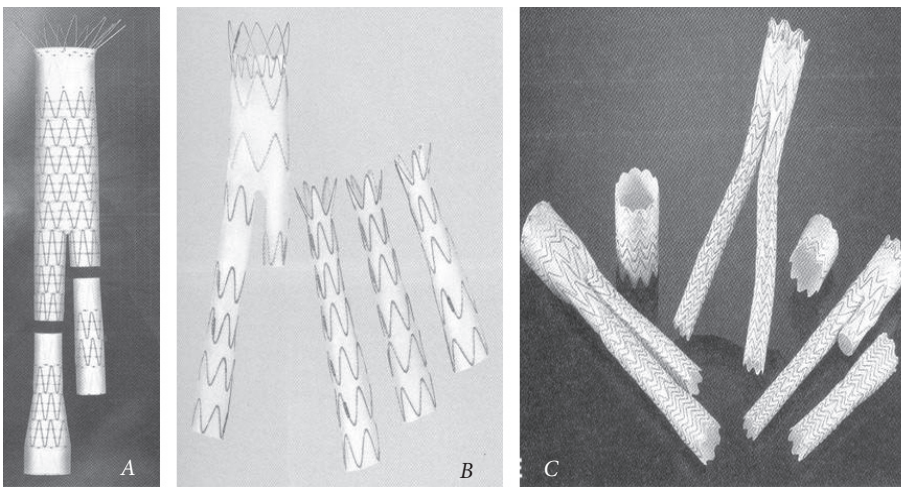


Fig. 3. Modular stentgrafts. A = Zenith, B = Talent, C = Excluder devices.¹

extension limb), or three components (a main body with separate ipsilateral and contralateral iliac extension limbs). The aortic component may be extended proximally with an aortic extension cuff, if required.

The graft material consists of polyester fabric or expanded polytetrafluoroethylene (e-PTFE), with most current devices supported throughout by a metal skeleton (endoskeleton, exoskeleton or interwoven). The metals used are stainless steel, 'Elgiloy' (nickel, cobalt, and chromium super-alloy) or, more commonly, nitinol (nickel-titanium alloy).

Stentgraft fixation ('seal'/'landing' zones)

Aortic fixation of the stentgraft may be infrarenal (relying on radial compression

with or without hooks or barbs attached to the proximal covered stent), or suprarenal with uncovered metal stent struts that maintain perfusion of the renal arteries, while the infrarenal covered component provides the seal.

Distally, a seal requires normal common iliac arteries. Associated iliac aneurysms require an external iliac artery landing zone (after coil embolisation or flared stentgraft occlusion of the ipsilateral internal iliac artery to prevent backflow). Other options to permit use of aneurysmal or occlusive iliac segments include: use of an iliac conduit (10 mm graft for access via an extraperitoneal approach), internal iliac to external iliac artery bypass grafting, iliac bifurcated stentgrafts, or an iliac occluder cuff with a femoro-femoral crossover bypass graft).

Table I. Prerequisites for successful EVAR

- Successful stentgraft delivery and deployment
- Adequate stentgraft fixation in normal arterial segments proximal and distal to an AAA (aortic and iliac 'seal' or landing zone)
- Depressurisation of the aneurysmal sac with no type 1 or type 3 endoleaks
- Stentgraft patency without significant twisting, kinking, migration, occlusion or graft sepsis

Table II. Anatomical requirements for abdominal aortic stentgrafting

- Infrarenal aortic neck length ≥ 20 mm (for infrarenal fixation) or 10 - 15 mm (for suprarenal fixation)
- Infrarenal aortic neck diameter ≤ 28 mm, with no more than 1 - 2 mm thrombus lining and < 3 mm diameter discrepancy at any point in the neck
- Aortic neck angulation (junction between the aortic neck and the aneurysm) < 60 degrees (ideally < 40 degrees)
- External iliac diameter ≥ 7 mm (with extensively calcified vessels) or ≥ 6 mm (with non-calcified vessels)
- Iliac vessels without severe tortuosity, significant aneurysmal or occlusive disease

EVAR: principles of repair

Successful stentgraft exclusion of an AAA requires certain criteria to be fulfilled (Table I).

Successful stentgraft attachment and aneurysm exclusion requires a thorough anatomical evaluation and patient selection (Table II).

Peri-procedural imaging and technique

Multi-detector CT angiography (MDCTA) is a good preprocedural imaging tool, with various 2-D and 3-D reformatting techniques allowing measurements including centre lumen line measurements for EVAR (Fig. 4).

Calibrating angiography, transoesophageal echo and intravascular ultrasound (IVUS) are useful adjuncts only for thoracic aortic pathology. The stentgraft should generally be oversized by 15 - 20% (10 - 15% for connective tissue disorders, aortic dissections, etc.).

EVAR is performed with local, regional (epidural) or general anaesthesia (better outcomes associated with local anaesthetic), and usually requires two small groin incisions to expose the femoral arteries. Fluoroscopy with C-arm image-intensifiers and angiography with calibrated pigtail catheters ensure precise infrarenal deployment, graft length measurement, modular 'docking' (with sufficient overlap of the components) and distal fixation of the devices (Fig. 5).

The devices are delivered and deployed over stiff guidewires. Fixation of the stentgraft in the seal zones is aided by use of a large diameter compliant ('moulding') balloon.

Post-procedural surveillance imaging, at 1, 6 and 12 months and thereafter annually, is mandatory and consists of Duplex U/S, MDCTA (or MR angiography) and plain X-rays. Imaging aims to detect changes in sac diameter and volume, endoleaks, stentgraft migration, etc. (Fig. 6).

Complications of EVAR

Endoleaks

An endoleak is defined as persistent blood flow or pressure within the sac on imaging (Table III).

Type 1 endoleaks may be treated with an aortic extension cuff. Type 2 endoleaks may be treated with coil embolisation or

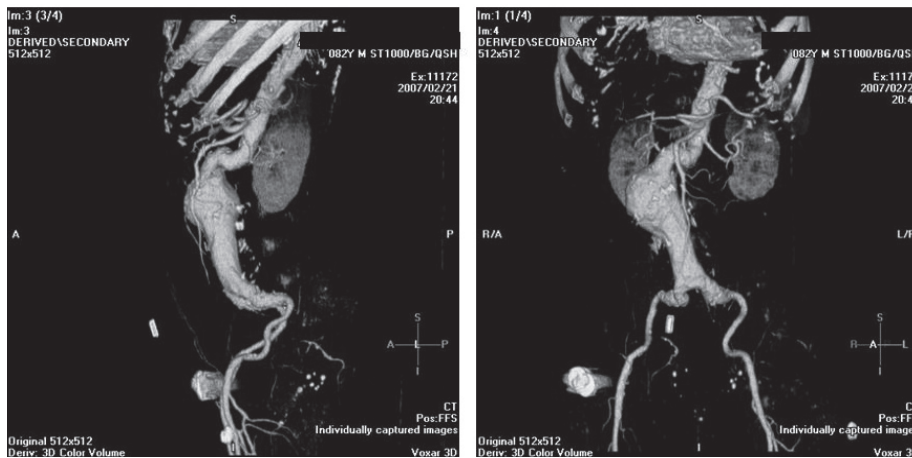


Fig. 4. 3-D display (MDCTA) in 2 projections showing severe aortic neck angulation unsuitable for EVAR.

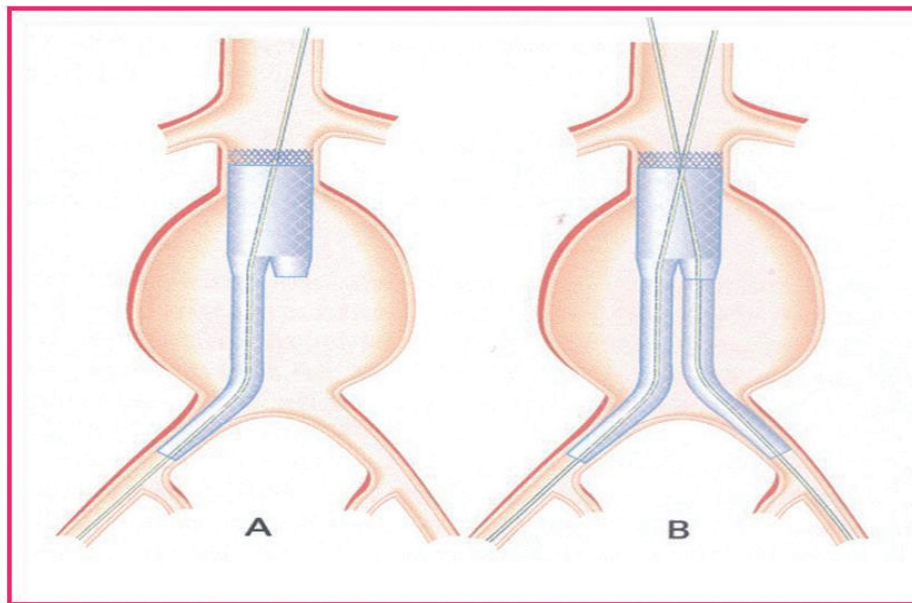


Fig. 5. Graphic representation of a modular stentgraft deployment. (Blum U, et al. N Engl J Med 2007; 336: 13 - 20.)

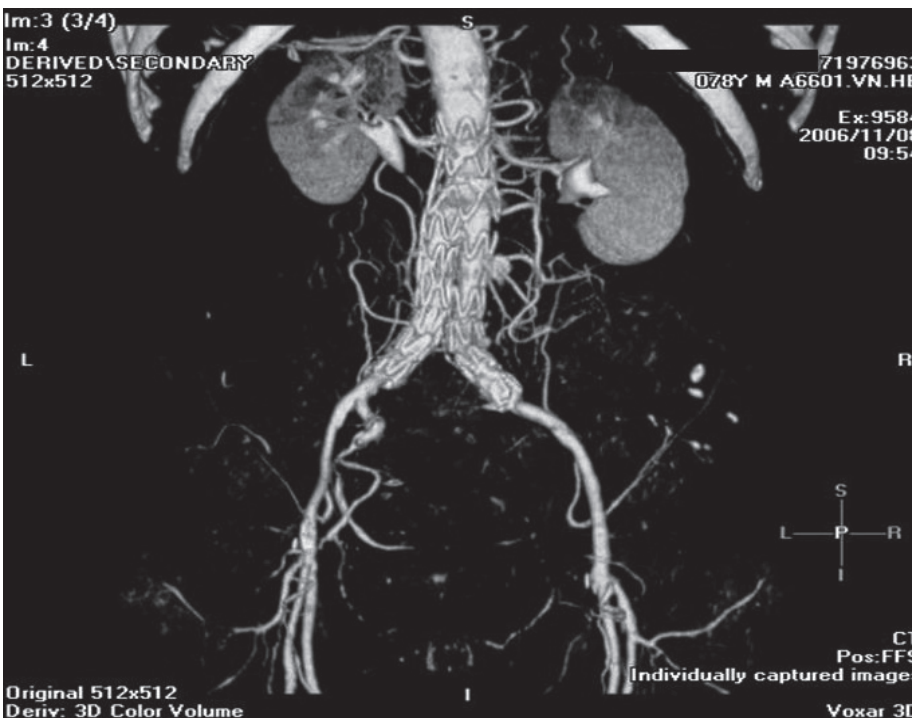

Fig. 6. Post-procedural MDCTA of an abdominal aortic stentgraft (post EVAR).

Table III. A simple classification of endoleaks

- Type 1: inadequate proximal or distal seal
- Type 2: patient side branch (intercostals, lumbar, accessory renal, inferior mesenteric arteries, etc.)
- Type 3: modular disconnection or fabric tear
- Type 4: increased graft porosity
- Type 5: indeterminate (endotension)

laparoscopic clip ligation of offending lumbar or inferior mesenteric arteries. Type 3 endoleaks may be treated with an additional stentgraft. Delayed type 4 endoleak has been linked to increased porosity associated with e-PTFE stentgrafts, namely Excluder ('sac hygroma').

The Eurostar registry revealed primary endoleak rates of 16% (43% type 1, 35% type 2, 7% type 3, 8% type 4 and 5% type 5). A total of 75% of endoleaks resolved after a month, and 16% of patients developed a new (secondary) endoleak after a month.²

An endoleak is suspected if there is sac expansion of over 5 mm or sac volume increase over 5% on imaging. Type 1 and type 3 endoleaks should be treated expeditiously. Type 2 endoleaks unassociated with sac expansion can be monitored by more frequent imaging.

A recent systematic review of 163 studies showed a pooled estimate of 10.5% for type 1 endoleaks and 13.7% for type 2, 3 and 4 endoleaks combined (annual incidence of 10.2%).³

Stentgraft migration

This is defined as a greater than 5 mm change in stentgraft position. The incidence is 2 - 2.9%. Higher rates are associated with oversizing (by over 20%), with infrarenal fixation (10.9%, v. 2.1% for suprarenal fixation) and aortic neck angulation of over 60 degrees.⁴

Graft limb occlusion

The overall incidence was approximately 2.8% (2.7% at 1 year, 4.1% at 2 years and 5.5% at 3 years)⁴ and was associated with older generation unprotected stentgrafts. Graft limb kinking was more likely with distal aortic diameters under 16 mm and 'bail-out' stenting was invariably required.

Stentgraft kinking

The incidence in the Eurostar registry, a large multinational European database formed in 1996, was 3.7%. Patients at risk were women with angulated aortic necks treated by less experienced teams. Interestingly, there was no relationship between decrease in aneurysm diameter and stentgraft kinking.⁵

Stentgraft fracture

This is usually associated with severe aortic neck angulation.

Aneurysm rupture

The cumulative risk of rupture is approximately 1 - 2% per annum with a resultant operative mortality of 40 - 50%. Significant risk factors for rupture are type 1 endoleak, type 3 endoleak, stentgraft migration and post-procedure stentgraft kinking.⁶

The evidence for EVAR

The EVAR I study compared EVAR and OR in good-risk patients aged over 60 years, with AAAs over 5.5 cm. The EVAR 30-day mortality was approximately 1.7% v. 4.7% for OR, $p = 0.009$. At 12 months there was negligible difference in the health-related quality of life between EVAR and OR groups. At 4 years, the all-cause mortality was similar in both groups (28%), although the aneurysm-related mortality was significantly better for EVAR (4% v. 7%, $p = 0.04$). At 4 years the mean hospital costs were higher with EVAR, and the reintervention rate was also higher with EVAR.^{7,8}

The DREAM trial had similar 30-day mortality results in favour of EVAR. At 2 years, however, there was no difference in the all-cause and aneurysm-related mortality between the two groups.^{9,10}

The EVAR II study compared EVAR with no intervention in patients considered unfit for OR. The 30-day mortality in the EVAR group was 9%. Mortality at 4 years was 64% (similar for both groups). There was no difference in the all-cause and aneurysm-related mortality rates between the two groups.¹¹

A recent analysis of 5 USA multicentre device trials showed no overall survival advantage for EVAR compared with OR in high-risk patients at 4 years (55% v. 66%). There was also no difference in the aneurysm-related mortality rate.¹²

Much of the data and experience with stentgrafts come from the Eurostar registry. Successful stentgraft deployment was achieved in 97%; the 30-day mortality was 2.9% (3.4% in the initial experience).

The cumulative annual risk of conversion to OR was 2.1% (1.9% at 30 days and 11.7% at 4 years); contributing significant risk factors were type 1, 2 and 3 endoleaks, stentgraft migration and graft kinking.⁶ The cumulative risk for a secondary reintervention (usually endovascular) was 12% at 1 year, 24% at 2 years, and 35% at 3 years.⁴

Concerns of renal impairment with the use of suprarenal stent fixation have not materialised. However, patients with renal impairment undergoing EVAR have a higher mortality rate compared with patients with normal renal function.

The Eurostar registry has certainly informed and influenced the evolution of stentgraft technology, device-related complications having decreased from 21.7% to 7.3% between 1994 and 2000. Current devices are associated with fewer secondary interventions, less conversions to OR and less aneurysm-related mortality.

A recent US study showed a better anatomical profile (suitability) for EVAR at 5 years, with improved survival and freedom from rupture for patients with small AAAs (< 5.0 cm), compared with medium and large aneurysms (> 5.5 cm).¹³ However, current concerns with long-term durability, the results of the US and UK small AAA studies showing no benefit of OR compared with imaging surveillance alone,^{14,15} and lack of significant differences in secondary interventions, endoleaks and stentgraft migration rates between small and large AAAs preclude EVAR for small AAA in current practice.

In a recent systematic EVAR review, the 30-day mortality rates, annual rupture rates (0.6%), and total number of endoleaks all fell significantly with time. The results of new randomised controlled trials

(‘ACE’ and ‘OVER’ trials) utilising current state-of-the-art stentgrafts are awaited.

The current consensus therefore advocates OR in young, fit patients (even despite suitable anatomy for EVAR) and EVAR in older, conventional (‘good and intermediate’) risk patients with suitable anatomy. Patients with significant medical co-morbidities should be optimised prior to EVAR. EVAR in a patient with a life expectancy of < 1 year cannot be justified on current evidence.

Endovascular repair of emergent or ruptured AAA (e-EVAR)

All stable patients presenting with suspected ruptured AAA should have a MDCTA to assess suitability for EVAR. Commercial stentgrafts of various diameters, lengths and configurations need to be readily available. A recent study showed that although 45.8% of patients with ruptured AAA had suitable anatomy for e-EVAR, the applicability rate was low.¹⁶

A recent Dutch study comparing e-EVAR with OR for ruptured AAA showed significant differences regarding mean operative times, mean blood losses, mean ICU stays and mean hospital stays in favour of e-EVAR. However, there were no differences in the 30-day mortality rates (31% in both groups), systemic complications or early and late reintervention rates.¹⁷

Expanded indications for aortic stentgrafting

- Juxtarenal, pararenal and suprarenal AAA (using fenestrated and branched stentgrafts).

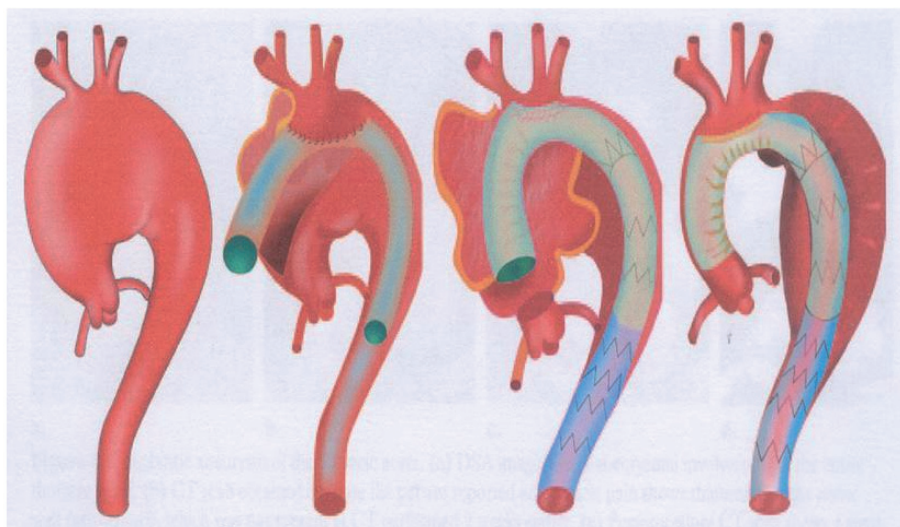


Fig. 7. Complex aortic arch aneurysm repair using open surgical techniques with stentgrafting of the ‘elephant trunk’ (hybrid procedure). (Garzon G, et al. Radiographics 2005; 25: S229-S244.)

Endovascular repair

- Thoracic endovascular aortic aneurysm repair (TEVAR).
- Hybrid procedures (combined surgery and stentgrafting) for repair of thoraco-abdominal aortic aneurysms (TAAA).
- Hybrid procedures for repair of aortic arch aneurysms (including the 'stented elephant-trunk' technique) (Fig. 7).
- Acute and chronic type II aortic dissections.
- Treatment of penetrating aortic ulcers.
- Traumatic thoracic aortic rupture
- Thoracic aortic pseudo-aneurysm.

References

1. Rutherford RB. *Vascular Surgery*, 6th ed. Philadelphia: Elsevier Saunders, 2005.
2. Buth J, Laheij RJF. Early complications and endoleaks after endovascular abdominal aortic aneurysm repair: Report of a multicenter study. *J Vasc Surg* 2000; 31: 134-146.
3. Franks SC, Sutton AJ, Brown MJ, Sayers RD. Systematic review and meta-analysis of 12 years of endovascular abdominal aortic aneurysm repair. *Eur J Vasc Endovasc Surg* 2007; 33: 154-171.
4. Towne JB. Endovascular treatment of abdominal aortic aneurysm. *Am J Surg* 2005; 189: 140-149.
5. Fransen GA, Desgranges P, Laheij RJ, et al. Frequency, predictive factors, and consequences of stentgraft kinking following endovascular AAA repair. *J Endovascular Ther* 2003; 10(5): 913-918.
6. Vallabhaneni SR, Harris PL. Lessons learnt from the Eurostar registry on endovascular repair of abdominal aortic aneurysm. *Eur J Rad* 2001; 39: 34-41.
7. Greenhalgh RM, Brown LC, Epstein D, et al. Comparison of endovascular aneurysm repair with open repair in patients with abdominal aortic aneurysm (EVAR trial 1), 30-day mortality results. *Lancet* 2004; 364: 843-848.
8. Endovascular aneurysm repair versus open repair in patients with abdominal aortic aneurysm (EVAR trial 1): randomized controlled trial. *Lancet* 2005; 365: 2179-2186.
9. Endovascular aneurysm repair and outcome in patients unfit for open repair of abdominal aortic aneurysm (EVAR trial 2): randomized controlled trial. *Lancet* 2005; 365: 2187-2192.
10. Prinssen M, Verhoeven ELG, Buth J, et al. A randomized trial comparing conventional and endovascular repair of abdominal aortic aneurysms. *N Engl J Med* 2004; 351: 1607-1618.
11. Blankensteijn JD, de Jong SECA, Prinssen M van der Ham AC, Buth J, Dream Trial Group. Two year outcomes after conventional or endovascular repair of abdominal aortic aneurysms. *N Engl J Med* 2005; 352: 2398-2405.
12. Sicard GA, Zwolak RM, Sidawy AN, White RA, Siami FS. Endovascular abdominal aortic aneurysm repair: Long-term outcome measures in patients at high risk for open surgery. *J Vasc Surg* 2006; 44: 229-236.
13. Zarins CK, Crabtree T, Bloch DA, Arko FR, Ouriel K, White RA. Endovascular aneurysm repair at 5 years: does aneurysm diameter predict outcome? *J Vasc Surg* 2006; 44: 920-930.
14. Lederle FA, Samuel EW, Jonhson GR, et al. Immediate repair compared with surveillance of small abdominal aortic aneurysms. *N Engl J Med* 2002; 346: 1437-1444.
15. The UK Small Aneurysm trialists: Long-term outcome of immediate repair compared with surveillance of small abdominal aortic aneurysms. *N Engl J Med* 2002; 346: 1445-1452.
16. Hoornweg LL, Wisselink W, Vahl A, Balm R. The Amsterdam Acute Aneurysm trial: suitability and application rate for endovascular repair of ruptured abdominal aortic aneurysms. *Eur J Vasc Endovasc Surg* 2007; 20: 1-5.
17. Visser JJ, Bosch JL, Hunink MGM, van Dijk CK, Hendriks JM, Poldermans D. Endovascular repair versus open surgery in patients with ruptured abdominal aortic aneurysms: clinical outcomes with 1 year follow-up. *J Vasc Surg* 2006; 44: 1148-1155.

In a nutshell

- Aortic stentgrafts have expanded the treatment options for repair of abdominal aortic aneurysms.
- Surgery and EVAR are complementary, not competitive, treatment strategies.
- Current stentgraft configuration for EVAR involves a modular, bifurcated, design. Thoracic stentgrafts employ a tube configuration, with current limitations involving obtaining an adequate seal in the aortic arch and bulky, rigid, delivery devices.
- Current limitations to EVAR include hostile proximal aortic neck anatomy, difficult iliac access, and small calibre vessels in females.
- EVAR in appropriate patients has excellent early and improving intermediate results. In experienced hands it is safe and effective.
- The magnitude of surgery may be reduced by the adjunctive use of aortic stentgrafts ('hybrid' procedures for complex aortic aneurysm repairs).
- EVAR, despite being minimally invasive, is not a lesser procedure. The magnitude of procedure-related complications rivals that associated with open surgery.
- In the long term, EVAR is more expensive than surgery.
- The long-term durability of aortic stentgrafts has yet to be defined.
- EVAR is less invasive, but patients require serial long-term follow-up and imaging surveillance, with increased probability of secondary reinterventions (approximately 40% are free of reinterventions at 5 years). This needs to be discussed with patients.