

Advances in trauma surgery

Trauma surgery has advanced as a specialisation in the past few years.

ANDREW NICOL, MB ChB, FCS (SA)

Trauma Surgeon and Head, Trauma Centre, Grootte Schuur Hospital and University of Cape Town

Andrew Nicol is an associate professor and trauma surgeon at Grootte Schuur Hospital and the University of Cape Town. His particular areas of interest are trauma systems, penetrating cardiac trauma and liver injuries.

PRADEEP NAVSARIA, MB ChB, MMed, FCS (SA)

Trauma Surgeon and Deputy Head, Trauma Centre, Grootte Schuur Hospital and University of Cape Town

Pradeep Navsaria is a senior lecturer and trauma surgeon at Grootte Schuur Hospital and the University of Cape Town. His current fields of interest consist of the non-operative management of abdominal gunshot wounds and laparoscopy in extraperitoneal rectal injuries.

There have been numerous advances in the field of trauma surgery over the past few years. The establishment of trauma centres has allowed for the regionalisation of trauma care and contributed significantly to a reduction in trauma mortality. The Statscan has reduced the time taken to obtain the X-rays required in resuscitation. Damage control surgery has dramatically improved the survival of severely injured patients undergoing emergency surgery and there has been a continuation of a trend towards the selective, conservative management of major trauma.

Trauma systems

A significant advance in the management of the severely injured patient has been the development of trauma care systems, initially in Europe and the USA in the 1970s and then throughout the world. This system is an organised approach to the acutely injured patient that provides personnel, facilities, and equipment for optimum care on an emergency basis. It is well accepted that the preventable death rate from trauma approximates 30% without a trauma care system and this can be reduced to 5% with full trauma system implementation.

A trauma care system deals with the prevention of trauma, the emergency and subsequent hospital treatment and rehabilitation. The requirements comprise an efficient pre-hospital service with field triage guidelines. The injured patient must be taken to the most appropriate facility according to the severity of the injury. Studies in the USA have shown remarkable improvement in survival when seriously injured patients bypass the nearest local hospital to reach a regional trauma centre.¹ Such triaging of the trauma patients has also been proven to be extremely cost effective.

A trauma centre constitutes the level 1 hospital in the system. Trauma surgeons are available as well as the back-up of specialist facilities. Approximately 20% of trauma patients will require the

services of the trauma centre. The smaller regional hospitals are divided into specific levels of care according to staffing and the availability of surgical/emergency services and they are graded from level 2 to 4 hospitals.

Also included in the system are speciality trauma centres for paediatrics, spinal cord injuries and a major burns unit. A rehabilitation centre is also required for further long-term management (see Fig. 1).

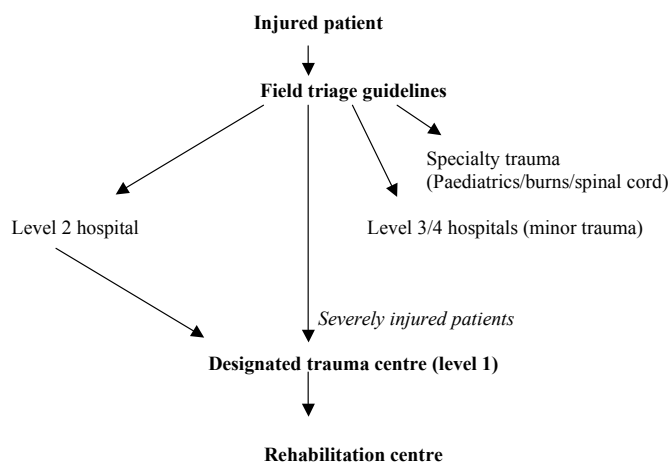


Fig. 1. The functioning of a trauma care system.

The Statscan

The Statscan is a new digital radiography system designed for trauma radiology and developed as a collaborative effort between Lodox (Pty) and the University of Cape Town (Fig. 2). It was originally designed by the De Beers mining corporation to produce a full-body ultra-low dose X-ray in order to detect smuggled diamonds in humans. This technology has been enhanced and now the Statscan can produce a whole-body digital X-ray in under 13 seconds with a mean radiation dose typically only 6% that of a conventional X-ray.²

The system comprises an X-ray tube mounted on a C-arm, which emits a low-dose fan beam. An X-ray detector unit is situated on the other end of the C-arm comprising scintillator arrays linked

A significant advance in the management of the severely injured patient has been the development of trauma care systems.

The ability to rapidly obtain whole-body images that can be magnified to look at specific regions of the body with a clarity similar to conventional X-rays is a major advance in trauma radiology.

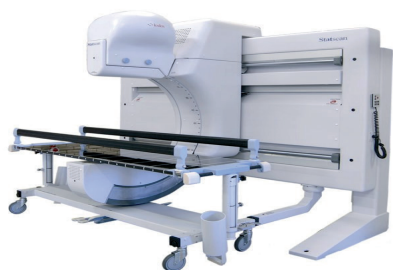

Fig. 2. The Statscan.

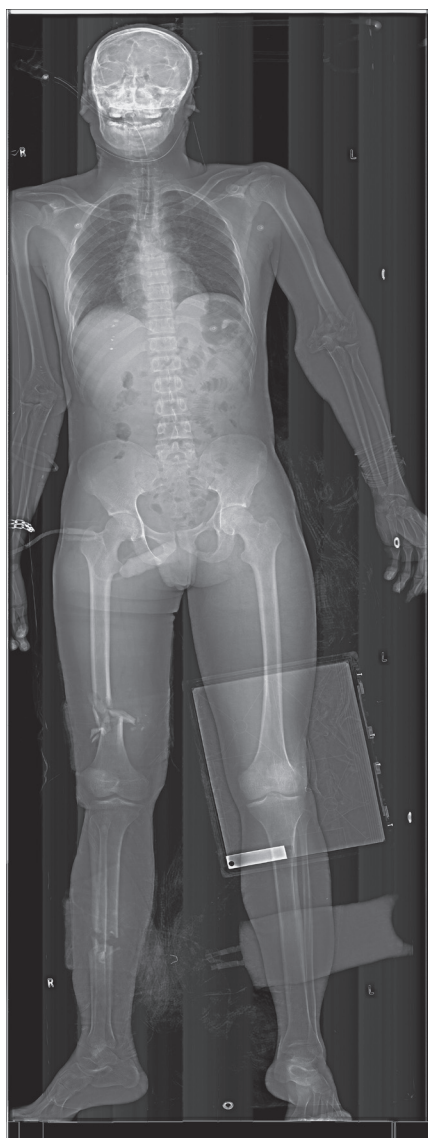


Fig. 3. A whole-body digital image produced by the Statscan.

to charge-coupled devices. An image is obtained by scanning the C-arm over the required anatomical portion of the patient while continually reading the output of the detectors. The C-arm travels at a rate of up to 14 cm per second and can be rotated to produce lateral views. The X-ray image is

then displayed on a computer-controlled operating and viewing system with standard DICOM 3 (digital imaging and communication in medicine 3) capability.

The ability to rapidly obtain whole-body images that can be magnified to look at specific regions of the body with a clarity similar to conventional X-rays is a major advance in trauma radiology. The low radiation dose allows for the system to be situated in the resuscitation room. One of the major rate-limiting steps in major polytrauma resuscitation in the past has been the acquisition of the all required X-rays. The Statscan has certainly resulted in a major reduction in the time taken to perform resuscitation.³

Head injury

The current indications for a CT scan of the head in the adult patient are: any patient with a Glasgow coma score of 14 or less, any focal neurological deficit, any localising signs (dilated pupil), severe headache or vomiting (more than 2 episodes) in the conscious patient, fractured skull on palpation or X-ray, clinically apparent base of skull fracture, penetrating eye injuries (30% will have intracranial extension), tangential gunshot wounds to the skull (10% will have a cerebral injury), penetrating skull trauma, a stab to the head with a loss of consciousness (slot fracture), seizures and the patient who is on warfarin therapy and has a head injury.

A more liberal policy for a CT scan of the head in injured children is required in the presence of a high-risk mechanism despite the presence of a normal neurological examination on initial screening. Sixteen per cent of children with significant head injuries will have a Glasgow coma score of 15 and no loss of consciousness.⁴

Cervical spine injuries

Conscious and asymptomatic

The cervical spine can be cleared clinically (without cervical spine X-rays) in the fully conscious patient provided there is no neck pain and the patient is not under the influence of drugs or alcohol.

Conscious and symptomatic

The standard 3 view plain X-rays are required consisting of a lateral cervical spine, anteroposterior (AP) and an open mouth view. If there are any abnormal or poorly visualised areas then a CT scan is indicated. If there are any abnormal findings on the neurological examination, magnetic resonance imaging (MRI) is indicated to identify a cord injury.

Unconscious and intubated

The incidence of an unstable spinal injury is around 10% in the intubated patient. The radiological evaluation will consist of a lateral cervical spine, an AP view and a CT scan of the occiput to the third cervical vertebra. An open mouth view is not accurate in the intubated patient. Spinal precautions should be continued even in the presence of a normal CT scan of the upper neck. If the patient is not expected to be fully conscious within 48 hours, then a CT of the whole cervical spine is required to exclude any cervical spine injury.

Surgical management of penetrating neck injuries

The patient presenting to the emergency room with massive bleeding from a penetrating neck injury requires haemostatic surgery. The really controversial issue, however, is how to manage the stable patient with penetrating neck trauma. The last 2 decades have seen a major shift in the management from mandatory surgical exploration

If the patient is not expected to be fully conscious within 48 hours, then a CT of the whole cervical spine is required to exclude any cervical spine injury.

In damage control surgery, the major initial priorities are to control the bleeding and to prevent bowel spillage.

in all cases towards a more selective, conservative approach based on clinical findings and specialised investigations. The introduction of diagnostic tools such as oesophagography, flexible endoscopy, angiography, colour flow Doppler imaging and multislice helical computed tomography has resulted in an increasing confidence in the ability to detect injuries in the neck. The fact that certain of these injuries can be managed safely conservatively or more effectively by endovascular interventions has further swung the pendulum towards the selective, conservative approach.

The proponents of selective exploration on the basis of special investigations allude to the high rate of negative explorations in mandatory neck explorations and the excellent sensitivity of special investigations such as angiography, oesophagography, oesophagoscopy and flexible laryngotracheobronchoscopy in excluding clinically significant injuries. Also many of the injuries detected at mandatory exploration, such as thyroid, pharyngeal and certain venous trauma may be treated conservatively. Four prospective studies on the selective conservative approach to the management of penetrating cervical injuries have confirmed the safety of such an approach with successful conservative management in 80%. The patient is assessed clinically with the direction of the tract taken into account as well as the potential structures that may have been injured. Further investigations are considered on the basis of clinical symptoms and signs. The selection for exploration can be made on the basis of careful initial and repeated clinical examination. Selective observation based on clinical examination and the use of adjunctive investigations based on these clinical examinations have been shown to be able to exclude clinically significant injuries at several large trauma centres.

Transmediastinal gunshot wounds

Haemodynamically unstable patients who have sustained a transmediastinal gunshot wound (TMGSW) to the chest require emergency surgery. The traditional evaluation of haemodynamically stable patients with a TMGSW has been angiography and either an oesophagogram or endoscopy. The advent of contrast-

enhanced helical CT scanning has enabled the mediastinal tract of the gunshot to be delineated. If the tract on CT scan is away from any major structures then no further investigations are required. If on CT there is a mediastinal haematoma then an angiogram is indicated, if there is mediastinal air then an oesophagogram is warranted. In this way the CT scan has become the screening method of choice to determine which further investigations are required in TMGSW to the chest.⁵

Damage control surgery

A major advance over the last decade has been the introduction of damage control surgery into the armamentarium of the trauma surgeon.⁶ The previous surgical philosophy in operating on trauma patients was to repair all the injuries regardless of the time taken and the physiological state of the patient. This often resulted in lengthy procedures being performed on very unstable patients. The patients would become cold and develop what is called the 'lethal triad' of hypothermia, acidosis and disseminated intravascular coagulation. It is now accepted that this is no longer appropriate surgical management and not all injuries require early definitive management.

In damage control surgery, the major initial priorities are to control the bleeding and to prevent bowel spillage. This is achieved by ligating bleeders, packing livers and retroperitoneal bleeding, stenting arteries and ureters and ligating bowel with a suture. The abdomen can be left open (open abdomen) with the bowel covered by a plastic bag to prevent evisceration. The patient is then taken to the intensive care unit for stabilisation, rewarming and correction of any clotting abnormalities. The patient is taken back

It has now become apparent that around a third of isolated gunshot wounds to the liver may be treated with non-operative management.

to the operating theatre 24 hours later for definitive repair of the injuries. The packs can be removed, arteries repaired, and the bowel re-anastomosed.

The indications for instituting a damage control approach are profound haemodynamic instability, major multiple intra-abdominal or chest injuries, blood transfusion requirement of more than 10 units and a lactate level of greater than 5 mmol/l.

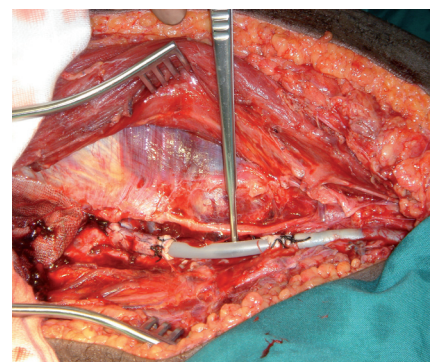


Fig. 4. A plastic stent inserted into the superficial femoral artery.

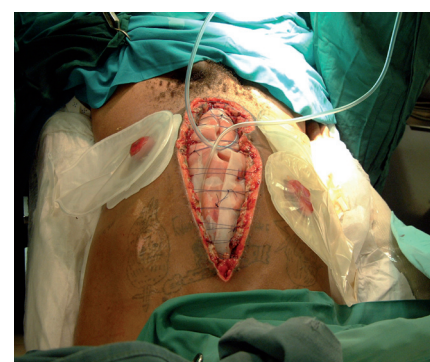

Fig. 5. An open abdomen.

This damage control approach has resulted in a significant improvement in the survival rates following major trauma.

Non-operative management of gunshot wounds to the liver

A gunshot wound to the abdomen was considered to be an indication for a mandatory laparotomy. It has now become apparent that around a third of isolated gunshot wounds to the liver may be treated with non-operative management. These patients need to be haemodynamically stable, fully conscious to allow for serial abdominal observations, to have no active bleeding from the liver on the CT scan, and have a high-care bed available for close monitoring. These patients should, however, only be managed non-

operatively in a trauma centre with access to endoscopic retrograde cholangiography, angiography and percutaneous drainage under CT guidance in order to deal with any external biliary fistulae, false aneurysms or liver abscesses that may complicate such a conservative policy.⁷

Screening tests in the evaluation of blunt abdominal trauma

Focused assessment with sonography for trauma (FAST) has become available in the emergency room to exclude intra-abdominal injury. It screens four areas for blood collections, namely the perisplenic, perihepatic, pelvis and pericardium (the 4 Ps). It should, however, only be used for abdominal evaluation in the haemodynamically unstable, unconscious patient after blunt trauma. The abdomen is then screened as a potential source of blood loss and a positive result will be an indication for a laparotomy. A FAST should not be used in penetrating trauma and it is not particularly sensitive for excluding bowel perforations. It is operator dependent and should probably not be performed in the case of associated pelvic fractures.

CT scanning of the abdomen is only an option in the haemodynamically stable patient. It allows for assessment of the retroperitoneal structures, such as the pancreas, but is only able to identify bowel perforations in about 30% of cases.

A diagnostic peritoneal lavage (DPL) is a useful test in the haemodynamically unstable patient with a head injury

after blunt trauma. It is an alternative to FAST but is contraindicated in the case of previous abdominal surgery and pregnancy. A nasogastric tube and a urinary catheter must be inserted prior to a DPL. It is extremely sensitive for blood in the peritoneal cavity but not very specific. A positive DPL is an indication for laparotomy. DPL is also not very sensitive for detecting bowel perforations.

Minimally invasive surgery

Thoracoscopy is being successfully used to clear out the chest of empyemas and clotted haemothoraces. This obviously avoids the pain and recuperation time required for an open posterolateral thoracotomy. Laparoscopy appears to be useful to exclude tangential gunshot wounds to the abdomen (not breaching the peritoneum) and for detecting diaphragm injuries. Laparoscopy also does not appear to be particularly sensitive in detecting small-bowel perforations.

Advanced Trauma Life Support Course (ATLS) and the Definitive Surgical Trauma Course (DSTC)

The introduction of the Advanced Life Support Course (ATLS) in South Africa has been a major advance with respect to the resuscitation and emergency management of the injured patient. It has provided a standard of care and allowed a common

language to be spoken with respect to the resuscitation and in the arranging of transfers. The Trauma Society of South Africa organises the ATLS courses (www.traumasa.co.za). Recently the Definitive Surgical Trauma Course (DSTC), run under the auspices of the International Association for the Surgery of Trauma and Surgical Intensive Care (IATSIC), has been started in South Africa. This course is aimed at general surgeons performing trauma surgery in South Africa and offers protocols and guidance in dealing with the operative trauma.

References

1. Peitzman AB, Courcoulas AP, Stinson C, *et al.* Trauma centre maturation. Quantification of process and outcome. *Ann Surg* 1999; 230: 87-94.
2. Beningfield S, Potgieter H, Nicol A, *et al.* Report on a new type of trauma full body digital X-ray machine. *Emerg Radiol* 2003; 10: 23-29.
3. Boffard KD, Goosen J, Plani F, *et al.* The use of low dose X-ray (Lodox/Statscan) in major trauma: comparison between low dose X-ray and conventional X-ray techniques. *J Trauma* 2006; 60: 1175-1183.
4. Hoyt DB. What's new in trauma and critical care. *J Am Coll Surg* 2002; 194: 335-351.
5. Ibirogba S, Nicol AJ, Navsaria PH. Screening helical computed tomographic scanning in haemodynamic stable patients with transmediastinal gunshot wounds. *Injury* 2007; 38: 48-52.
6. Koraklis G, Spirakos S, Glinavou A. Damage control surgery: An alternative approach for the management of critically injured patients. *Surg Today* 2002; 32: 195-202.
7. Omshoro-Jones JAO, Nicol AJ, Navsaria PH, *et al.* Selective non-operative management of liver gunshot injuries. *Br J Surg* 2005; 92: 890-895.

In a nutshell

- The injured patient must be taken to the most appropriate hospital and not the closest.
- A more liberal use of the CT head is required in children after head trauma.
- An open mouth view is not accurate in the intubated patient.
- A CT scan may be used to determine the need for angiography and contrast studies in the stable patient with the transmediastinal gunshot wound.
- Damage control surgery is an attempt to control bleeding and prevent contamination as rapidly as possible.