

# Modern imaging in patients with obstructive jaundice

**The evaluation of cholestatic jaundice is a common problem in clinical practice.**

**J E J KRIGE, MB ChB, FACS, FRCS, FCS (SA)**

*Professor, Department of Surgery, Faculty of Health Sciences, University of Cape Town  
Principal Specialist and Head, HPB Surgical Unit, Groote Schuur Hospital, Cape Town*

*Professor Krige is ad hominem Associate Professor in the Department of Surgery, University of Cape Town. He received his surgical training at the University of Cape Town and the University of California in Los Angeles and is a Fellow of the Royal College of Surgeons of Edinburgh, the American College of Surgeons and the College of Surgeons of South Africa. His major areas of clinical interest include portal hypertension and oesophageal varices, upper gastro-intestinal interventional endoscopy and surgical diseases of the liver, bile ducts and pancreas.*

**S J BENINGFIELD, MB ChB, FF Rad (D) (SA)**

*Professor, Department of Radiology, Faculty of Health Sciences, University of Cape Town  
Chief Specialist, Department of Radiology, Groote Schuur Hospital, Cape Town*

*Professor Beningfield undertook his radiology training at the University of Cape Town and is a Fellow of the College of Radiologists of South Africa. His major areas of clinical interest include imaging and intervention in hepatobiliary disease, vascular imaging and intervention, and computer applications in radiology.*

**J M SHAW, MB BCh, FCS (SA)**

*Full-time Consultant, Department of Surgery, Faculty of Health Sciences, University of Cape Town and HPB Surgical Unit, Groote Schuur Hospital, Cape Town*

*Dr Shaw completed his postgraduate surgical training at the University of Cape Town. He is a Fellow of the College of Surgeons of South Africa and has the Certificate in Surgical Gastroenterology from the Colleges of Medicine of South Africa.*

Often, cholestatic jaundice caused by intrahepatic hepatocellular disease may be clinically and biochemically indistinguishable from cholestasis due to extrahepatic bile duct obstruction. The most common intrahepatic causes of jaundice are viral hepatitis, alcohol-induced hepatitis, cirrhosis and drug-induced jaundice. Extrahepatic jaundice is most often due to a stone in the common bile duct (CBD) or a pancreaticobiliary malignancy (pancreatic, ampullary or cholangiocarcinoma). Pancreatic pseudocysts, chronic pancreatitis, sclerosing cholangitis, benign bile duct strictures or parasites in the bile duct are less common causes.

The principal clinical task is to distinguish obstructive jaundice from jaundice due to parenchymal liver disease. If major bile ducts are obstructed, surgery or therapeutic endoscopy may be required, but should be avoided in parenchymal liver disease as inappropriate intervention may aggravate the situation. In most patients, a likely cause of jaundice can often be established by taking a careful history, completing a thorough physical examination, testing the urine and stool, and requesting basic haematology and liver function tests, including viral serology (Table I). These easily obtained blood tests may confirm the initial clinical diagnosis or refine the differential diagnosis and direct further appropriate investigations. Since most jaundiced patients are not critically ill when initially assessed, diagnosis and therapy can be undertaken in a stepwise fashion, with each subsequent test logically selected according to the information available at that point. Only severe or worsening cholangitis requires urgent intervention.

Over the past decade technical advances in imaging equipment have significantly modified the investigation of biliary tract

**Table I. First steps in the diagnosis of jaundice**

- Clinical history
- Physical examination
- Urine examination
- Stool examination
  - Biochemistry
  - Bilirubin
  - Alkaline phosphatase
  - Gamma GT
  - Transaminases
- Haematology
  - Haemoglobin
  - WBC
  - Platelets
  - INR
- Viral markers

diseases. A wide array of special investigations, including expensive and invasive procedures, is now available for evaluating the jaundiced patient with suspected biliary obstruction. Complete assessment of biliary obstruction requires detailed imaging to define the exact level and cause of the biliary obstruction, and to implement treatment. Currently available technologies include transabdominal ultrasonography (US), endoscopic retrograde cholangiopancreatography (ERCP), percutaneous transhepatic cholangiography (PTC), endoscopic ultrasound (EUS), magnetic

resonance imaging with cholangio-pancreatography (MRI, MRCP) and helical (or spiral) computed tomography (CT). Direct imaging techniques such as ERCP and PTC are invasive and carry a higher associated risk, but have the added ability to sample tissue and perform biliary drainage with stenting or stone removal. Indirect techniques offer lower procedural risk and permit staging of malignancies. New direct radiological investigations such as MRCP (often together with solid-organ MRI), EUS, and spiral CT provide improved imaging quality at low risk. However, without a clear and rational strategy, the inappropriate use of imaging may lead to the duplication of investigations with resultant increased costs, delayed diagnosis and, possibly, unwarranted morbidity.

### Initial imaging in obstructive jaundice

Radiological imaging is the cornerstone of diagnosis in patients with suspected extrahepatic obstructive jaundice. Several algorithmic approaches have been described, all starting with an ultrasound scan (Fig.1). If dilated ducts are seen on ultrasound, referral to a specialist with experience in hepatobiliary disease is wise, as endoscopic or surgical intervention may be required. Accurate information about the level of biliary obstruction is essential because therapy may be complex with hilar obstructions, and these patients are therefore best treated by a multidisciplinary group.

### Transabdominal ultrasonography

Abdominal US is the initial imaging test of choice in jaundiced patients because it is non-invasive, inexpensive and readily available. US is highly operator dependent and requires skill and experience to produce consistently good results. Dilated ducts are indirect evidence of biliary obstruction. As a rough guide, a CBD of less than 7 mm internal transverse diameter is regarded as normal, while a larger diameter suggests biliary obstruction. US is particularly useful because it offers the ability to assess pancreaticobiliary structures non-invasively and in real-time without exposing the patient to ionising radiation. A definitive diagnosis can be made by demonstrating gallstones in the gallbladder or CBD, or a mass in the head of the pancreas. In patients without dilated ducts, hepatocellular disease is the likely diagnosis; however, parenchymal liver disease or sclerosing cholangitis may prevent biliary dilatation despite obstruction being present.

Other than being nil per mouth little preparation is required, so the procedure is generally well tolerated. As new-generation US scanners are compact and self-contained, the equipment can be wheeled to the patient in the ward, the ICU or the operating theatre. A unique application of US is colour Doppler imaging that can be used to assess the patency, direction and volume of blood flow in critical vessels such as the portal, superior mesenteric and hepatic veins, and hepatic artery.

Although US is widely used, there are important limitations. The clearest images

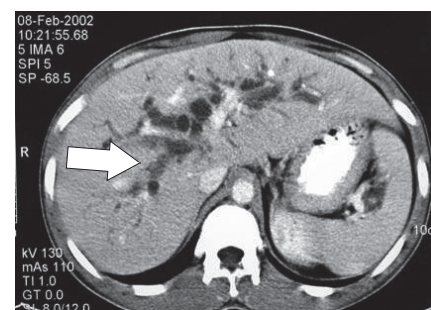


Fig. 2. CT scan showing dilated bile ducts (arrow).

are obtained in lean patients because resolution deteriorates with depth and obesity; bone and gas are impenetrable and further limit visibility.

### Computed tomography (CT) scanning

CT technology has improved significantly over the past two decades (Fig. 2). The evolution has proceeded through several stages, from conventional CT to helical (or spiral) CT to new, multidetector CT in which ultrafast detector rotation and collimation can be combined to yield high-resolution, three-dimensional reconstructions of the liver, pancreas and related structures with excellent vascular enhancement.

Spiral CT after intravenous injection of iodinated contrast medium allows the rapid acquisition of images during the arterial, portal, and delayed parenchymal phases. It also provides high-quality, three-dimensional reconstructions in various formats and can depict up to third-order intrahepatic branches.

These advances in technology have expanded the role of CT in evaluating the biliary tree. The high-resolution, thin-slice images in single breath-holds, and the ability to display these images in cine mode and coronal views are ideal for tracing the dilated bile ducts to the point of obstruction. CT scanning is also helpful in evaluating liver masses, often complementing US. CT is now widely accepted as the imaging method of choice to detect, stage, and assess resectability of pancreatic tumours.

The major advantages of spiral CT over ERCP or EUS include its low level of invasiveness, minimal operator dependence, low technical failure rate and, in contrast to ERCP, ability to produce a three-dimensional image of the biliary tree. The major limitations of CT are the inability to detect small peritoneal implants, small hepatic metastases, lymph node metastasis in normal-sized nodes, and intraductal tumour extent. Spiral CT gives a relatively high dose of radiation to

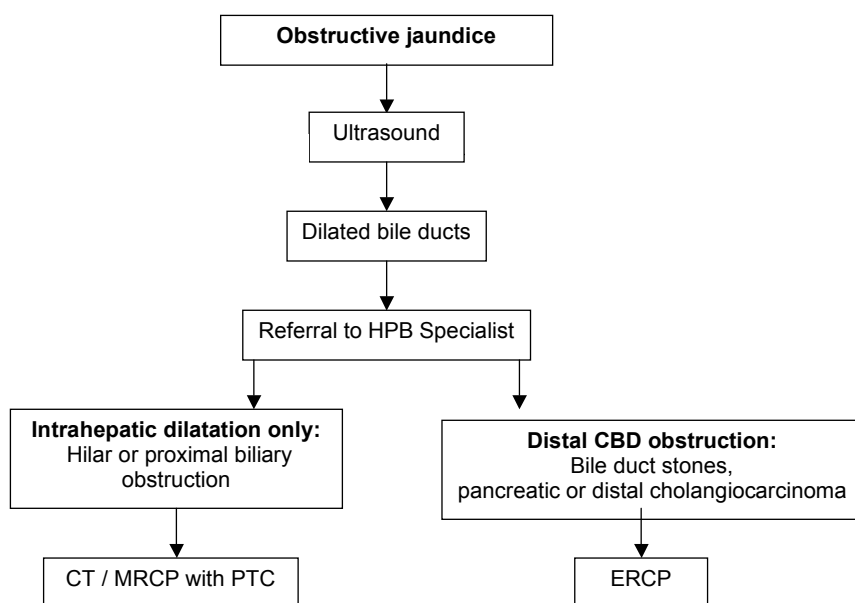


Fig. 1. Algorithmic approach to imaging in obstructive jaundice.

## Obstructive jaundice

patients and a further drawback is a small risk of adverse reaction to the iodinated contrast agents. Its main limitation is in patients with impaired renal function with high serum creatinine levels, as contrast may be nephrotoxic. Artefacts produced by patient movement, respiration and support devices also limit diagnostic value.

### Magnetic resonance imaging (MRI)

MRI is the most recent advance in cross-sectional imaging of the bile ducts and liver. The physics of MRI is complex and uses magnetic fields and radiowaves to chart the regional density of mobile hydrogen nuclei in the body. Although spiral CT is usually the first choice in cross-sectional imaging of the liver and pancreas, MRI is rapidly evolving in the evaluation of the patient with pancreatic cancer as a 'one-stop shop'. MRI is also useful in patients with contrast allergy or in those with reduced renal function, provided gadolinium is avoided.

### Magnetic resonance cholangiopancreatography (MRCP)

This technique involves the manipulation of a volume of data acquired by MRI. A heavily T2-weighted sequence enhances the signal of 'water-filled' bile and pancreatic ducts without the use of contrast material or ionising radiation, to produce high-quality images of ductal anatomy (Fig. 3).

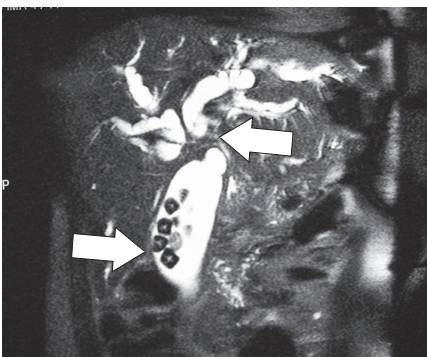


Fig. 3. MRCP showing bile ducts obstructed by a hilar cholangiocarcinoma (upper arrow) and incidental gallstones in the gallbladder (lower arrow).

MRCP is accurate in demonstrating the presence and level of biliary obstruction, but is less sensitive for detecting small stones. The major advantage of MRCP is the non-invasive nature of the procedure. It usually does not require conscious

sedation and, in contrast to ERCP, MRCP can demonstrate the biliary tree above and below complete obstructions. In cholangiocarcinoma, the main advantage of MRCP is that it can non-invasively provide a three-dimensional image of the biliary tree, which can help in planning treatment. The major disadvantages of MRCP compared with ERCP are lower resolution, unit availability, lack of any immediate therapy for duct obstruction, claustrophobia, and the inability to evaluate patients with pacemakers or ferromagnetic implants.

### Endoscopic retrograde cholangiopancreatography (ERCP)

ERCP is regarded as the gold standard for imaging the biliary system and combines the advantage of diagnosis of biliary obstruction with therapeutic intervention, if required. ERCP is the intervention of choice in patients with CBD stones and in the palliation of malignant biliary obstruction (Figs 4 - 6). The drawbacks of ERCP include high equipment costs, the need for conscious sedation, and dependence on skilled interventional endoscopists. The failure rate increases substantially

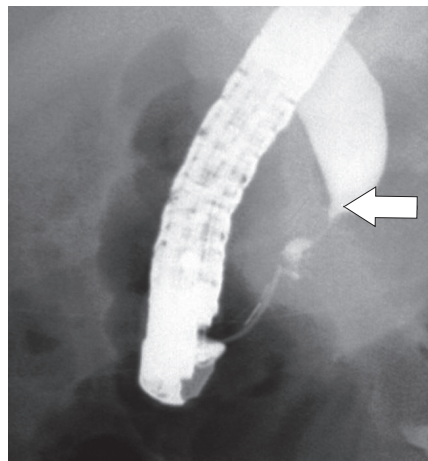


Fig. 4. An ERCP demonstrating a malignant distal CBD stricture (arrow) secondary to a pancreatic carcinoma.

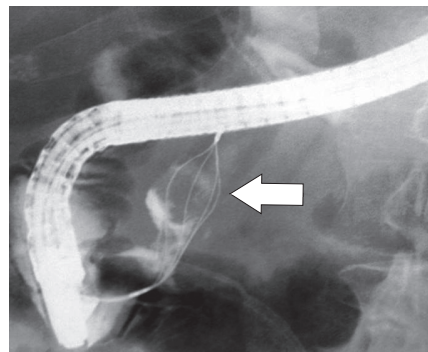


Fig. 5. ERCP basket extraction of CBD stone (arrow).

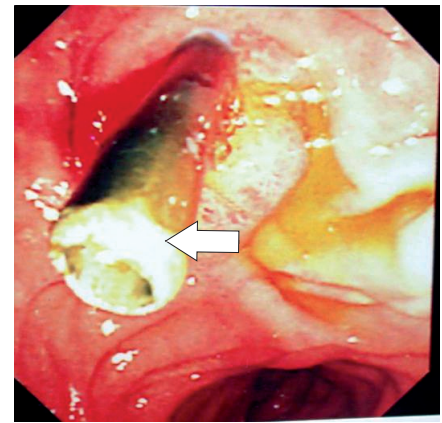


Fig. 6. Endoscopic plastic transpapillary biliary stent (arrow).

in patients with altered anatomy, such as after a Billroth II gastrectomy, or in patients with duodenal narrowing due to tumour infiltration. Stenting a proximal hilar cholangiocarcinoma can be difficult, and undrained contrast injection above the site of obstruction usually mandates urgent PTC biliary drainage because of the risk of cholangitis. The most common complications after ERCP are acute pancreatitis and cholangitis, which are severe in 1% of patients. Because of these risks and the availability of MRCP, ERCP is evolving into a predominantly therapeutic procedure.

### Percutaneous transhepatic cholangiography (PTC)

PTC involves puncture, under local anaesthesia, of either the left or right liver lobe with a fine flexible needle using fluoroscopic guidance to enter a peripheral intrahepatic bile duct. Contrast is injected to outline the biliary system and identify the obstruction. A skilled interventional radiologist can successfully opacify the intrahepatic biliary tree in nearly all patients with dilated ducts, and in most patients with non-dilated ducts (Fig. 7). The overall procedure morbidity is less than 5%. Possible complications include bleeding, bile leaks, cholangitis, septicaemia, pneumothorax, and rarely allergic reactions to the contrast medium. PTC is performed primarily in patients in whom ERCP has failed, or when altered anatomy precludes access to the ampulla, and for biliary drainage and stenting in patients with irresectable hilar cholangiocarcinoma.

### Endoscopic ultrasonography (EUS)

This technique uses a small high-frequency ultrasound probe mounted on the tip of an endoscope that is positioned in the duodenum by direct vision. The close

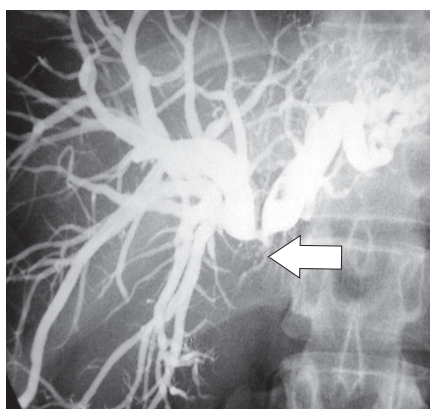


Fig. 7. PTC showing a hilar cholangiocarcinoma (arrow).

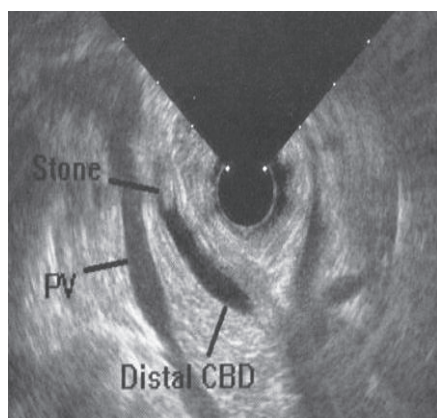


Fig. 8. Endoscopic ultrasound showing a gallstone in the CBD.

proximity of the probe to the bile ducts and pancreas permits high-resolution imaging. Several features make EUS a very useful procedure. EUS is less invasive

than ERCP, is able to identify most causes of obstructive jaundice such as pancreaticobiliary malignancies and CBD stones with similar or better accuracy than ERCP (Fig. 8), and does not expose the patient to radiation or contrast material.

Tissue sampling in the form of EUS-guided fine-needle aspiration can also provide a cytological diagnosis and important staging information in pancreaticobiliary malignancies. The limitations of EUS include high operator dependency with a steep learning curve, equipment cost and availability, the inability to provide any immediate therapeutic procedure and the need for conscious sedation. Visualisation is limited to within 8 cm from the probe, and imaging can be obscured by stents, surgical clips or calcific pancreatitis.

### Applying further imaging in obstructive jaundice

If US demonstrates dilated intrahepatic bile ducts and a hilar tumour is suspected, MRCP is the next investigation of choice, as more accurate non-invasive imaging of the level and extent of the bile duct obstruction is obtained (Fig. 1). CT scanning is complementary to US and provides information on liver parenchyma, gallbladder pathology, bile duct dilatation and pancreatic disease. CT is particularly valuable for the recognition of lesions as small as 1 cm in either the liver or

the pancreas. If further non-operative intervention is necessary to define the extent more accurately or relieve biliary obstruction, either ERCP or PTC are the second-line procedures used. ERCP is advisable when the obstruction involves the lower common bile duct such as with gallstones or carcinoma of the head of the pancreas. PTC is preferred for high obstructions (hilar cholangiocarcinoma or strictures of the hepatic duct bifurcation) because of better biliary opacification above the obstruction and a lower risk of introducing sepsis.

In most patients, a low obstruction of the CBD is drained endoscopically by ERCP, either by sphincterotomy and stone removal, or by inserting an intraluminal transpapillary biliary stent. A stent may be the definitive treatment for inoperable carcinomas or in frail patients with large CBD stones. For patients who have biliary infection and who require surgery, stenting provides effective preoperative biliary drainage by allowing the infection and jaundice to resolve and liver function to recover. In patients who have irresectable hilar cholangiocarcinoma, expandable metal biliary stents provide effective palliation. Percutaneous US-guided liver biopsy may be required to determine the nature and histological stage of intrinsic parenchymal liver disease, while laparoscopy with US is used in selected patients to assess and stage liver, biliary or pancreatic tumours before resection.

### In a nutshell

- Cholestatic jaundice caused by intrahepatic hepatocellular disease may be clinically and biochemically indistinguishable from cholestasis due to extrahepatic bile duct obstruction.
- The most common intrahepatic causes of jaundice are viral hepatitis, alcohol-induced hepatitis, cirrhosis and drug-induced jaundice.
- Extrahepatic jaundice is most often due to a stone in the common bile duct or a pancreaticobiliary malignancy. Pancreatic pseudocysts, chronic pancreatitis, sclerosing cholangitis, benign bile duct strictures or parasites in the bile duct are less common causes.
- Ultrasound is a useful initial investigation because it is non-invasive and assesses pancreaticobiliary structures in real-time without exposing the patient to ionising radiation.
- Dilated ducts are indirect evidence of biliary obstruction.
- If bile ducts are not dilated, hepatocellular disease is the likely diagnosis; however, parenchymal liver disease or sclerosing cholangitis may prevent biliary dilatation despite obstruction being present.