

Diabetic foot ulcers – evidence-based wound management

A diabetic foot ulcer should be regarded as a medical emergency.

GREGORY WEIR, MB ChB, MMed (Chir), Certificate in Vascular Surgery (SA College of Medicine), Trauma & Vascular Fellowship (Australia)

President, Wound Healing Association of Southern Africa (WHASA) and Medical Director, Vascular and Hyperbaric Unit, Life Eugene Marais Hospital, Pretoria

Gregory Weir is a registered and certified vascular surgeon. His practice focuses on cerebrovascular and peripheral vascular disease. He has an interest in wound care and specifically the management of diabetic patients with complicated foot ulcers secondary to ischaemia. His research interest includes the appropriate, selective use of hyperbaric oxygen therapy in the treatment of diabetic foot ulcers.

Correspondence to: gweir@vascular.co.za

This article aims to summarise the available evidence in the wound management of diabetic foot ulcers to promote cost-effective evidence-based practice. Diabetic foot ulcers have a significant impact on the individual patient's quality of life, potential morbidity and even mortality. Diabetic foot ulcers also consume a gradually increasing portion of our health care budget. Whenever possible the focus should be on prevention rather than cure. All diabetic patients must have both their feet examined, with every consultation, by every health care practitioner. When an ulcer has already developed, it should be managed as a medical emergency, requiring an intensive interdisciplinary team approach to avoid potential loss of limb and/or life.

According to the International Working Group on the Diabetic Foot (<http://www.iwgdf.org/>) only two-thirds of diabetic foot ulcers will eventually heal.¹ The median time to healing of all ulcers is approximately 6 months. Up to 28% of all diabetic foot ulcers may result in some form of amputation.

Initial steps

First things first: assess the patient as a whole before addressing the hole in the patient. Take a careful history to determine general health, glycaemic control, complications and co-factors that may cause skin breakdown or affect the healing of an ulcer (e.g. smoking).² Never make any assumptions with regard to the patient's prior medical management. At the recent International Interdisciplinary Wound Care Course (IIWCC) at Stellenbosch University, Professor Gary Sibbald referred to the following enabler to summarise general supportive care of all diabetic patients:

ABCDE:

- **A** Tight glycaemic control (HbA_{1c})
- **B** Tight **B**lood pressure control
- **C** Tight **C**holesterol control
- **D** Individualised diabetic **D**iet
- **E** Supervised **E**xercise

A complete physical assessment that includes vascular status (ABPI, TBPI, TcPO₂), structural or bony deformities, footwear and sensation is essential. This will influence the appropriate

management of the patient with a diabetic foot ulcer prior to commencement of conservative wound care. Depending on the clinical findings the priorities could be:

VIPs:

- **Vascular:** Restore arterial circulation to the limb to optimise O₂ delivery to the ulcer
- **Infection:** Treat systemic bacterial infections with systemic antibiotics (not topical)
- **Pressure:** Redistribute pressure by offloading the foot and applying dressings
- **Sharp debridement:** Remove devitalised tissue by sharp surgical debridement

The health care practitioner who identifies the patient at risk should immediately modify factors that could cause skin breakdown and/or influence healing and refer the patient to an interdisciplinary wound care team to ensure comprehensive care and individualised patient education.²

A complete physical assessment that includes vascular status (ABPI, TBPI, TcPO₂), structural or bony deformities, footwear and sensation is essential.

Debridement

The term debridement refers to the removal of surface debris, devitalised tissue (slough) and infected matter. The aim is to allow the remaining viable tissue to heal by secondary intention. Debridement can be done surgically (sharp debridement), biologically (maggot debridement therapy), biochemically (enzymes) or chemically (antiseptics).

The evidence in support of the benefit of sharp debridement indicates that healing is more likely with more extensive debridement.³ In the absence of adequate arterial supply aggressive debridement and

Preparing the Wound Bed Paradigm

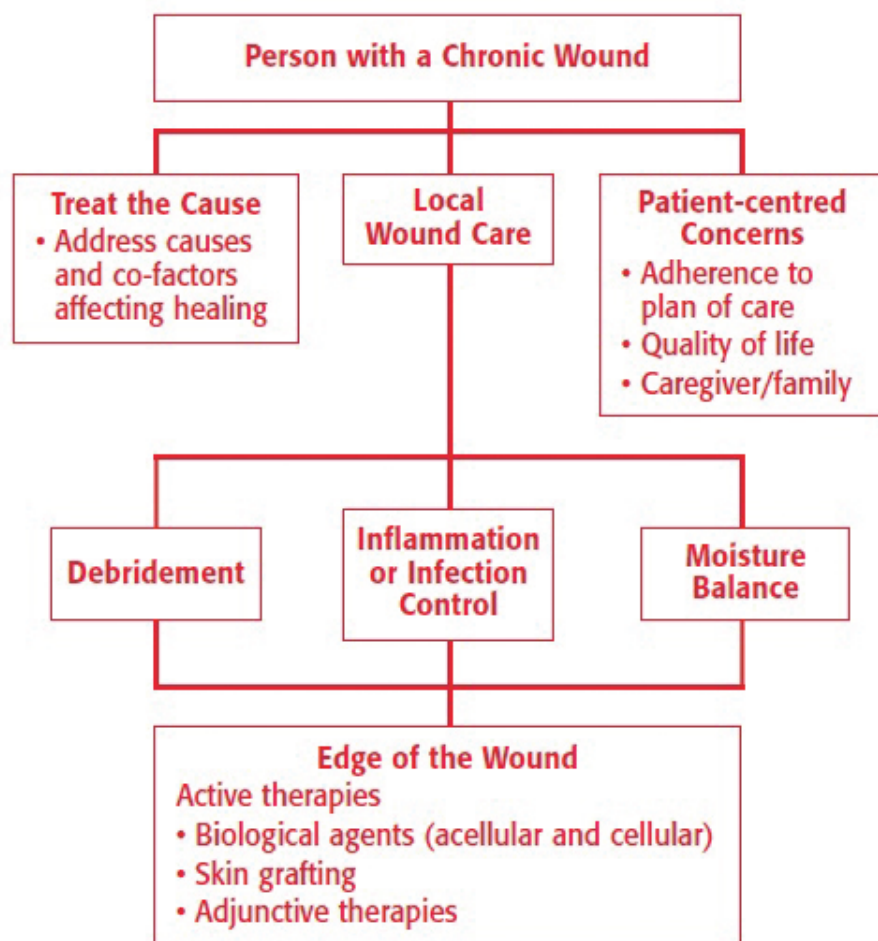


Fig. 1. Preparing the wound bed.

even moist interactive dressings are not recommended.²

Biological debridement with disinfected fly larvae (maggot debridement therapy) is associated with decreased time to healing, decreased incidence of major amputation and reduced requirement for antibiotics.

The evidence in support of the benefit of sharp debridement indicates that healing is more likely with more extensive debridement.

Wound bed preparation

Dressing products should provide an optimal wound healing environment encouraging debridement, inflammation and infection control, as well as moisture balance. Always monitor the effectiveness of interventions and reassess if skin

breakdown occurs (wound edge) and/or if healing is not occurring at the expected rate. Fig. 1 illustrates the paradigm for preparing the wound bed.⁴

Antiseptics

None of the commercially available antiseptics have demonstrated any significant benefit over normal saline or sterile water. The potential risks associated with the use of some of these antiseptics (e.g. sensitisation and/or allergic responses) support the routine use of normal saline or sterile water for cleaning diabetic foot ulcers. Cold fluids may contribute to pain and should be avoided.

Dressings

Alginate and collagen-alginate products

Collagen-alginate dressings have not been proven to be effective with regard to either wound area or rate of healing. In practice the alginates are often used because of their haemostatic and absorptive properties. Because of these properties, alginates are often used after sharp surgical debridement.

Hydrogels

A single open-label randomised controlled trial reported a benefit in terms of healing of non-ischaemic foot ulcers when a hydrogel was compared with saline-moistened gauze.

Carboxymethylcellulose hydrofibre dressing

A single, small randomised controlled trial of subjects with deep foot ulcers reported a significant reduction in days to healing when a carboxymethylcellulose hydrofibre dressing was compared with saline moistened gauze.

Polymeric semi-permeable membrane

A reduction in ulcer area has been reported with the use of a polymeric semi-permeable membrane dressing, compared with saline moistened gauze.

Dressing products should provide an optimal wound healing environment encouraging debridement, inflammation and infection control, as well as moisture balance.

Resection of the chronic wound

If the wound does not respond to conservative therapy, intervention and/or adjuvant options should be considered.² The rationale for resecting a chronic ulcer and its base is that a chronic wound will be replaced by an acute one which will proceed to heal at an increased rate. Moreover, if the process of resection includes the removal of bone underlying ulcers in areas subjected to abnormal pressure loading (such as under the metatarsal heads), then healing may be enhanced by the off-loading which results.

Excision of plantar ulcers with or without removal of underlying bone

There is evidence to support complete excision of plantar neuropathic ulcers. The resection includes the entire wound bed, together with any underlying bony prominences. This is associated with faster

Ulcers

wound healing with fewer recurrences. This is especially true of ulcers beneath the hallux (Fig. 2), and to a lesser degree of the 5th metatarso-phalangeal joint. The evidence suggests that in practice extended resection might be considered earlier and more often in the management of neuropathic diabetic foot ulcer. This should not be done in patients with uncorrected arterial insufficiency.

Early excision of infected soft tissue

A single retrospective cohort study compared outcomes in patients admitted to hospital with extensive infection and who either did or did not undergo surgical

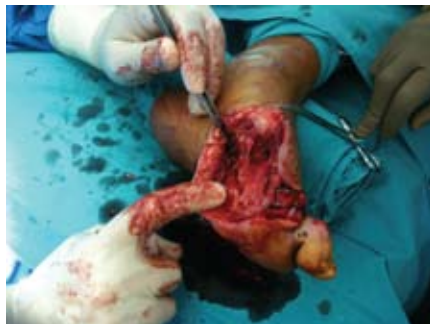

Fig. 2. Excision of plantar ulcer.

excision of infected tissue within 3 days of admission. Surgery led to a significantly reduced incidence of major amputation compared with those managed medically.

Hyperbaric oxygen (HBO_2)

Topical HBO_2

There is not sufficient evidence to support this modality. Recent studies on topical wound oxygen (TWO_2) suggested potential promise, but larger studies are required.

Systemic HBO_2

Hyperbaric oxygen therapy involves inhaling 100% oxygen at increased pressure in a chamber designed specifically for this purpose (Fig. 3). In the patient with a diabetic foot ulcer, this results in reduced wound oedema, improved oxygen supply and improved bacterial defence. Numerous cohort studies and four randomised controlled trials have provided some evidence to suggest that systemic HBO_2 reduces the rate of major amputation in patients who have chronic foot ulcers as a complication of diabetes. The study reported by Abidia *et al.*⁵ was the most robust and the only one which was blinded. It was based on a study population with severe peripheral arterial disease which was not amenable to revascularisation. The available evidence suggests that HBO_2 is of benefit for patients with diabetic foot ulcers with infection and/or ischaemia. In their review article Boulton *et al.*⁶ cautioned that patients with neuropathic ulcers without infection or ischaemia have not been demonstrated to benefit from HBO_2 (<http://www.sauhma.co.za/>).

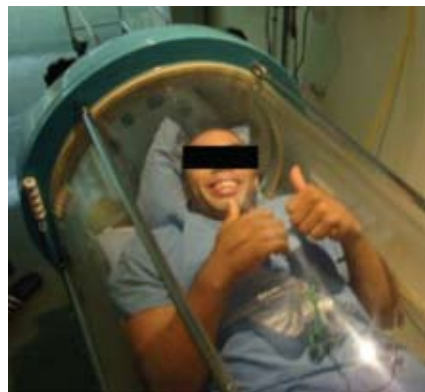

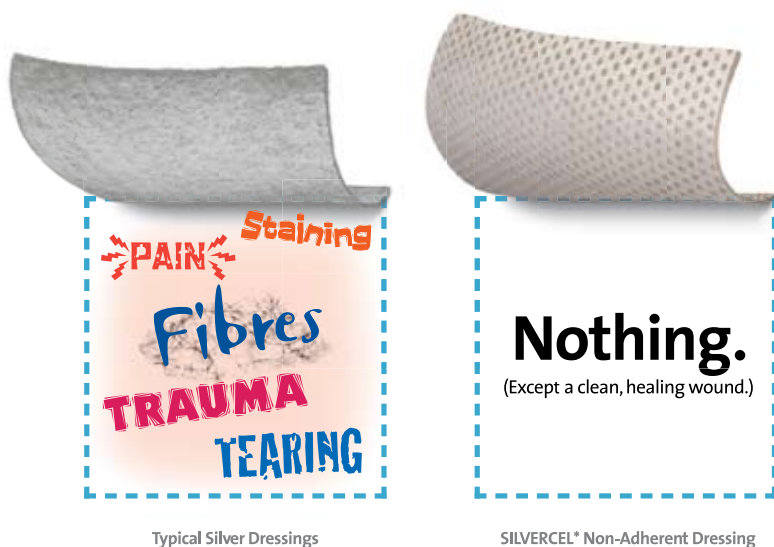Fig. 3. Hyperbaric oxygen therapy.

Ozone therapy (O_2)

The Environmental Protection Agency of the USA has warned against the toxicity of ozone ionisers and the adverse effects associated with their use. Unfortunately patients are regularly misled into buying expensive machines that offer the promise of 'ozone therapy' when in actual fact they are exposing themselves to a toxic gas. Ozone is not oxygen. (<http://www.epa.gov/o3healthtraining>)



What should **your** silver dressing leave behind?



Finally, a non-adherent silver alginate dressing!

Introducing a powerful antimicrobial dressing with a non-adherent layer for less traumatic dressing changes. SILVERCEL* Non-Adherent Dressing can be removed in one piece without sticking to the wound bed. Suitable for infected, chronic and acute wounds.¹

Tough on Infection. Easy on Patients .



Customer care line: +27 800 214 633

For further information please contact your local Systagenix Wound Management representative, or visit: www.systagenix.com

1. Data on file, Systagenix Wound Management.
*Trademark of Systagenix Wound Management IP Co. B.V. © Systagenix Wound Management 2009

Reduction of tissue oedema

Topical negative pressure (TNP) and compression therapy have been utilised after foot surgery to promote healing by reducing tissue oedema and possibly in the case of TNP, by minimising accumulation of surface debris.

Topical negative pressure

A benefit in both healing rate and healing time has been demonstrated in prospective randomised trials. A benefit of topical negative pressure in both time to and proportion of persons healing in postoperative wounds has also been demonstrated. Once again caution should be applied in the presence of ischaemia. Please refer to the WHASA consensus document on topical negative pressure therapy for more detail⁷ or go to <http://www.whasa.org>.

Compression

A single study has suggested a significant benefit of compression therapy in the absence of ischaemia.

The rationale for resecting a chronic ulcer and its base is that a chronic wound will be replaced by an acute one which will proceed to heal at an increased rate.

Growth factors

There have been a relatively large number of studies designed to evaluate the effect of growth factors and other agents which may modulate abnormalities of wound biology but there is currently little evidence to suggest that any of the interventions reported should be adopted in routine practice. The trial of platelet-derived growth factor (PDGF) undertaken in the USA reported apparent benefit in neuropathic foot ulcers, although this was not confirmed in a subsequent study.

The evidence from randomised controlled trials suggests that epidermal growth factor (EGF) may hasten healing, especially in neuropathic foot ulcers, and further randomised trials are urgently needed to

establish the effectiveness and cost benefit of EGF in routine care.

The effect of granulocyte-colony stimulating factor (G-CSF) was studied primarily to determine whether its use may help eradicate infection, and there has been no observed effect on ulcer healing. A meta-analysis has suggested that the use of G-CSF may be associated with a reduced incidence of major amputation in limb-threatening infection. Further robust and blinded studies are required before the potential role of G-CSF can be established.

Bio-engineered skin and skin grafts

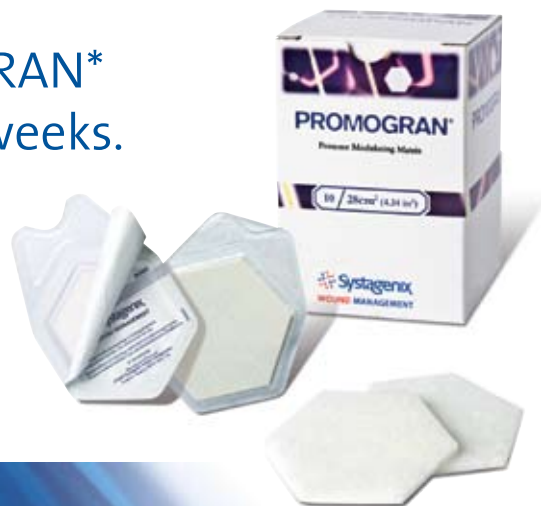Bio-engineered skin products and skin grafts may exert part of their effect through the release of growth factors and cytokines and although widely used in some areas, their role has not been clearly established in clinical practice.

There is currently no evidence to justify the use of other bio-engineered allograft skin products on a routine basis.

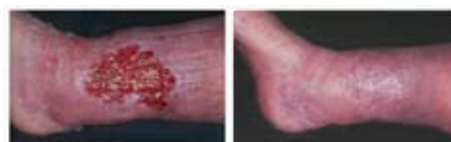PROMOGRAN*
PROTEASE MODULATING MATRIX

Question:
After treating the same wound for 7.5 years, what eventually healed it?

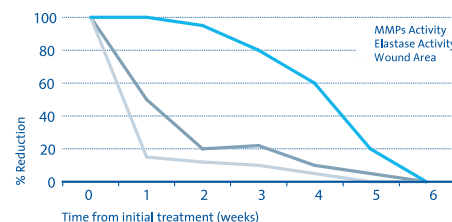
Answer:
PROMOGRAN*
in just 6 weeks.



MMPs, Elastase, and wound surface area, in a 7.5 year old wound⁽ⁱ⁾



If you think PROMOGRAN might bring the same quality of life back to your patients, heal more wounds faster^(2,3,4,5), and cost-effectively^(3,5,6), we are just an e-mail away:
Send it to: i-want-a-rep@systagenix.com
Quote on subject: PROMOGRAN



SYV01110006/2009

References: 1. Cullen, B, Boyle, C, Webb, Y. Modulation of the chronic wound environment; an in vitro evaluation of advanced wound therapies. SAWC, Tampa FL, 2007. 2. Nisi G et al. Use of protease-modulating matrix in the treatment of pressure sores. Chir Ital 2005;57:456-8. 3. Vin F et al. The healing properties of PROMOGRAN* in various leg ulcers. J Wound Care 2002;13:336-41. 4. Veves A et al. A randomized, controlled trial of PROMOGRAN* (a collagen/oxidized regenerated cellulose dressing) vs standard treatments in the management of diabetic foot ulcers. Arch Surg 2002;137:822-827. 5. Lazaro-Martinez et al. Estudio aleatorizado y comparativo de un apósito de colágeno y celulosa oxidada regenerada en el tratamiento de úlceras neuropáticas de pie diabético. Cir Esp. 2007;82(1):27-31. 6. Chatenekar O, Willis, M, Persson U. Health Economics. Cost effectiveness of treating deep diabetic foot ulcers with PROMOGRAN* in four European countries. J Wound Care, Vol 11, No.2, Feb. 2002. 7. Snyder. Sequential therapies and advanced wound care products as a standard practice in the home care setting. Home health abstract for SAWC, San Diego, April 2008 (presentation at the ISU satellite symposium)

Systagenix Wound Management (South Africa) (Pty) Ltd. Unit F3, Building 1, Greenstone Hill Office Park, Greenstone Hill, Edenvale, 1609 P.O. Box 3613, Edenvale, 1610 Tel: +27 860 968 637 Fax: +27 11 452 5597

Systagenix
WOUND MANAGEMENT
www.systagenix.com

Customer care line: +27 800 214 733

Other physical stimuli

None of the studies of the use of electrical, magnetic, ultrasound or laser therapy produced clear evidence of effect, although all reported some apparent benefit in *post hoc*, per protocol or subset analyses. The use of these modalities outside of a formal research protocol is not justified.

Conclusion

The current accepted management of a patient with a diabetic foot ulcer includes supportive care by an interdisciplinary team. This team should include all health care workers involved in the treatment of diabetic patients and their complications. The complex pathogenesis due to different causative factors makes the diabetic foot ulcer difficult to study. Trial design is extremely difficult due to multiple confounding factors. This explains why few interventions have robust evidence to support their use. There is some evidence to favour the use of hydrogels in the debridement of wounds with surface contamination. There is strong evidence to suggest that early excision of plantar neuropathic ulcers may be associated with accelerated healing and a reduced incidence of recurrence. Systemic HBO₂ therapy may also be associated with an improved outcome in those with inoperable peripheral arterial disease. There are some data to suggest that the use

of EGF may be associated with enhanced healing. Further evidence to substantiate the effect of these, and other, interventions is urgently needed.

You can make a difference by establishing, training and empowering a team to work with patients with diabetes and diabetic foot ulcers, or joining an established interdisciplinary team.

References

1. International Diabetic Federation. International Consensus on the Diabetic Foot – DVD. s.l. International Diabetes Federation, 2007.
2. Orsted HL, Searles GE, Trowell H, *et al.* Best practice recommendations for the prevention, diagnosis and treatment of diabetic foot ulcers: update 2006. *Wound Care Canada* 2006; 4: 1.
3. Steed DL, Donohoe D, Webster MW, *et al.* Effect of extensive debridement and treatment on the healing of diabetic foot ulcers. Diabetic Ulcer Study Group. *J Am Coll Surg* 183; 1: 61-64.
4. Sibbald RG, Schultz GS, Falanga V, *et al.* Preparing the wound bed 2003: Focus on infection and inflammation. *Ostomy/Wound Management* 2003; 49: 24-51.
5. Abidia A, Laden G, Kuhan G, *et al.* The role of hyperbaric oxygen therapy in ischaemic diabetic lower extremity ulcers: a double-blind randomised-controlled trial. *Eur J Vasc Endovasc Surg* 2003; 6: 513-518.
6. Boulton AJ, Carrington AL, Ashe H, *et al.* Clinical practice: Neuropathic diabetic foot ulcers. *N Engl J Med* 2004; 1: 48-55.
7. Naude L. Topical negative pressure therapy in wound management – A WHASA consensus document. *Wound Healing Southern Africa*. Vol. 2(2). Supplement: 1-6.

In a nutshell

- A diabetic foot ulcer requires an intensive interdisciplinary team approach.
- Optimal medical management of all diabetic patients is crucial (ABCDE).
- Diabetic patients must have both feet examined at every consultation.
- Prevention of a diabetic foot ulcer is always better than cure: education is key.
- More than 28% of all diabetic foot ulcers may result in some form of amputation.
- Adequate arterial supply is essential.
- Systemic antibiotics are given for systemic infections: avoid topical antibiotics.
- Pressure redistribution by offloading is essential in the neuropathic ulcer.
- Sharp debridement improves outcome in the absence of ischaemia.
- The ideal dressing maintains a moist, protective wound care environment.

Single Suture

It's safe to donate your kidney

Live kidney donors are one answer to the chronic shortage of kidneys for transplantation. But is it safe to donate a kidney to a relative? The most reassuring data so far come from a large cohort of more than 80 000 adult donors who had a nephrectomy between 1994 and 2009 in the USA. Just 25 died within 90 days of surgery – an associated mortality of 3.1 per 10 000 donations, which is substantially lower than the mortality associated with laparoscopic cholecystectomy (18/10 000).

Long-term survival was excellent. Donors were no more likely to die during 6 years of follow-up than matched controls from the general population. In fact, they were less likely to die, although this advantage was probably caused by residual differences in health and fitness that were unaccounted for by matching and adjustments. Donors are carefully selected after a battery of tests, say the authors. Controls were selected using basic demographic and co-morbidity information from a less detailed national survey. The donors were probably healthier.

Surgery was riskier for men than for women, and black donors had a higher surgical mortality than white or Hispanic donors. These subgroups should be counselled accordingly, say the authors. The small minority of donors with hypertension (2%) had the highest risks of all.

Segev DL, *et al.* *JAMA* 2010; 303: 959-966.