

# Principles of management of vascular problems in the diabetic foot

**A multidisciplinary approach accounting for the complex pathobiology and biomechanics of the diabetic foot is crucial to decrease the rate of amputations.**

**LYNNE TUDHOPE, MB ChB, MMed (Surg), BA**

*Registered Vascular Surgeon and Endovascular Specialist, Montana and Wilgers Hospitals, Pretoria*

*Lynne Tudhope is President of the Diabetic Foot Working Group of South Africa and an editorial board member for diabetes in the Journal of Wound Healing of South Africa. She has been an invited speaker at numerous international congresses on the diabetic foot. She has a special interest in endovascular treatment of the neuroischaemic diabetic foot and heads the multidisciplinary foot clinics at Montana and Wilgers hospitals in Pretoria.*

*Correspondence to: ltudhope@tiscali.co.za*

Recognising that the symptoms of foot ischaemia in a diabetic patient are caused by macrovascular stenosis or occlusion due to atherosclerosis is the most important principle in the management of lower limb salvage in diabetics. The erroneous concept that microvascular occlusion of arterioles, so-called small-vessel disease, is the cause of gangrene, ulceration and amputations in diabetics still persists, in spite of several studies proving otherwise.

**It is also important to remember that ischaemia is accompanied by infection in approximately 50% of patients with diminished perfusion to the foot, and that most patients will have peripheral neuropathy as well.**

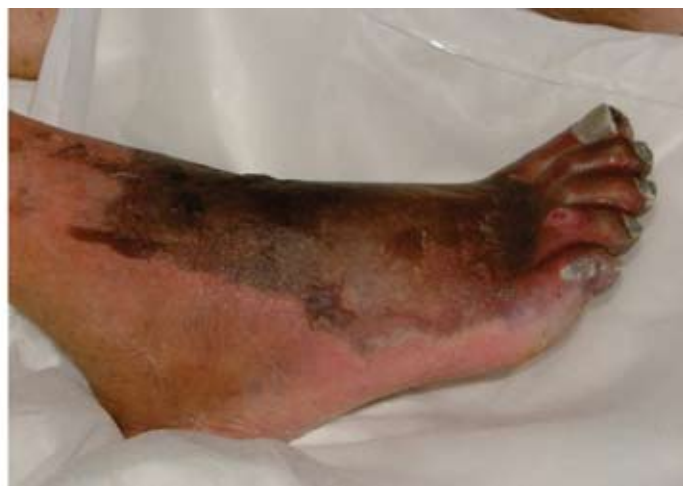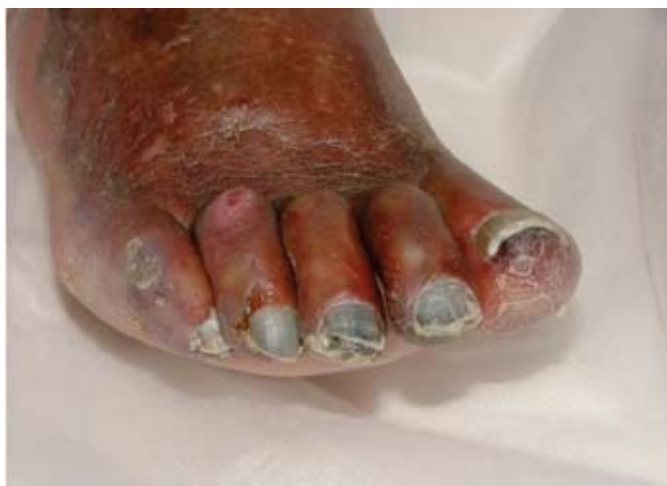It is also important to remember that ischaemia is accompanied by infection in approximately 50% of patients with diminished

perfusion to the foot, and that most patients will have peripheral neuropathy as well. A basic principle of management in foot salvage is therefore the understanding of the complex interplay of neuropathy, ischaemia and infection in each individual patient.

## *An approach to treatment*

The treatment of vascular insufficiency either by bypass grafting or endovascular intervention is crucial for limb salvage, but a multidisciplinary approach accounting for the complex pathobiology and biomechanics of the diabetic foot is crucial if amputation rates are going to be decreased.

Although the atherosclerotic disease process is histologically similar in both patient groups, generalised atherosclerosis is more prevalent and progresses more rapidly in diabetic patients. These patients tend to seek help for manifestations of atherosclerotic disease up to a decade earlier than non-diabetic patients do. Also, diabetic patients with coronary atherosclerosis are more likely to have silent ischaemia, with none of the typical symptoms of angina or chest pain associated with myocardial infarction. There is no evidence, however, that diabetes mellitus increases perioperative cardiac morbidity or mortality. This was proven in a multivariate study of over 6 500 major vascular procedures of all types including



*Fig. 1. Severe ischaemia in the toes of a diabetic with accompanying blistering and necrosis of the skin on the dorsum of the foot. Note the clawing and retraction of the toes with ulcer formation on the 4th and 5th toes.*

## Vascular problems

carotid endarterectomy, aortic aneurysm repair and lower limb bypass.<sup>1</sup> In a separate study involving 800 lower limb bypasses followed for 5 years or more, the hospital mortality rate was 1% and long-term graft patency, limb salvage and patient survival rates were comparable with or better than those for non-diabetic patients treated over the same period.<sup>2</sup>

Age alone is also not a contraindication to arterial reconstruction. Successful vascular intervention is often carried out in selected patients over the age of 90 years if their functional and physiological status belies their chronological age.

The most important difference in treating lower limb vascular problems in diabetics is the location of the stenotic or occlusive lesion. The distal vessels of the lower limb are usually spared in non-diabetics with atherosclerosis, whereas in diabetics these infrapopliteal arteries leading onto the foot are usually the most affected. Surprisingly, the arteries of the foot itself are usually spared in diabetics, making vascular intervention, be it either open surgical bypass or endovascular procedure, a very real option in limb salvage. Those diabetics who smoke often have a combination of both patterns of disease and this complicates the revascularisation procedure.

### **Age alone is also not a contraindication to arterial reconstruction.**

### *Peripheral ischaemia and intervention*

In patients presenting with typical signs and symptoms of peripheral ischaemia, several factors must be taken into account prior to any intervention being undertaken. Patients with a short life expectancy (due to co-morbid conditions or terminal cancer), non-ambulatory or bedridden patients are better served with primary amputation. Extensive necrotising infection that after debridement will no longer provide the patient with a functional foot likewise requires immediate amputation.

In patients presenting with ischaemia and infection, spreading sepsis must be controlled prior to arterial reconstruction. Most infections in diabetics are polymicrobial, and broad-spectrum intravenous antibiotics should be started after cultures have been taken. Prompt

incision and drainage of abscesses as well as the necessary toe, ray or partial forefoot amputation together with the required debridement of non-viable tissue should also be undertaken before revascularisation. Fig. 2 shows a patient with diabetic feet with all of the cardinal signs of deformity, callus formation and ulceration with infection.

### **In patients presenting with ischaemia and infection, spreading sepsis must be controlled prior to arterial reconstruction.**

### *Inflammation in diabetics*

Typical signs and symptoms of inflammation are often diminished or even absent in diabetics due to their blunted neurogenic response. This is why it is so important to probe all ulcers to exclude deep space abscesses and debride non-viable tissue until all visibly thrombosed small veins are removed.

Glycaemic control is probably the most sensitive indicator of improvement and resolving infection and should occur within 3 - 4 days of antibiotic therapy and

debridement. During this time preoperative evaluations prior to revascularisation including duplex Doppler, CT angiography or MR angiography can be carried out.

An extremely important fact to remember in the treatment of the diabetic foot is that dry eschars without signs of infection should only be debrided if arterial reconstruction is planned. Dry gangrene of individual toes should also be left and kept dry until and if reperfusion is done. Debridement or amputation of dry non-infected tissue without prior restoration of pulsatile flow to the foot can lead to an increase in necrosis of tissue and exacerbation of sepsis.

### *Renal function as a complication*

Diabetic patients with compromised renal function or renal failure present a special challenge, both as far as preoperative or diagnostic angiography is concerned, and also with regard to complex interventional procedures such as remote arthroectomy, balloon angioplasty and stenting. The restriction of angiographic contrast volume is always of paramount importance in a diabetic patient undergoing any angiographic procedure, but withholding endovascular intervention when limb salvage is possible, is generally inappropriate and unnecessary. A transient rise in serum creatinine seldom leads to anuria or the need for haemodialysis. With appropriate pre- and post-intervention rehydration, plus the careful placement of interventional diagnostic catheters at the

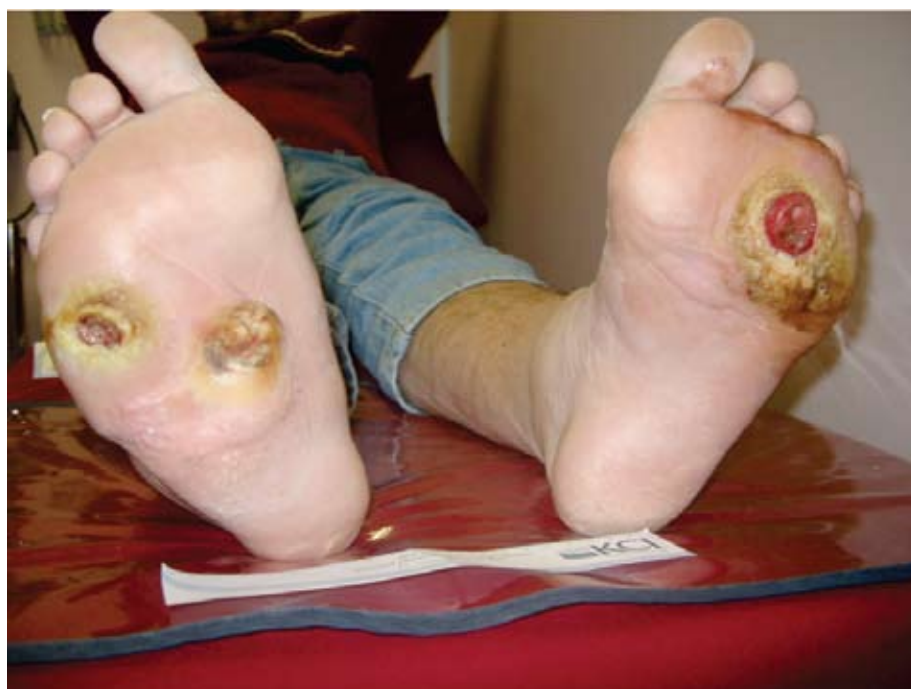

Fig. 2. Diabetic feet with all of the cardinal signs of deformity, callus formation and ulceration with infection.

most distal sites in the arterial tree in order to minimise contrast volume, this group of patients can safely undergo the required endovascular intervention.

**Typical signs and symptoms of inflammation are often diminished or even absent in diabetics due to their blunted neurogenic response.**

*Decision to treat*

Because most diabetics who are referred for vascular assessment already have a non-healing ulcer or gangrene, with or without accompanying sepsis, the decision to treat is not usually based on claudication or rest pain symptoms. In any case, a diabetic patient with severe neuropathy can have no rest pain whatsoever, even with extreme ischaemia of the limb, owing to the complete loss of sensation. Suffice to say, any diabetic in whom pulses are not easily palpable has a critically ischaemic limb until proven otherwise.

The assessment of an ankle brachial index in this patient group is also notoriously inaccurate due to the severe calcification of the infrapopliteal arteries. This may yield artificially elevated values and mislead the inexperienced clinician. In fact, approximately 10% of diabetics have totally non-compressible vessels, making the ankle brachial index incalculable. A more accurate assessment of distal ischaemia is the toe brachial pressure because, as previously mentioned, the vessels on the foot itself are usually spared the extreme calcification of the infrapopliteal vessels. Toe pressures of less than 30 - 50 mmHg are indicative of critical ischaemia. Transcutaneous oxygen pressure, when available, is also a useful tool for assessing the diffusion of oxygen through the skin surface, and can help in deciding levels of amputation in the non-oedematous lower limb.

In experienced hands, the evaluation of waveforms and velocities by means of arterial duplex Doppler provides the clinician with information that can determine whether surgical or endovascular treatment should be pursued. The arterial Doppler together with the

aforementioned factors of co-morbidity and life expectancy can often negate the need for any further invasive tests.

The ultimate goal of vascular reperfusion in the lower limb is the restoration of pulsatile flow to the foot. Every surgical bypass and each endovascular intervention has to establish direct flow through at least one vessel to the foot to meet the criteria for a successful reperfusion.

Iliac artery disease accompanies more distal lower limb disease in approximately 10 - 20% of patients with diabetes. In this case, assessment of inflow disease from the infrarenal aorta to the foot is necessary. It is possible to obtain detailed and complete pictures of the infrarenal aorta to the toes with less than 100 ml of contrast. Balloon angioplasty with or without stenting is almost always an option and will improve inflow for more distal endovascular procedures or surgical bypass.

Intra-arterial digital subtraction arteriography is the most accurate way of assessing the infrapopliteal arterial tree. The entire tree and foot circulation must be visualised. Anterograde femoral artery puncture with placement of diagnostic catheters as far distally as possible restricts contrast volume and ensures filling of distal stenosed and collaterally perfused vessels.

*Bypass grafting*

For more than 50 years, the gold standard for lower limb vascular reperfusion has been the reversed saphenous vein femoro-popliteal or distal bypass. Vein size discrepancy as a result of this reversal, after harvesting, has always been an inherent problem in the procedure. This led to the concept of *in situ* bypass grafting, where the vein was not reversed at all, but vein valves were atraumatically cut, thus allowing for the flow of blood distally down the vein. Another important advance in arterial bypass grafting in diabetics with minimal inflow disease has been the concept of inflow grafts taken from the popliteal artery to more distal locations rather than the traditional location of the common femoral artery. This method shortens the operation time and potentially minimises the risk of wound complications in the thigh and groin area.

When the only possible bypass outflow site is one of the foot arteries, femoro-pedal or popliteal pedal bypass remains the only option. Pomposelli and colleagues published their results of vein bypass grafts to the dorsalis pedis in over 1 000 patients with a follow-up of more than 10 years, and showed a patency rate of 63% with a limb salvage rate of 78%. Even in those

patients with foot infection, placing the vein graft in close proximity to the sepsis did not prove hazardous.<sup>3</sup>

In spite of the successful outcomes in open bypass surgery, less than 50% of patients report feeling that they are back to normal 6 months after surgery. If one considers that 50% of all patients requiring limb salvage therapy survive less than 5 years after their procedure, then endovascular therapy as a treatment in diabetics with lower limb ischaemia must be the first-line therapy of choice. Limb salvage rather than vessel patency becomes more important. Wound healing rather than claudication distance takes precedence. The advent of low-profile balloons and steerable guidewires, as well the creation of stents specifically designed for the infrapopliteal region, now makes angioplasty of distal pedal vessels possible. Recreation of a totally occluded pedal arch is routinely carried out with these new endovascular tools, enabling healing of recalcitrant ulcers to take place with a minimum of recovery time.

**Because most diabetics who are referred for vascular assessment already have a non-healing ulcer or gangrene, with or without accompanying sepsis, the decision to treat is not usually based on claudication or rest pain symptoms.**

A simple algorithm, proposed by Marc Bosiers *et al.*,<sup>4</sup> enables the interventionalist to make the correct choice when faced with the complex atherosclerotic infrapopliteal diabetic arterial tree. Short focal lesions should first undergo percutaneous transluminal balloon angioplasty (PTA). A suboptimal PTA outcome such as flow-limiting dissection or residual stenosis of >50%, should then be addressed with bail-out stenting.



## Vascular problems

Balloon-expandable stents allow for more precise placement at ostial lesions and the high radial force that they exert is ideally suited for the heavy calcified vessels so common in diabetics. However, they do fracture, so strict surveillance and follow-up is of paramount importance. In Fig. 3 an arteriogram of the infra-popliteal trifurcation shows a tight stenosis of the popliteal artery and the tibio-peroneal trunk. After balloon angioplasty and stent the stenosis is no longer present (Fig. 4).

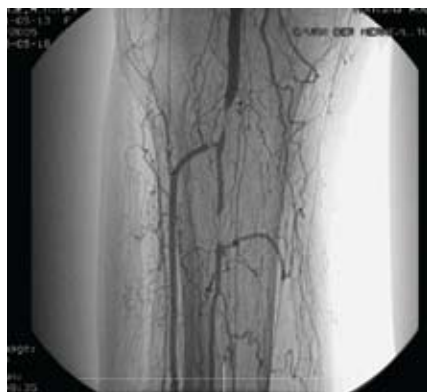


Fig. 3. Arteriogram of the infra-popliteal trifurcation showing a tight stenosis of the popliteal artery and the tibio-peroneal trunk.

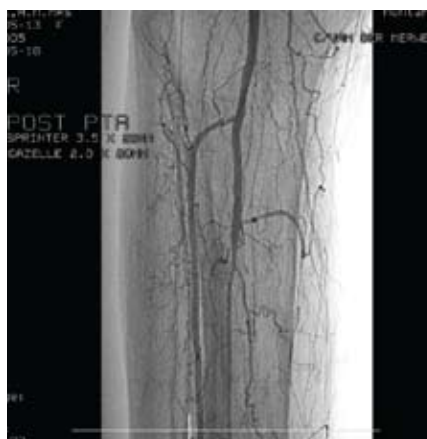

Fig. 4. After balloon angioplasty and stent the stenosis is no longer present.

The advantages of self-expanding stents in the lower limb include excellent crush resistance and extreme flexibility together with an optimal radial force.

Long occlusions, or diffusely calcified lesions, are suitable indications for sub-intimal angioplasty. In patients treated with sub-intimal angioplasty the risk of major amputation is low and the mortality rate is nil. Experienced centres have repeatedly reported primary success rates of 90% and 1-year limb salvage rates as high as 85 - 90%. Five-year primary assisted patency rates of 64% have been reported using this method of recanalisation.

Overall, in fact, percutaneous interventions yield limb salvage rates of 80 - 90%.

It is important to note that there is an inseparability of new endovascular tools and modern wound care. Restoring blood flow is one issue, wound care is another. Specialised wound dressings and vacuum-assisted closure therapy are essential tools in limb salvage. These, together with aggressive endovascular treatment of the infra-popliteal arteries, are the first-line treatment of choice for the ischaemic ulcerated diabetic foot.

## Conclusion

In conclusion, all diabetics with chronic limb ischaemia should be revascularised. However, the final outcome of endovascular intervention in the diabetic patient with foot ulceration is determined by multiple factors. These include

- patient compliance
- patient co-morbidities
- the involvement of a multidisciplinary team
- the location of the ulcer
- the adequacy of blood circulation to that location
- the extent of infection present and the control of infection by means of debridement and/or antibiotics.

An increasingly varied and downsized endovascular 'tool box' is now available to those interventionalists who treat the high-risk diabetic patient group with lower limb ischaemia as a result of complex below-knee lesions. Special crossing and re-entry devices designed for femoro-popliteal and distal application may facilitate recanalisation of long chronic occlusions. Improved stent designs, arthroscopy devices and drug-eluting stents improve patency rates and together with modern wound care applications, result in improved wound healing rates.

## Intra-arterial digital subtraction arteriography is the most accurate way of assessing the infrapopliteal arterial tree.

The optimal revascularisation strategy in diabetic patients with chronic critical limb ischaemia (CLI) remains unclear but it has been shown that diabetics with CLI benefit from early revascularisation. To achieve this benefit,

multiple revascularisation procedures may be required and close surveillance is therefore mandatory. The presence of diabetes should not deter clinicians from attempting revascularisation by means of percutaneous interventions.

The aggressive and systematic approach to diabetic foot disease will result in improved limb salvage among diabetic patients with vascular insufficiency. In numerous studies in both the UK and USA it has been shown that healing foot ulcers in the diabetic population costs the health care system of any country much less overall, in the long term, than amputating the affected foot.

## References

1. Hamdan AD, Salzberg SS, Sheahan M, *et al.* Lack of association of diabetes with increased post-operative mortality and cardiac morbidity: results of 6565 major vascular operations. *Arch Surg* 2002; 137: 417-421.
2. Akbari CM, Pomposelli FB Jr, Gibbons GW, *et al.* Lower extremity revascularisation in diabetics: Late observations. *Arch Surg* 2000; 135: 452-456.
3. Pomposelli FB Jr, Kansal N, Hamdan AD, *et al.* A decade of experience with dorsalis pedis artery bypass: Analysis of outcome in more than 1000 cases. *J Vasc Surg* 2003; 37: 307-315.
4. Bosiers M, Deloose K, Verbist J, *et al.* Why DES may not work for most patients with leg ischemia caused by below knee arterial occlusive disease. *Vascular Disease Management* 2008; 5: 140-142.

## FURTHER READING

- Alexandrescu V, Hubermont G, Phillis Y, *et al.* Combined primary subintimal and endoluminal angioplasty for ischaemic inferior limb ulcers in diabetic patients: 5 year practice in a multi disciplinary 'diabetic-foot' service. *Eur J Vasc Endovasc Surg* 2009; 37(4): 448-456.
- Armstrong D, Lavery L. Diabetic Foot Study Consortium. Negative pressure wound therapy after partial diabetic foot amputation: a multicentre, randomized controlled trial. *Lancet* 2005; 366(9498): 1704-1710.
- Bell P. The management of lower limb ischemia. *J Cardiovasc Surg* 2008; 49(2): 141-143.
- Boulton AJM. The pathway to ulceration: aetiopathogenesis. In: Boulton AJM, Cavanagh PR, Rayman G, eds. *The Foot in Diabetes*, 4th ed. Hoboken, NJ: Wiley & Sons, 2006: 51-67.
- 'Facts & Figures: Did You Know' International Diabetes Federation. Available at <http://www.idf.org>
- Faglia E, Clerici G, Clerissi J, *et al.* Early and five year amputation and survival rate of diabetic patients with critical limb ischemia: data of a cohort study of 564 patients. *Eur J Vasc Endovasc Surg* 2006; 32(5): 484-490.
- Hamden AD, Pomposelli FB jr. Lower limb arterial reconstruction in patients with diabetes mellitus: Principles of treatment. In Levin ME, O'Neil LW, Bowker JH, Pfeifer MA, eds. *The Diabetic Foot*, 7th ed. Philadelphia: Mosby Elsevier, 2008; 429-442.
- International Working Group on the Diabetic Foot. *International Consensus on the Diabetic Foot*. Maastricht, 1999.

Levin ME, O'Neil LW, Bowker JH, Pfeifer MA, eds. *The Diabetic Foot*, 7th ed. Philadelphia: Mosby Elsevier, 2008.

LoGerfo FW, Gibbons GW, Pomposelli FB Jr, et al. Trends in the care of the diabetic foot: Expanded role of arterial reconstruction. *Arch Surg* 1992; 127: 617-621.

Palumbo PJ, Melton LJI. Peripheral vascular

disease and diabetes. In: National Diabetes Data Group, eds. *Diabetes in America*, 2nd ed. (NIH publ. no 495-1468). Washington, DC: US Government Printing Office, 1995: 401-408.

Pomposelli FB jr, Jepsen SJ, Gibbons GW, et al. Efficacy of the dorsal pedis bypass for limb salvage in diabetic patients: Short term observations.

*J Vasc Surg* 1990; 11: 745-751.

Schwarzmaier-D'Assie A, Karnik R, Bonner G, Vavrik J, Slavy J. Fracture of a drug eluting stent in the tibioperoneal trunk following bifurcation stenting. *J Endovasc Ther* 2007; 14: 106-109.

### *In a nutshell*

- In the presence of ischaemia with tissue loss, restore pulsatile flow to the foot whenever possible.
- Ankle brachial indices in the diabetic patient can be falsely elevated or normal even in severe ischaemia.
- A typical neuropathic location of an ulcer alone does not preclude ischaemia as a major contributor.
- Lack of palpable foot pulses is abnormal regardless of how good the Doppler sounds are.
- Drain infections before revascularisation but do not debride dry eschars until revascularisation has been completed.
- Revascularisation is a crucial component of foot salvage, but the responsibility of the vascular surgeon does not end until the foot is healed.