

# Charcot's osteoarthropathy

*An increased awareness of this condition may help in enabling an earlier diagnosis, instituting appropriate treatment, and preventing severe deformity and disability.*

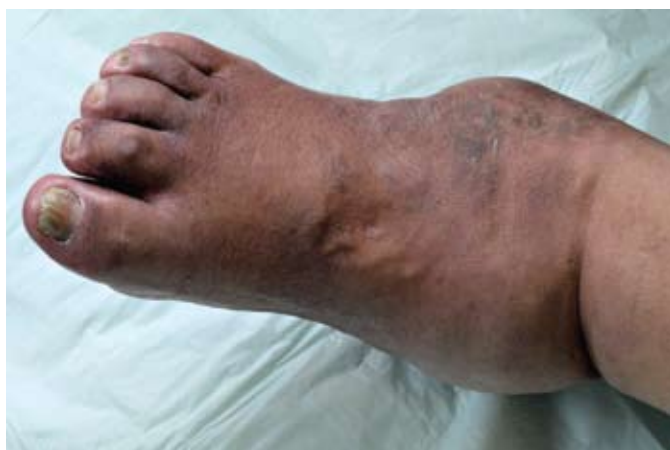**TRACEY JOHNSON, BTech Pod (SA)**

*Podiatrist, Centre for Diabetes and Endocrinology, Houghton, Johannesburg*

*Tracey Johnson has a special interest in the foot in diabetes, with an emphasis on prevention by appropriate patient education and complete foot assessment. She is involved in the Diabetic Foot Working Group and has been chairperson of the South African Podiatry Association.*

*Correspondence to: Tracey Johnson (tracey@cdcentre.co.za)*

Charcot's osteoarthropathy is a devastating, chronic, progressive destruction of bone and joint integrity affecting one or more peripheral articulations. It is characterised by joint dislocation, subluxations and pathological fractures in patients with peripheral neuropathy and results in a debilitating deformity, possibly leading to ulceration and amputation<sup>1</sup> (Fig. 1).



*Fig. 1. Severe chronic destruction and deformity of the ankle because of unrecognised acute Charcot's osteoarthropathy.*

Although the condition was first described in 1831 by the American physician John Mitchell, it bears the name of the 19th century French neurologist Jean-Martin Charcot. The nomenclature of the condition in the literature bears more than 40 different names: Charcot's foot, Charcot's neuro-osteoarthropathy and diabetic neuroarthropathy, to name but a few. While there is no consensus on the most appropriate terminology, resulting in possible confusion in diagnosis and treatment, Charcot's osteoarthropathy appears to be the most acceptable.<sup>2</sup>

Both Mitchell and Charcot observed the condition in non-diabetic patients and it was only much later – in 1936 – that William Jordan linked the condition to diabetes-induced neuropathy. Although neuropathic joint disease has been associated with many other conditions such as tabes dorsalis, chronic alcoholism, leprosy, syringomyelia and spinal cord lesions, it is currently most prevalent in patients with diabetes.

There are no large prospective population studies available. However, reports on the incidence and prevalence vary widely and range between 0.1% and 29%.<sup>3</sup> Occurrence rates are the same in men and women, and type 1 and type 2 patients with diabetes are

at risk. Patients with type 1 diabetes present at a younger age and have a longer duration of diabetes compared with patients with type 2 diabetes.<sup>4</sup>

**In Charcot's osteoarthropathy there is an excessive inflammatory response to minor trauma in which pro-inflammatory cytokines may play a role.**

## *Pathogenesis*

Even though the exact pathophysiological mechanisms and development of Charcot's osteoarthropathy are unknown, multiple factors appear to contribute to the condition (Fig. 2). The most important determinants are peripheral neuropathy with loss of protective sensation, autonomic neuropathy with increased blood flow to the bone, and trauma. However, other causes that are often prevalent in diabetes, such as metabolic factors that tend to weaken bone, renal disease, renal transplantation, steroid-induced osteoporosis and decreased cartilage growth activity, should also be considered.

**In the presence of plantar ulceration, differentiating between Charcot's osteoarthropathy and osteomyelitis is challenging.**

There are two traditional theories concerning the pathogenesis, i.e. the neurotraumatic and neurovascular theories. The neurotraumatic theory emphasises the importance of a loss of protective sensation in allowing progressive destruction of bones and joints because of repetitive mechanical trauma to the foot. In contrast, the neurovascular theory centres on the possibility that there is an inherent weakness in the bones secondary to an altered sympathetic autonomically stimulated vascular reflex that causes hyperaemia and periarticular osteopenia.

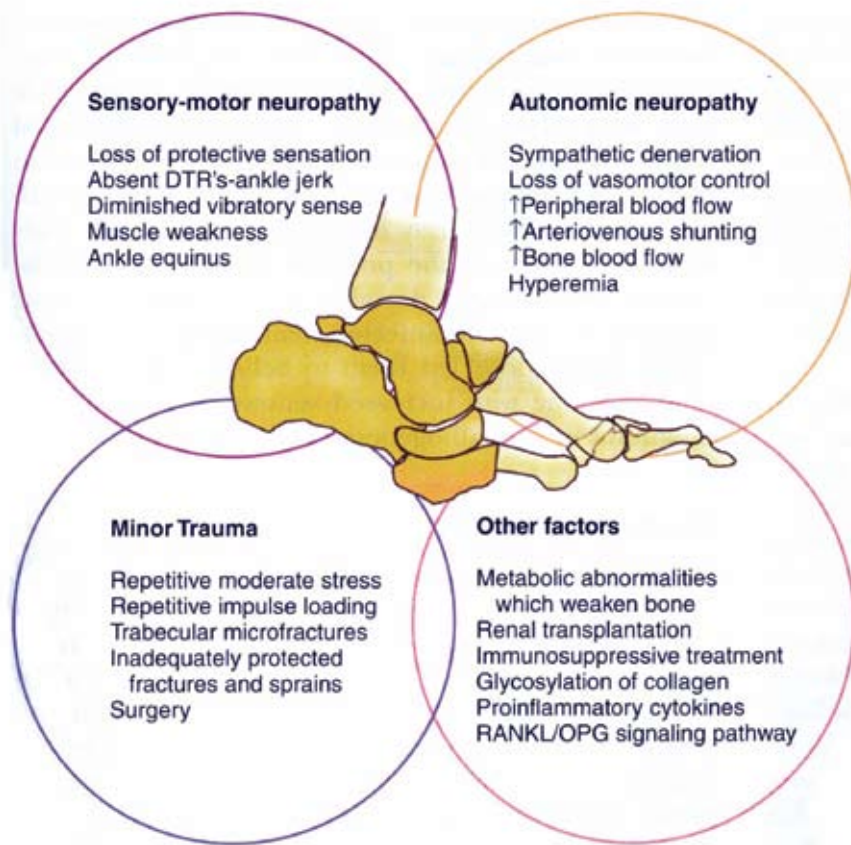


Fig. 2. Pathogenesis of Charcot's osteoarthropathy. (Reprinted from Sanders LJ, Frykberg RG. The Charcot foot (pied de Charcot). In: Levin, O'Neal. Levin and O'Neals The Diabetic Foot. 7th ed. Elsevier, 2007: 257-283. Copyright with permission from Elsevier and the authors.)

However, neither of the above theories, on its own, is sufficient to explain all aspects of Charcot's osteoarthropathy. Explanations are lacking for why the condition tends to be unilateral (when neuropathy is symmetrical), is self limiting (when neuropathy is irreversible) and is rare (when neuropathy is common). In addition, neither theory takes account of the role played by inflammation.<sup>5</sup>

In Charcot's osteoarthropathy there is an excessive inflammatory response to minor trauma in which pro-inflammatory cytokines may play a role.<sup>6</sup> A newer theory is that the receptor activator of nuclear factor KB ligand (RANKL) has been identified as an essential cytokine for the formation and activation of osteoclasts and may play a role in the pathogenesis. RANKL activates the receptor RANK

that is expressed on osteoclasts, thus promoting osteoclastogenesis. RANKL is expressed on bone-forming osteoblasts and therefore bone resorption and bone formation are coupled through RANKL. The effects of RANKL are physiologically counterbalanced by the glycoprotein osteoprotegerin (OPG) that acts as a decoy receptor for RANKL. The balance between RANKL and OPG determines osteoclast functions. Alterations of the RANKL:OPG ratios are critical in the pathogenesis of bone diseases that result from increased bone resorption, and therefore may be important.

### Staging and/or classifications

Charcot's osteoarthropathy may affect the forefoot, the tarsometatarsal joints, the Chopart's or naviculocuneiform joints, and the ankle or subtalar joints, or be isolated to the calcaneus. It rarely involves the knee, although some cases have been reported. While any bone or joint in the foot or ankle can be affected, the majority of cases occur in the midfoot.

Clinical staging or classification can contribute to facilitating communication between professionals, predicting outcome and facilitating treatment. It certainly provides clearer understanding of the disease progression. Eichenholtz,<sup>7</sup> with the most recognised pathological classification, divided the pathological process into the following three radiographically distinct stages: development, coalescence, and reconstruction (Fig. 3). Stage 0, which was added later by Shibata *et al.*, is a prodromal period initiated by trauma but without any significant radiographic findings.<sup>8</sup>

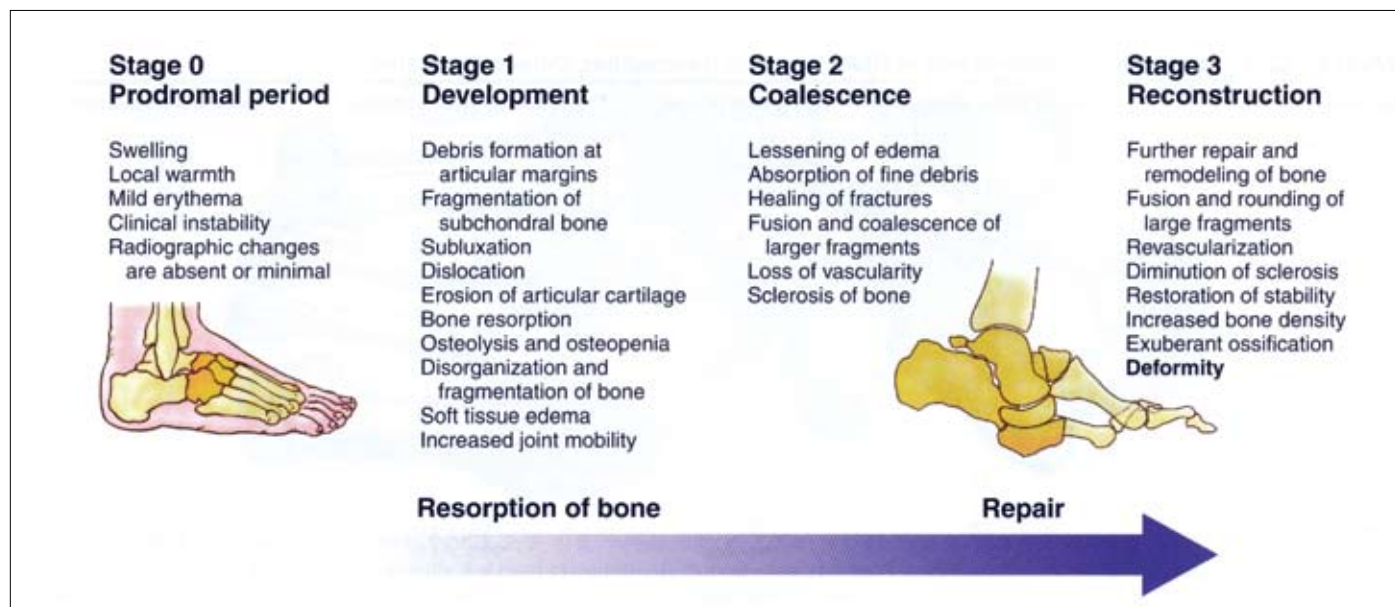


Fig. 3. Staging and classification of Charcot's osteoarthropathy. (Reprinted from Sanders LJ, Frykberg RG. The Charcot foot (pied de Charcot). In: Levin, O'Neal. Levin and O'Neals The Diabetic Foot. 7th ed. Elsevier, 2007: 257-283. Copyright with permission from Elsevier and the authors.)



## Clinical features and diagnosis

Because Charcot's osteoarthropathy remains a poorly understood and frequently overlooked complication of diabetes, it has been postulated that health care professionals regularly involved in the management of patients with diabetes are more likely to encounter and recognise the formidable diagnostic and treatment challenges of pedal neuropathic joint disease. However, for those who seldom see a patient with diabetes this condition is frequently misdiagnosed as gout, posterior tibial dysfunction, infection or even deep vein thrombosis. It often presents without warning and deteriorates rapidly, with ravaging effects. An increased awareness is essential to enable early diagnosis and start appropriate treatment, thereby preventing severe deformity and disability. A high clinical index of suspicion for Charcot's osteoarthropathy must be maintained, until otherwise proven.

**While any bone or joint in the foot or ankle can be affected, the majority of cases occur in the midfoot.**

Acute Charcot's osteoarthropathy is characterised by an erythematous, swollen and warm foot in the presence of neuropathy (Fig. 4).

The patient will usually have bounding pedal pulses, although these may be difficult to locate because of oedema. There may or may not be a history of trauma. While the foot is insensate and generally painless, it is important to note that mild pain and discomfort may be a presenting feature. However, the severity of the pain is significantly less than would be expected, based on the severity of the clinical and/or radiographic findings. Instability and loss of joint function may also be present. Passive movement of the joint may reveal a 'loose bag of bones'.

Dermal thermometry is gaining in popularity to determine temperature differences between limbs. These temperature scanners are relatively inexpensive and quite accurate and practical in diagnosing and treating Charcot's osteoarthropathy. The temperature of the affected limb is often 2 - 8°C higher than that of the contralateral limb. The heat becomes less intense when the inflammation settles.

While the diagnosis should be made by clinical examination, supported by the use of thermometry, further investigations may be useful.

## Investigations

### Radiographic imaging

Baseline radiographs are useful to assist in staging the progression of the condition (Fig. 5). However, it must be stressed that during the acute, prodromal period, the radiographic presentation may be entirely normal. Furthermore, X-rays are neither sensitive nor specific for differentiating between changes due to Charcot's osteoarthropathy and those due to an infection such as osteomyelitis.

In the presence of plantar ulceration, differentiating between Charcot's osteoarthropathy and osteomyelitis is challenging. The definitive diagnosis of Charcot's osteoarthropathy can be made with a synovial tissue biopsy, which will contain shards of bone and cartilage embedded deep into the synovium. A bone biopsy, on the other hand, is used to make the definitive diagnosis of osteomyelitis. These tests are highly invasive and involve considerable risk to the patient.

A less invasive test is available to aid in differentiating between the two diseases. Magnetic resonance imaging (MRI) provides exquisite anatomical detail of both soft tissue and bone, and may describe in more detail the nature of the bony

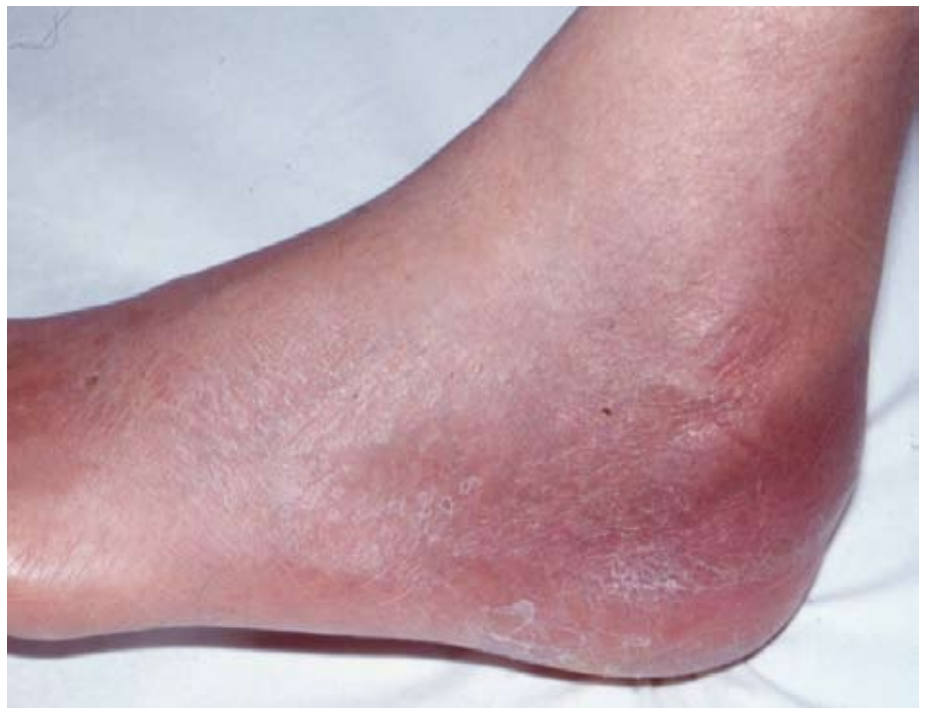

Fig. 4. Typical appearance of acute Charcot's osteoarthropathy on visual examination.

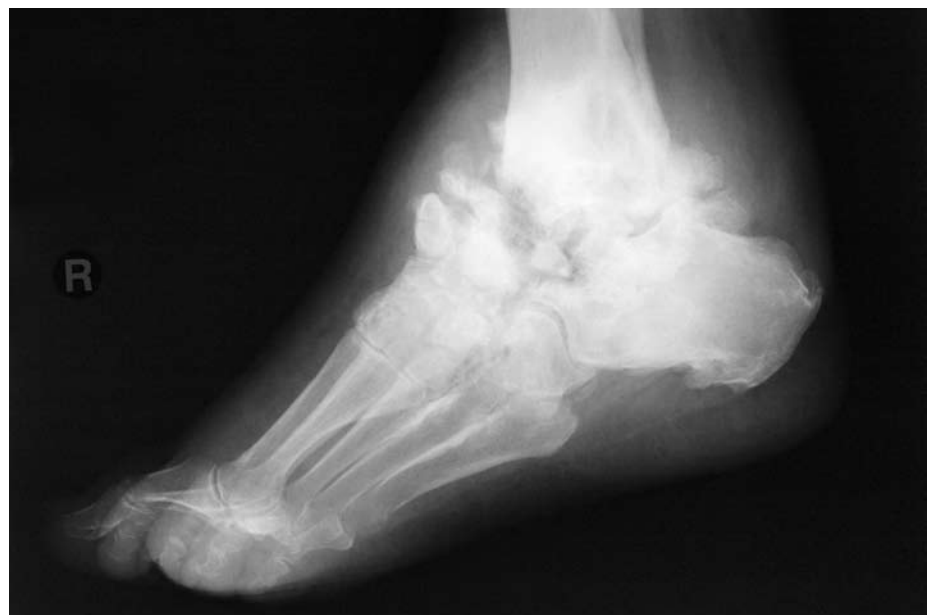

Fig. 5. Plain radiograph revealing chronic destructive effects of Charcot's osteoarthropathy in later stages. There may be no radiographic changes evident in the acute stages of the condition.

damage. MRI abnormalities in the early stages include sub-chondral bone marrow oedema with or without microfracture.<sup>9</sup> This imaging technique can be used to differentiate between osteomyelitis (which produces a high-intensity signal on T2 images) and Charcot's osteoarthropathy (which produces a low-intensity signal on T2 images), but these findings have a low specificity.

### Laboratory studies

Blood tests may not necessarily prove to be useful. Patients are usually afebrile with no clinical or laboratory evidence of infection. Although the local inflammatory response may be excessive, systemic features are often limited. A white cell count (WCC) with differential diagnosis can assist in distinguishing between Charcot's osteoarthropathy and osteomyelitis. The WCC is elevated when infection is present, and infection often reveals a left shift. However, a WCC is a nonspecific marker for inflammation and the results may be elevated in patients with Charcot's osteoarthropathy.

There may be a mildly elevated erythrocyte sedimentation rate associated with a normal WCC. A recent study showed that C-reactive protein was within the normal range in almost 50% of patients presenting with acute Charcot's osteoarthropathy and only moderately elevated in the remainder.<sup>10</sup>

### Treatment considerations

There is no specific treatment to reduce or reverse the destructive changes. The mainstay of treatment of the acute stage is to reduce the inflammation in the bones and reduce the ongoing bone resorption and remodelling to prevent bone destruction and deformity in the long term.<sup>11</sup> The least invasive mechanisms are the most appropriate, with the following goals of treatment:

- to prevent deformity
- to avoid further trauma
- to obtain a plantigrade weight-bearing foot that is able to wear a shoe and avoid excess pressure on the skin, which might lead to ulceration.

A team approach is recommended to prevent patients with these high-risk foot deformities from succumbing to limb loss.

### Non-surgical treatment

Treatment is primarily non-operative. If the condition is diagnosed early, medical and conservative measures will usually suffice.

Surgery is most often reserved for patients with severe or unstable deformities that are not amenable to long-term bracing or footwear therapy alone.

### Immobilisation

Early immobilisation and joint off-loading are critical in the initial treatment of Charcot's osteoarthropathy. The best method of off-loading is non-weight bearing, but it is not always practical.

The total contact cast (TCC) remains the gold standard for prolonged immobilisation. This type of cast is made to conform exactly to the shape of the foot and ankle, with distribution of the pressure over a wide area. The principles of this approach are to control and decrease swelling, provide skeletal stability and protect the soft tissues. The healing process in the foot and ankle of a patient with diabetes takes about twice as long as in a healthy person's limb; therefore, the immobilisation period is lengthy. In general, treatment with non-weight-bearing immobilisation is recommended until the foot becomes quiescent – the mean duration needed is 18.5 weeks. Casting can be discontinued based on clinical, radiographic and dermal thermometric signs of quiescence.

## Early immobilisation and joint off-loading are critical in the initial treatment of Charcot's osteoarthropathy.

Management after removal of the cast includes lifelong protection of the involved extremity. After a TCC is removed, a variety of specialised footwear options is available to continue the healing process and to prevent future deformity. The Charcot's restraint orthotic walker is designed to off-load the foot and distribute plantar pressure more evenly. Patellar tendon braces have also been used to reduce plantar pressure. Custom-moulded shoes and orthotics are also important treatments. These need to be checked regularly to ensure a proper fit.

Patient education regarding the diagnosis, duration of treatment and prognosis is essential. If patients understand the nature of this limb-threatening condition, they may be more motivated to adhere to the treatment plan. Emphasis on total joint off-loading, weight loss and strict glucose

control may improve the outcome of the disease. Preventing further injury, noting temperature changes, checking feet daily, reporting trauma and receiving professional foot care are also important tenets of treatment.

### Antiresorptive pharmacological agents

There is insufficient evidence to support the use of pharmacological therapy in acute Charcot's osteoarthropathy. No agents have yet been formally studied.

However, one of the possible targets for pharmacological therapy is the increased osteoclastic activity that results in decreased bone mineral density that may occur with Charcot's syndrome. Certain drugs currently available have shown 'off-label' promise in observational studies as antiresorptive therapies for acute Charcot's osteoarthropathy. While none is FDA approved for the treatment of Charcot's osteoarthropathy, clinically they have been observed to arrest the acute stages of the condition. These include the bisphosphonates, intravenous pamidronate, and alendronate (Fosamax).<sup>12</sup> Anecdotally, they appear to normalise foot temperatures and reduce urinary markers of bone turnover. Another possible antiresorptive agent is intranasal calcitonin, which inhibits osteoclasts. Health care providers should however be cautious with unregistered use of these agents as they have immunosuppressive properties and could lead to soft-tissue infections.

Future therapies may centre on modulating the balance of OPG and the receptor activator of nuclear kappa-B ligand (RANKL). The exaggerated inflammatory response in acute Charcot's foot has shown over-expression of tumour necrosis factor-alpha (TNF-alpha) and interleukin 1 and 6 (IL-1 and IL-6). In theory TNF-alpha inhibitors, such as infliximab (Revellex) or etanercept (Enbrel), or high-dose corticosteroids, may halt the inflammatory process.<sup>13</sup>

### Surgical therapy

Surgical intervention in acute Charcot's osteoarthropathy is controversial. Some clinicians advocate surgery only when conservative measures have failed, whereas others propose early surgical intervention for improved outcomes. Patients treated with surgery have longer healing times, and the generally accepted rationale is to steer well clear of surgery in the acute stages.

Failure of conservative treatment to properly address chronic recurrent ulcerations, bony deformities, unstable

joints, a non-breakable and 'unshoeable' ankle and foot, acute displaced fractures and malalignment are indications for the surgical reconstruction of Charcot's osteoarthropathy of the ankle and hindfoot. Because of the nature of the existing disease process there may be further breakdown and continued progression of the deformity. Arthrodesis, or joint fusion, is the most common surgical procedure used to treat diabetes-related foot deformities. Other surgical procedures include exostectomy of bony prominences, osteotomy, partial tarsectomy, and Achilles tendon lengthening.

#### References

- Jude EB. Charcot foot: What's new in pathogenesis and medical management? In: Boulton AJA, ed. *The Foot in Diabetes*. 4th ed. John Wiley & Sons Ltd, 2006: 265-273.
- Foster A. *The Diabetic Foot*, Autumn 2005.
- Frykberg RG, Belczyk R. Epidemiology of the Charcot foot. *Clin Podiatr Med Surg* 2008; 25(1): 17-28.
- Petrova NL, Foster AVM, Edmonds ME. Difference in presentation of Charcot osteoarthropathy in type 1 compared with type 2 diabetes. *Diabetes Care* 2004; 27: 1235-1236.
- Jeffcoate W. Charcot neuro-osteoarthropathy. *Diabetes Metab Res Rev* 2008; 24 (Suppl 1): S62-S65.
- Jeffcoate WJ, Game F, Cavanagh PR. The role of proinflammatory cytokines in the cause of neuropathic osteoarthropathy (acute Charcot foot) in diabetes. *Lancet* 2005; 366: 2058-2061.
- Eichenholtz SN. *Charcot Joints*. Springfield: Charles C Thomas, 1966.
- Shibata T, Tada K, Hashizume C. The results of arthrodesis of the ankle for leprotic neuroarthropathy. *J Bone Joint Surg* 1990; 72A: 749-756.
- Chantelau E, Richter A, Schmidt-Grigoriadis P, Scherbaum WA. The diabetic Charcot foot: MRI discloses bone stress injury as trigger mechanism of neuroarthropathy. *Exp Clin Endocrinol Diabetes* 2006; 114: 118-123.
- Petrova NL, Moniz C, Elias DA, Buxton-Thomas M, Bates M, Edmonds ME. Is there a systemic inflammatory response in acute Charcot foot? *Diabetes Care* 2007; 30: 997-998.
- Jude EB. Charcot foot: what's new? *International Diabetes Monitor* 2007; 19(1): 21-27.
- Jostel A, Jude EB. Medical treatment of Charcot neuroosteoarthropathy. *Clin Podiatr Med Surg* 2008; 25(1): 63-69.
- Jeffcoate WJ. Theories concerning the pathogenesis of the acute Charcot foot suggest future therapy. *Current Diabetes Report* 2005; 5(6): 430-435.

### In a nutshell

- Diabetes mellitus is the most prevalent cause of Charcot's osteoarthropathy in the 21st century.
- The exact pathophysiology is unclear and speculative, although a loss of protective sensation, autonomic neuropathy and trauma are the most important determinants.
- Charcot's osteoarthropathy should be suspected in any patient with diabetes and long-standing neuropathy presenting with a warm swollen foot without local or systemic signs of infection.
- If initially unsure about the diagnosis, treat for Charcot's osteoarthropathy until proven otherwise.
- Plain X-ray presentation in the early stages may be completely normal and should be followed up with magnetic resonance imaging (MRI).
- Early recognition of Charcot's foot and immobilisation with gold standard total contact casting can minimise potential foot deformity, ulceration, and loss of function.
- The goal is to keep the patient immobilised and bearing no weight until the disease progresses to the chronic stage, which is signified by a decrease in pain and swelling and radiographic signs of resolution.
- Surgical intervention in the acute stage is considered unacceptable and should be reserved for failure of conservative therapies.

### Single suture

## Light drinking linked to slower weight gain for middle-aged women

Middle-aged women who reported a light or moderate alcohol intake were less likely than non-drinkers to become overweight or obese during a 13-year study. Nearly 20 000 female health care workers had a normal body weight when recruited to the Women's Health Study in the early 1990s. The cohort gradually gained weight over the next 13 years – 41.3% (7 942/19 220) became overweight and 3.8% (732/19 220) became obese. The authors modelled their self-reported drinking habits against risk of weight gain and found a clear and significant trend – those who drank most gained least, up to a threshold of around 30 - 40 g of alcohol a day (3 half-pints of beer or 3 small glasses of wine). After extensive adjustments to account for the different lifestyles and diets of women who drink more or less alcohol, the relative risks for becoming overweight or obese fell from 1.00 for non-drinkers to a low of 0.78 for the small number of women who drank at least 30 g alcohol a day. The link survived sensitivity analyses and seemed the same for women of all ages.

The authors can't confidently explain their findings, although others have reported similar associations in female nurses. The evidence so far points to a distinct difference between the sexes. Alcohol is generally associated with weight gain in men, possibly because they drink on top of their usual dietary intake. In this study, as in others, women who drank more tended to eat less.

Wang L, et al. *Arch Intern Med* 2010;170: 453-461.