

MORE ABOUT... HIV-RELATED SURGERY

Vascular disease in HIV/AIDS

RG BOTHA, MB ChB, DA (SA),
MMed (Surg), CVS (SA)

Consultant Vascular Surgeon, Department of Surgery, Faculty of Health Sciences, University of the Free State

Correspondence to: plkargb.md@ufs.ac.za

The well-documented relationship between vascular disease and HIV infection has evolved from infectious and inflammatory vasculitides to:

- premature atherosclerosis
- its related contributing conditions (metabolic syndrome, dyslipidaemia, insulin resistance syndrome) and
- complications (acute coronary and cerebrovascular syndromes).¹

Triple antiretroviral therapy ensures adequate viral suppression, which is paramount to the successful clinical management of HIV-infected patients. The associated metabolic effects as well as the increased longevity associated with these drugs increase the cardiovascular manifestations, which should be prevented and treated.

Perioperative risk assessment and reduction

The American Heart Association (AHA) 'Initiative to Decrease Cardiovascular Risk and Increase Quality of Care for Patients Living with HIV/AIDS'² concluded that metabolic and anthropometric abnormalities contribute to cardiovascular disease risk. These abnormalities may be due to HIV or its therapy and may be affected by environmental and immunological factors with the net effect of being pro-atherogenic.

The Pavia consensus statement³ brought the following important aspects to attention:

- HIV infection may directly cause cardiovascular disease
- HIV therapy may cause cardiovascular disease
- HIV therapies may interact with drugs used for cardiovascular complications
- Primary prevention of coronary heart disease in patients receiving antiretroviral therapy includes exercise, diet and treatment of hyperlipidaemia, hypertension and glucose intolerance.

Peripheral arterial occlusive disease (PAOD) in HIV-infected patients

Van Marle reported the classic risk factors for PAOD to be less prevalent in their studied HIV population. Patients were also of younger age than expected at presentation.⁴ Three clinical syndromes may present:

Atherosclerotic disease

Contributing risk factors are:

- disease specific (metabolic syndrome, dyslipidaemia, insulin resistance syndrome, antiretroviral therapy, i.e. protease inhibitors) or
- due to a high prevalence of the traditional risk factors for atherosclerosis in this population.

Future research has to determine whether HIV infection and antiretroviral therapy contribute independently to increased cardiovascular disease.^{1,2}

Non-atherosclerotic disease

- Infectious arteritis (CMV, varicella zoster virus, mycobacterium and fungal infections)
- inflammatory vasculitis (leucocytoclastic vasculitis),⁵ polyarteritis nodosa (PAN),

Henoch-Schönlein purpura, drug-related hypersensitivity vasculitis, temporal arteritis/polymyalgia rheumatic and nonspecific unclassified vasculitis) and

- microvascular changes (thrombotic purpura (TTP) and haemolytic uraemic syndrome).¹

Prothrombotic state

An increased prothrombotic state is observed in HIV patients with active opportunistic infections or malignancy and in patients with AIDS. The potential mechanisms proposed are the presence of antiphospholipid antibodies, such as anticardiolipin antibodies and lupus anticoagulants, and also increased levels of von Willebrand factor, fibrinogen and D-dimers as well as deficiencies of protein C, protein S, antithrombin III, heparin cofactor II and increased platelet activation.

Thus, the multifactorial pathogenesis may explain the peculiar characteristics and features of HIV-associated occlusive vasculopathy (Table I).

Aneurysms in HIV-infected patients (Fig. 1)

The pathogenesis is uncertain. It is commonly associated with, but not exclusively due to, a leucocytoclastic vasculitis. This process results in obliteration of the vasa vasorum and transmural necrosis. Infective aetiologies are a sporadic rather than a consistent finding.

Unlike degenerative aneurysms, these are found in atypical sites (common carotid and superficial femoral artery) with a saccular/multi-loculated morphology and tend to be multiple. Low CD4 counts as well as hypoalbuminaemia are consistent findings with prognostic implications.^{11,12}

Table I. Characteristics and features of HIV-associated occlusive vasculopathy

Young age at onset of disease (mean age 40 yrs)^{6,7}

Most patients present with advanced vascular disease (>50% critical limb ischaemia)²

Smoking is a common traditional risk factor⁴

CD4+ T cell count <200 cells/ μ l⁷

Hypo-albuminaemia is a reliable predictor of increased perioperative complications and poor long-term survival⁴

Infra-inguinal disease more often than aorto-iliac occlusive disease⁴

Macroscopic findings

Normal arteries proximal,⁸ and the occlusion is of a fibro-obliterative nature with cords/strings of fibrous tissue which can be removed from the arterial lumen⁴

Arteriographic findings

Pristine proximal arteries with extensive disease extending into the small and medium-sized arteries with poor run-off^{5,8,9}

Duplex ultrasonographic findings

Hyperechoic 'spotting' in the arterial wall, the 'string of pearls sign'¹⁰

Prognosis

Limb salvage rate 27%⁸

Wound sepsis

Graft sepsis

Perioperative mortality 6.95%

Late mortality 28.75%

HIV therapies may interact with drugs used for cardiovascular complications.

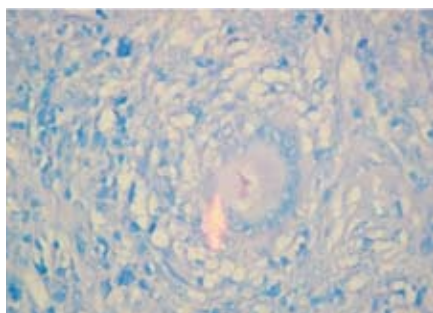


Fig. 1. Histology of an aorta aneurysm in an HIV-infected 40-year-old woman. The slide reveals granuloma formation as well as a TB bacillus in the wall of the aneurysm.

As for management, the same principles as in the case of other infected aneurysms apply, although aneurysm as well as patient factors may influence the definitive therapy of each.

Venous thromboembolism

In addition to classic risk factors, HIV-infected persons have additional predictors for the development of venous thromboembolic events (VTEs). VTEs are 2 - 10 times more common among HIV-infected persons compared with the general population, with incidence rates of 1.9 - 7.6 per 1 000 person-years and a median age of 37 years.¹³

Additional risk factors for VTE in HIV-infected patients are listed in Table II.

Table II. Additional risk factors for VTE in HIV-infected patients

Infection by HIV itself – low CD4 cell counts and high HIV viral loads ¹³
Thrombophilic abnormalities: antiphospholipid and anticardiolipin antibodies, decreased activities of natural anticoagulants, especially protein S, and increased platelet activation ¹
Endothelial lesions: thrombotic microangiopathy (TMA) also occurs at elevated rates among patients with HIV ¹³
An active infectious process – infections may lead to activation of endothelial cells and a procoagulant state ¹³
HIV-associated malignancies (e.g. Kaposi's sarcoma)
Inflammatory and/or dysmetabolic states

A recent retrospective review found that the current use of antiretroviral therapy, the duration of therapy and the percentage of time with HIV on therapy were not different among those with and without a VTE.¹³

The 2008 American College of Chest Physicians guidelines make no reference to the HIV-infected patient suffering from VTE. Veller and Eyal recommend prophylaxis along the same guidelines as those for a patient suffering from cancer and standard treatment protocols for patients with proven VTE.¹⁴

References available at www.cmej.org.za

HIV-related anal disease

E J THERON, FRCS (Edin)

Emeritus Professor of Surgery/Consultant/Reader/Training Co-ordinator, Department of Surgery, University of the Free State, Bloemfontein

Correspondence to: E J Theron (mwetrone@mweb.co.za)

Anal disorders are very common in HIV-infected patients. It is estimated that at least one-third of HIV-positive patients suffer from an anal disorder and that anorectal disease is the most common reason for surgical referral and intervention in these patients.¹

It is therefore imperative that all patients presenting with anal disorders should be tested for HIV, and conversely that all seropositive patients be questioned and if necessary examined for the presence of anorectal disease.²

Clinical presentation

The primary care physician should be acutely aware of the symptoms and signs that may become apparent; these should be kept in mind and actively looked for. Pain (proctalgia) or severe discomfort is the most common presenting symptom (55 - 60%), followed by a mass or swelling (>28%).¹ Blood or bloodstained discharge is often associated with these symptoms or could be the single presenting symptom in up to ≥20% of cases. Other presenting complaints include pruritus, painful defecation, incontinence and diarrhoea. Any symptom with regard to the anal area in an HIV-positive patient should be investigated and assessed thoroughly.

Pathology

In order to assess any of the above in an orderly and scientific manner, the pathology affecting the anal area should be considered (Table I).

Condyloma acuminatum (human papillomavirus) is the most common finding (40 - 50%) in many series, followed by peri-anal ulcers (32%), fistula-in-ano (30%), anal fissures (30%), sepsis and abscesses, complicated haemorrhoids and proctocolitis. Inflamed skin tags and hypertrophied/infected anal papillae are often associated with many of the abovementioned findings in the HIV-positive patient.³

Table I. Anal disorders in HIV-positive patients (most often found in combination)

Disorder	Average incidence (%)
Proctitis/skin involvement	40
Condylomata acuminata	43
Fissure-in-ano	30
Anal ulcer	29
Haemorrhoids	15
Chlamydia/gonorrhoea	2
Kaposi's sarcoma	2
Squamous cell carcinoma	1

Anal incontinence and soiling is a socially unacceptable and often devastating problem associated with anal disease in AIDS.

The higher prevalence of malignant disease in these patients should also be kept in mind, i.e. Kaposi's sarcoma of the anal canal skin, Hodgkin's lymphoma and possibly squamous cell carcinoma.⁴

Clinical approach

History

A careful history of the main complaint, all symptoms associated with the anal area, and function and anatomy of the anus should be obtained in an objective, formal yet sympathetic fashion. Patients are reluctant to divulge details and may have to be gently prompted to obtain an adequate picture of the pathology and altered function involved. Questions on sexual practices and particularly anal intercourse can sometimes be embarrassing to both patient and physician. Matter-of-fact queries with regard to pain during anal intercourse will afford the patient the opportunity to deny or admit to such practice; subsequent response to questioning may then follow spontaneously.

Keeping in mind the possible pathology, sensitively formulated leading questions will often clear doubts regarding the problem to be managed and its intensity.

Local examination

Most patients can be examined in a consulting room or clinic cubicle. Privacy, nursing/assistant support and good lighting are basic requirements, as well as anaesthetic jelly, swabs, lubricant, a proctoscope, malleable probes and suctioning equipment. Facilities for needle, forceps and open biopsies should be available and a bi-valve speculum for vaginal examination in female patients should always be at hand. Positioning is very important: in addition to the usual Sims' position (left lateral knee flexed), the knee-chest (jack-knife) position can be practical.⁵

In a limited number of patients the above approach will not be possible because of age, non-compliance and pain. An examination under general anaesthesia should then be

More about...

done. Look for pathology that should be expected, i.e. skin lesions, condylomata, abscesses and sepsis, proctitis, small perianal fistulas, fissures, infected thrombosed haemorrhoids and sphincter tone. Anal canal ulcers and multiple fissures may be missed, and associated rectal disease should be identified. In advanced destructive anal disease of fully fledged AIDS the findings may be confusing because of the presence of multiple pathology, and a descriptive clinical assessment should be made (Figs 1-6).

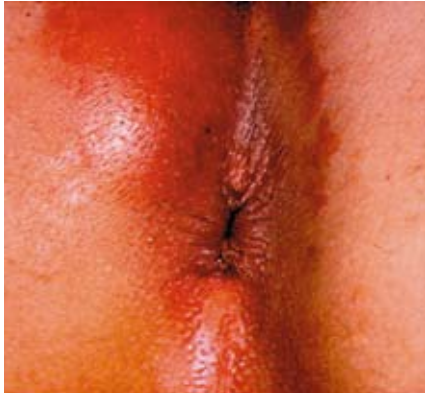

Fig. 1. Perineal abscess.

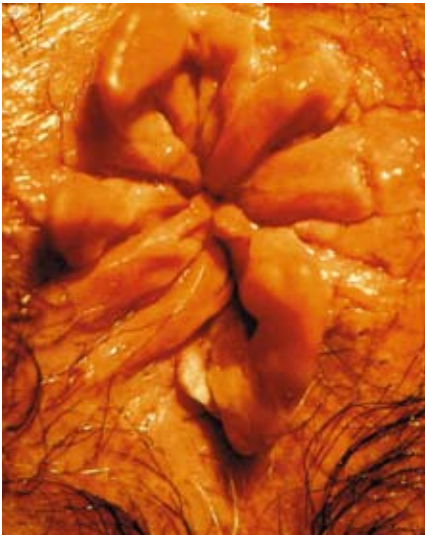

Fig. 2. Hypertrophied anal papillae.

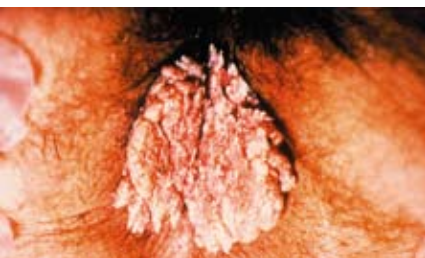

Fig. 3. Condylomata acuminata.

It may be necessary to perform proctosigmoidoscopy, either of the rigid or preferably of the flexible variety, to exclude or confirm the presence of associated rectosigmoid disease.

Appropriate special investigations such as MCS, histology and ultrasonography of the

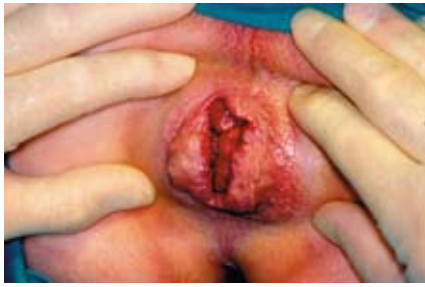

Fig. 4. Acute proctitis.

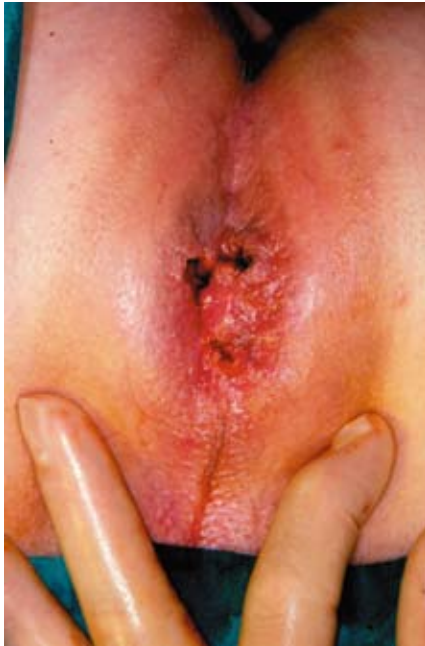

Fig. 5. Anal canal tissue breakdown.

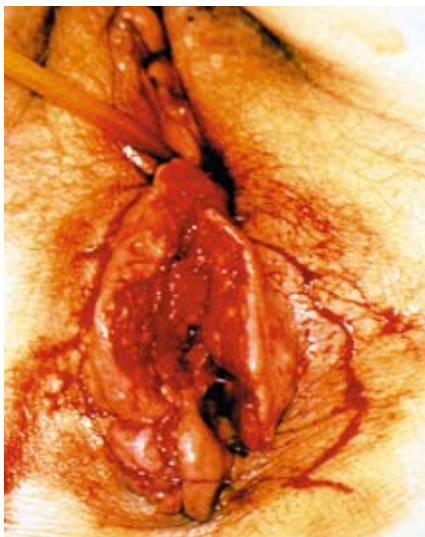

Fig. 6. Squamous carcinoma.

anal canal should be available to come to a final diagnosis.

The presenting symptoms of anal disease in HIV-positive patients in order of prevalence are the following:

- pain
- soiling
- lump/tumour
- blood/pus in stool
- diarrhoea/tenesmus.

Be careful not to hurt the patient or to cause further harm. Every clinical finding during the physical examination should be fully investigated and adequately documented in the patient's file.⁵

Management

Protection of the clinician and all nursing and other staff, including students, should be a priority. Gloves, masks and/or a visor must be used.⁵

Surgical intervention in the treatment of anal disease, e.g. haemorrhoidectomy, should be carefully considered in the HIV-positive patient because of delayed wound healing and even non-healing. According to some, the use of surgery should be limited to the drainage of pus. Disease in this area is usually more aggressive and persistent, and the recurrence rate of resected condylomata has been reported to be as high as 50% within 3 months.³ Peri-anal necrosis and necrotising fasciitis after surgery is a dire and often fatal complication.

In spite of the above, recent reports have been more positive regarding healing and cure rates after surgery. Acceptable results are reported with most interventions and an 'appropriately aggressive approach'¹ seems justified.

It is however very important that surgical intervention be restricted to conditions that require surgery as a matter of urgency and in which conservative management is deemed inadequate. Therefore, a haemorrhoidectomy on uncomplicated haemorrhoids would be contraindicated in the HIV-positive patient, while abscesses, active infected fistulas, anal ulcers, complicated haemorrhoids and extensive condylomata are important when considering surgery. Patients on antiretroviral therapy generally respond well. Satisfactory wound healing and eventual cure usually follow meticulous surgical technique and follow-up in more than 80% of cases.¹ Patients scheduled for surgical intervention must be on effective antiretroviral therapy; a low CD4 count (<200 μ l) and a high viral load may lead to poor or no healing of surgical wounds.

Careful selection of patients for surgery, gentle tissue-saving techniques and meticulous postoperative follow-up should result in a positive outcome.

Every patient's needs should be individualised and potential life-threatening complications of a conservative approach should be weighed against the 20% chance of poor results and non-healing after surgery.

References available at www.cmej.org.za

Soft-tissue tumours and HIV/AIDS

N PEARCE, MB BCh, MMed (Surg), FCS (SA)

Consultant, Department of General Surgery, University of the Free State, Bloemfontein

Correspondence to: N Pearce (nic.pearce@mweb.co.za)

Soft-tissue sarcomas are a diverse group of malignancies, with the majority originating from the mesoderm. The mesoderm accounts for approximately 75% of the body's mass but only for about 1% of tumours in the adult population. Approximately 43% arise from the extremities and the remainder from various other anatomical sites.¹

With the advent of increasingly available antiretroviral drugs, patient life expectancy is increasing and so is the incidence of previously rare conditions, such as Kaposi's sarcoma and lymphoma.

Risk factors

There are certain well-defined risk factors, including ionising radiation, chromosomal abnormalities, chemical exposure and lymphoedema. Some sarcomas have an increased incidence in the HIV population, notably Kaposi's sarcoma and various lymphomas.

Epstein-Barr virus is associated with smooth-muscle tumours in patients with HIV.²

The most commonly used staging system is based on the AJCC (American Joint Committee on Cancer) guidelines. The AJCC guidelines combine various factors, i.e. tumour grade, tumour size, depth of invasion, degree of nodal involvement and presence or absence of metastatic disease.³

Examination

Examination often reveals very few abnormalities, but the following factors indicate an increased risk of malignancy and should be actively sought and noted in patient records:⁴

- pain
- function loss
- neurovascular bundle invasion
- >5 cm in size
- located deep to the fascia
- systemic symptoms
- metastasis
- recurrence
- increased vascularity, i.e. warm.

Biopsy

A mass that has been present for more than 4 weeks or is greater than 5 cm in diameter is an indication for a biopsy. Core needle biopsy (e.g. Tru-cut needle®) has been shown to be accurate with regard to sensitivity and specificity. Fine needle

aspiration should be avoided, as this does not allow grading or histological typing. Incision biopsies have a potential to seed cancerous cells and should be done by the surgeon who takes responsibility for the final surgical management of the tumour, if possible.

Therapy

In the past amputation was considered to be the only option for treating soft-tissue tumours of the extremities. Currently, excision with a margin of at least 1 - 2 cm is considered adequate. Compartment excisions have shown to be of no greater benefit than wide local excisions. Excision with clear margins yields recurrence rates of between 12% and 31%.

Kaposi's sarcoma

This particular disease represents the most common tumour in the HIV population. As stated above, with an increasing life expectancy the prevalence of Kaposi's sarcoma is increasing.

Four clinical variants are described:⁵

- classic/sporadic/Mediterranean
- endemic African
- organ transplant associated
- epidemic (AIDS related).

There exists a theory of multiple infectious events. Kaposi's disease has been shown to be related to Kaposi's sarcoma-related herpesvirus (KSRHV) or herpesvirus type 8.⁶

The diagnosis is primarily clinical, with characteristic lesions that are not painful and usually located on the extremities. Lymphoedema occurs secondarily to the obstruction of the lymphatics. A Zimbabwean study revealed that most patients present in the late stages of AIDS (stages 3 and 4).

A histological diagnosis should be made before initiating therapy, but it bleeds. However, it should be borne in mind that the disease is not curable and one should aim to:

- alleviate symptoms
- reduce the tumour mass
- reduce the oedema
- prevent disease progression.

Treatment can be broadly grouped into two groups:

Treatment targeting lymphoedema:

- elevation of the limb
- exercise
- multilayer bandages
- compression stockings
- manual lymphatic drainage.

Treatment targeting the disease:

- radiation
- antiretroviral therapy
- chemotherapy – this may suppress an already depressed immune system.

Epstein-Barr virus-associated smooth muscle tumours (EBV-SMT)

Patients presenting with EBV-SMT seem to have a significantly low CD4 count, with tumour locations ranging from the central nervous system to the endocrine organ systems. Management must be tailored to the location of the tumour, but most tumours can be managed by surgical excision. EBV-SMT has a slow disease progression; however, optimal treatment still seems to evade us.⁷

Non-Hodgkin's lymphoma has not been discussed above, but should be noted, both because its incidence increases in the HIV-positive population and because it can present as a soft-tissue mass. Lymphoma is not classified by the WHO as a soft-tissue tumour.⁸

References available at www.cmej.org.za

Male genital disease in HIV and AIDS

SCHALK W WENTZEL, MB ChB, MMed (Urol)

Professor and Head, Department of Urology, University of the Free State, Bloemfontein

Correspondence to: S W Wentzel (wentzels@ufs.ac.za)

The first case of acquired immune deficiency syndrome (AIDS) was described in 1981.¹ In the past 29 years the number of AIDS cases has increased at a rapid pace and in 2004 it was estimated that 34 - 42 million people were living with HIV infection.²

The situation is even worse in sub-Saharan Africa, where in 2003 it was estimated that 25 million people were living with HIV infection. A suspected 3 million new cases and 2.2 million deaths due to AIDS were reported that year.³

The three modes of transmission of HIV are: unprotected intercourse, contact with blood, and mother-to-child transmission. There are several urological risk factors involved in the transmission of HIV.

Urological risk factors in HIV transmission

- Sexually transmitted infections (STIs). All STIs have a similar mode of transmission and there is evidence that genital ulcers and non-ulcerative STIs facilitate HIV transmission.⁴
- Antiretroviral therapy and genital secretions. Although patients on antiretroviral treatment may have lower HIV levels in their blood, sexual transmission may still be possible.⁵
- Circumcision status. Uncircumcised men have an increased risk of infection by way of STIs and HIV.⁶
- Specific sexual behaviour. Male-to-female

More about...

transmission is more prevalent than vice versa.⁷ In anal intercourse the insertive partner is less likely to contract HIV than the receptive partner.

Male genital manifestations of HIV infection

HIV can present in different forms in the male urogenital tract. The different manifestations are summarised in Table I.

Table I. Male genital manifestations of HIV

Non-malignant conditions

- Sexually transmitted infections
 - Genital herpes simplex virus (HSV)
 - Human papillomavirus (HPV)
 - Syphilis
 - Chancroid
 - Urethritis
- Molluscum contagiosum
- HIV-related genito-urinary tract infections
- Prostatitis
- Epididymitis and orchitis
- Necrotising fasciitis (Fournier's gangrene)

Neoplasms

- Kaposi's sarcoma (KS)
- Non-Hodgkin's lymphoma (NHL)
- Squamous genital cancers
- Testicular cancer

Sexually transmitted infections

Genital herpes simplex virus (HSV)

HSV types 1 and 2 are very common in HIV-infected men.⁸ The course of the infection may be prolonged and intravenous acyclovir may be necessary to cure the lesions. Patients with acyclovir-resistant HSV have been described and need treatment with foscarnet or topical cidofovir gel.

Human papillomavirus (HPV)

Warts (condylomata acuminata) are found on the penis, urethra, scrotum and perineum.

Other clinical presentations of HPV include bowenoid papulosis and epidermodysplasia verruciformis. Men with extensive penile warts should be screened for HIV.

Syphilis

There is a high prevalence of syphilis in HIV-infected populations, especially homosexual men.⁹ It progresses faster from secondary to tertiary syphilis in HIV-infected men, who, with early syphilis, have a high risk for the development of neurological complications and treatment failure of standard regimens.

Chancroid

Chancroid, caused by *Haemophilus ducreyi*, is a co-factor for HIV transmission. Chancroid in HIV-infected individuals may be resistant to standard regimens. Ulcers heal more slowly and prolonged courses of treatment may be needed.

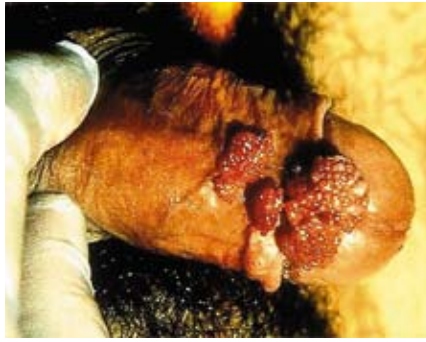

Fig. 1. Condylomata acuminata on the glans penis and foreskin.

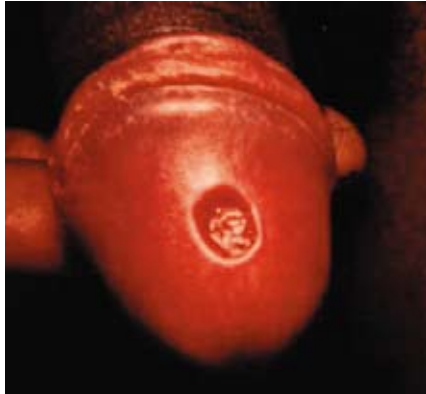

Fig. 2. Chancro caused by syphilis on the glans penis.

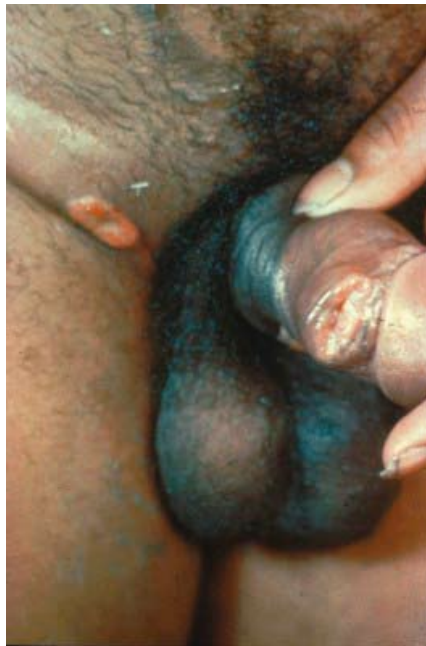

Fig. 3. Chancroid (*Haemophilus ducreyi*).

Urethritis

Patients with HIV have a high risk for the development of urethritis caused by *Neisseria gonorrhoeae* and *Chlamydia trachomatis*. There is a link between AIDS and Reiter's syndrome¹⁰ (urethritis, uveitis and arthritis), but the association is poorly understood.

Molluscum contagiosum

It is caused by a sexually transmitted pox virus and is found in 10 - 20% of AIDS patients, most often on the face and genital areas. The lesions can become very large and

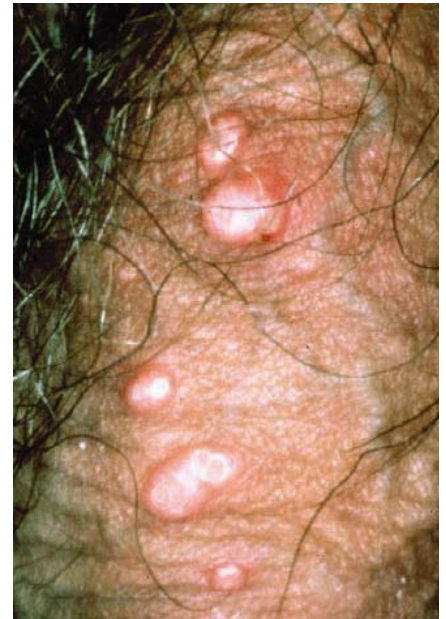

Fig. 4. Molluscum contagiosum on the penis.

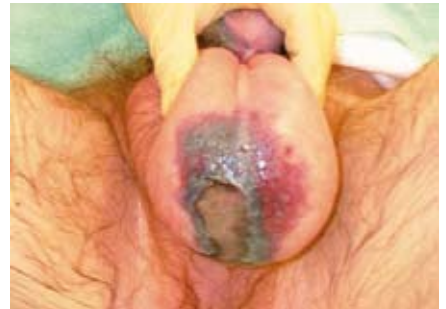

Fig. 5. Typical picture of Fournier's gangrene.

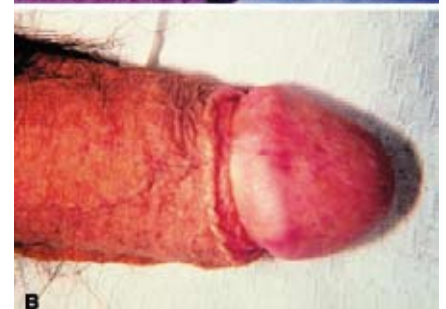
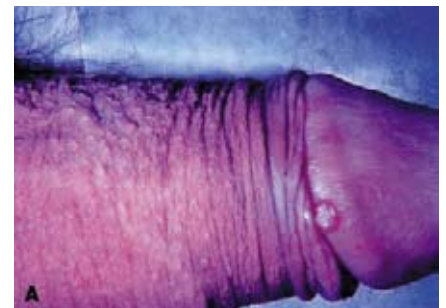
Fig. 6. Kaposi's sarcoma of the penis.

widespread in AIDS patients.¹¹ HIV-infected patients with molluscum contagiosum usually have a CD4 count of less than 250 cells/ μ l. Molluscum contagiosum lesions may simulate more serious infections, such as cutaneous pneumocytosis, histoplasmosis and cryptococcosis, and should be confirmed by biopsy.

HIV-related genito-urinary tract infections

Prostatitis

It is found in up to 8% of HIV patients¹² and presents as acute prostatitis. It can be associated with superimposed urinary tract infections.

Epididymitis and orchitis

In autopsy studies 39% of AIDS patients have signs of opportunistic testes infections. Infections usually cause atrophy of the testes with spermatogenetic arrest and depletion of Leydig's cells. Immunocompromised patients can also develop epididymitis caused by atypical organisms such as *Candida* and cytomegalovirus.¹³

Necrotising fasciitis (Fournier's gangrene)

It may be the presenting condition in previously undiagnosed AIDS patients.¹⁴ All patients with this life-threatening infection should be screened for HIV.

Neoplasms

Kaposi's sarcoma (KS)

Two types of KS are described, i.e. the classic type, which occurs in patients with lymphoma or immune deficiencies, and the epidemic type, which is associated with AIDS. KS can affect any skin area, including the male genitalia. A new herpesvirus, human herpesvirus 8, is associated with all cases of KS.¹⁵ An experienced observer can easily diagnose the typical purple indurated plaques, but the diagnosis needs to be confirmed by biopsy.

Non-Hodgkin's lymphoma (NHL)

Patients with NHL usually have widespread disease at presentation and genito-urinary sites may be involved primarily or secondarily.¹⁶ Since the introduction of antiretroviral therapy the incidence of KS has decreased and therefore NHL is the most common AIDS-associated malignancy in patients on therapy.

Squamous urogenital cancers

HIV-infected patients have a higher risk of developing HPV-associated squamous cancer of the penis as well as precancerous lesions associated with HPV. A study in the USA confirmed that HPV accounts for 50% of all penile carcinomas.¹⁷ Several studies on squamous carcinoma at other sites, such as the cervix, anorectum and oral cavity, have confirmed that these cancers have a higher incidence in HIV-infected patients.¹⁸ However, only a few cases of invasive penile cancer in the HIV-infected population have been described.¹⁹ In an as yet unpublished study at the Department of Urology, University of the Free State, Bloemfontein, we found that 56% of patients with penile carcinoma were HIV positive.²⁰

Testicular cancer

Testicular tumours are 50 times more common in the HIV-infected population

than in non-infected individuals.²¹ These tumours are also more often bilateral and there is a great risk of high-grade lymphoma in the testes. This is important when considering treatment, because all the known chemotherapeutic regimens will lead to further immune suppression.

Conclusion

It is clear that several dermatological conditions and tumours of the male external genitalia are associated with HIV infection. Patients with these lesions should be screened for HIV.

References available at www.cmej.org.za

Common head and neck problems in HIV-positive patients

JOHLENE DU PLESSIS, MB ChB, MMed (Chir)

Surgeon, De Aar Hospital, Northern Cape, and Private Practitioner, De Aar

Correspondence to: Johlene du Plessis (johlene_dup@yahoo.com)

Approximately 41 - 68% of all HIV-infected patients will present with pathological conditions of the head and neck at some point in the disease.¹

Common head and neck problems in HIV-positive patients are briefly discussed under the following headings:

- ulcers, plaques and gum disease
- neoplastic growths in and around the mouth
- lumps and bumps.

Ulcers, plaques and gum disease

Ulcerations

Recurrent oral ulcerations classify the patient as having stage II disease according to the WHO staging of HIV/AIDS.² Causes for these ulcers include viruses (herpes simplex virus (HSV), varicella zoster (VZ) and cytomegalovirus (CMV)), immunological causes (aphthous ulcers) and fungal infections (candida, histoplasmosis).

HSV and VZ (shingles) most often involve the perioral skin, but can also involve the oral mucosa. The typical prodrome precedes the vesicular eruption. It is very important to remember that if the tip of the nose is involved in shingles, the patient must be evaluated and monitored for possible involvement of the eye (corneal/conjunctival ulcerations) as this can lead to serious problems if left undiagnosed.

CMV and aphthous ulcers can look very similar to VZ, but lack the typical prodrome.

Leukoplakia and erythroplakia

Oral hairy leukoplakia (Fig. 1) presents as a painless, white, slightly elevated plaque that

is not easily removable (as is the case with candida). It has a hairy appearance and is most commonly located on the lateral border of the tongue. It can also involve the ventral tongue and in rare cases the buccal mucosa. Patients are usually asymptomatic and lesions can only be observed. If a lesion should show change, however, a biopsy should be done.

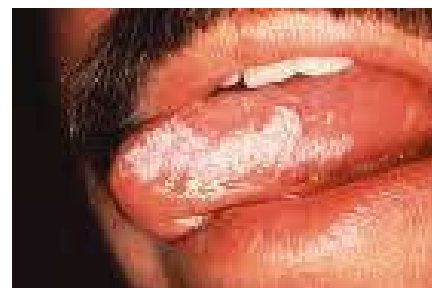

Fig. 1. Oral hairy leukoplakia.

Erythroplakia (Fig. 2) describes any red mucosal lesion and is more likely to indicate a malignant lesion. These lesions should therefore always be biopsied and followed up closely to rule out malignancy.

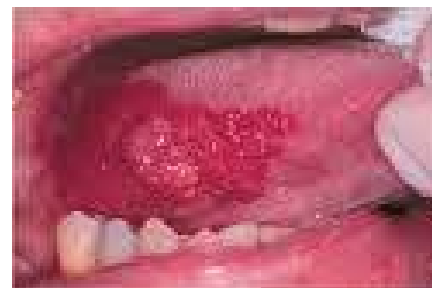

Fig. 2. Erythroplakia.

Candida albicans

Candida can present in 4 different forms:

- pseudomembranous candidiasis/thrush (most common form)
- erythematous candidiasis (red lesions on palate/dorsum of tongue)
- angular cheilitis (red, flaking lesions at corners of mouth)
- hyperplastic candidiasis (thick white plaques on mucosa) (Fig. 3).

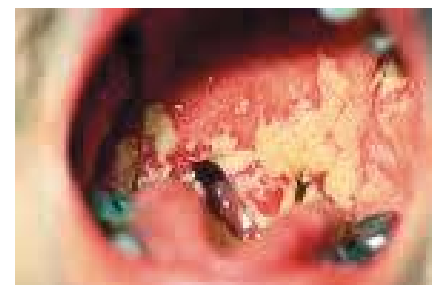

Fig. 3. Hyperplastic candidiasis.

These oral lesions can also be an indicator that candida is involving the oesophagus if accompanied by odynophagia and retrosternal pain. Oesophageal candida can be confirmed with gastroscopy. Treatment is with oral nystatin drops (only oral candida) or miconazole gel (Daktarin). Fluconazole 400

More about...

mg daily PO for 14 days is used if oesophageal candida is diagnosed.

Acute necrotising ulcerative gingivitis/periodontitis

This is an acute opportunistic infection of the gingiva that can spread to the underlying alveolar bone. Causative organisms include *Treponema* spp, *Selenomonas* spp, *Prevotella intermedia*, *Borrelia* spp, Gram-positive cocci, beta-haemolytic group B streptococci and *Candida albicans*.³ Patients present with painful, bleeding gums with varying amounts of necrotic tissue. Treatment consists of meticulous oral hygiene, debridement of necrotic tissue and local and systemic antibiotics. Oral antiseptics such as Glycothymol mouth wash can be used as adjunct therapy.

Neoplastic growths in the mouth

Human papillomavirus infection

These lesions present as condylomata acuminata, warts or focal epithelial hyperplasia. Treatment consists of simple surgical excision; biopsies can be done first if there is doubt about the diagnosis.

Kaposi's sarcoma

Kaposi's sarcoma usually presents on the skin, but the hard palate, gingiva, buccal mucosa and the dorsum of the tongue can also be involved (Fig. 4). Lesions present as red to purple raised plaques which can also ulcerate and cause pain and bleeding. Most of the time, mucosal lesions will accompany cutaneous lesions. Treatment consists of triple antiretroviral therapy and external beam radiation in collaboration with an oncologist.

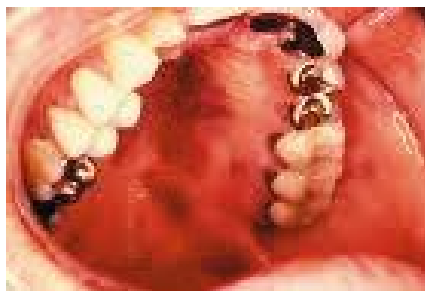

Fig. 4. Kaposi's sarcoma.

Lymphoma

Lymphoma can present in the oral cavity as a swelling or mass, but is extremely rare and usually associated with a poor prognosis.

Squamous cell carcinoma

Squamous cell carcinoma will present as in HIV-negative patients and the treatment approach will be the same.

Molluscum contagiosum

These lesions are characterised by flesh-coloured, dome-shaped, smooth or umbilicated papules and are caused by a DNA poxvirus. They are found commonly on the lips, buccal mucosa and palate (Fig. 5). Treatment of these lesions consists of cryotherapy or excision.⁴

Lumps and bumps

Lymphadenopathy

HIV-related lymphadenopathy is discussed by WJ Jacobs.⁵

Parotid enlargement

Unexplained persistent parotid enlargement is also a stage II-defining disease according

to WHO staging of HIV/AIDS.² Patients complain of mildly tender, soft parotid swelling that can be unilateral or bilateral (Fig. 6). The pathophysiology behind this phenomenon is a diffuse lymphoid infiltrate, hence the name diffuse infiltrative lymphocytosis syndrome or DILS.

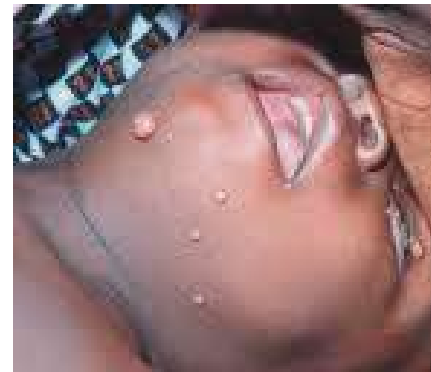

Fig. 5. Molluscum contagiosum.

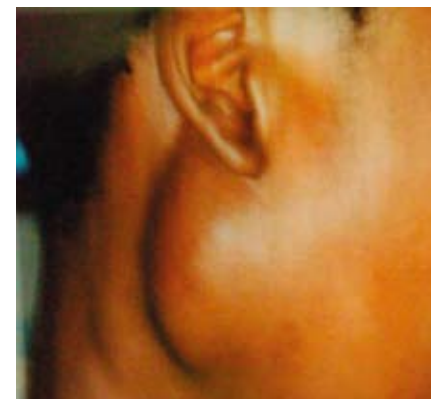

Fig. 6. DILS

Table I. Diagnosis and treatment of HIV-associated head and neck lesions

Disease	Clinical appearance	Diagnosis	Management
Candida	See text for different clinical types	Clinical picture +/- culture/biopsy	<ul style="list-style-type: none"> • Topical antifungal treatment • Systemic anti-fungal treatment for oesophageal candida
Periodontal disease	Halitosis, bleeding gums, severe pain in gums	Clinical picture	<ul style="list-style-type: none"> • Aggressive plaque removal and debridement by dentist • Topical or systemic antibiotics • Good oral hygiene
Oral hairy leukoplakia	White lesion lateral aspect of tongue, non-removable	Clinical picture +/- tissue biopsy	<ul style="list-style-type: none"> • Observation! • Biopsy indicated if there is change in lesion's appearance • In severe cases consider oral aciclovir
Herpes virus ulcers	Painful solitary/multiple vesicular lesions, may erode/coalesce	Clinical picture +/- smears +/- viral culture +/- biopsy	<ul style="list-style-type: none"> • Oral aciclovir • Can consider ganciclovir for CMV ulcers
Recurrent aphthous ulcers	Painful, well-circumscribed, shallow ulcers	Clinical picture +/- biopsy	<ul style="list-style-type: none"> • Topical analgesics (Teegel) • Topical or systemic steroids in severe cases
Kaposi's sarcoma	Painless red, bluish/purple maculae, papules/nodules	Clinical picture +/- biopsy	<ul style="list-style-type: none"> • Antiretroviral therapy • Radiation, co-ordinate with oncologist
Non-Hodgkin's lymphoma	Firm, painless focal swelling or poorly defined alveolar mass	Biopsy	<ul style="list-style-type: none"> • Oncology referral • Surgical debulking in case of airway obstruction
DILS	Painless uni/bilateral parotid swelling	Sonar, FNA	<ul style="list-style-type: none"> • Antiretroviral therapy +/- external beam radiation
Molluscum contagiosum	Flesh-coloured, dome-shaped, smooth or umbilicated papules	Clinical picture	<ul style="list-style-type: none"> • Cryotherapy or excision

There are numerous head and neck conditions that are commonly seen in HIV-positive patients, not all requiring surgical referral.

The diagnosis of DILS can be made by ultrasound/CT, which will show multiple cystic lesions throughout the superficial and deep lobes of the parotid gland. It has been described as having a Swiss cheese appearance on imaging. FNA of this lesion will reveal a benign lymphoepithelial cyst. Please do not do true-cut biopsies! You don't want the pathology report to come back reporting 'pieces of normal facial nerve!' Management of these lesions is not surgical and consists of antiretroviral therapy and/or external beam radiation.

The diagnosis and treatment of HIV-associated head and neck diseases are summarised in Table I.

Conclusion

There are numerous head and neck conditions that are commonly seen in HIV-positive patients, not all requiring surgical referral. It is very important that primary care physicians recognise these conditions and know when to refer them and when they can be managed at primary care level.

References available at www.cmej.org.za

The paediatric surgeon and HIV

ESMÉ LE GRANGE, MB ChB, MMed(Surg), Cert Ped Surg (SA)

Head, Clinical Unit, Paediatric Surgery, Universitas Hospital, Bloemfontein and Senior Lecturer Department of Surgery, University of the Free State, Bloemfontein

Correspondence to: Esmé le Grange (legransm.@ufs.ac.za)

Children form a large proportion of the HIV-positive population. A portion of infected infants progress rapidly to full-blown AIDS and die within 1 year without treatment.^{1,2} However, a larger proportion of infected infants and children (36%) are slow progressors² who have a median survival age of 16 years.

Prevention of mother-to-child transmission (PMTCT)

Mother-to-child-transmission³ (MTCT) takes place either during pregnancy, during

labour, or during breastfeeding. It has been shown that infants born to mothers who have the full-blown syndrome are more affected than those born from mothers who are HIV-positive.⁴ The Cochrane database from 2002 shows the advantages of programmes to prevent mother-to-child transmission, also recognising the fact that transmission rates drop to 1 - 2% in mothers on antiretroviral therapy.⁵ The PMTCT programme in South Africa aims to minimise transmission of the virus.

Testing difficulties

Infants (babies up to the age of 1 year) are notoriously difficult to test, because the maternal antibodies are still detected up to this age. Therefore the commonly used ELISA test cannot be used in this population group. A test where viral material is detected, such as the polymerase chain reaction (PCR) test, is a good option for those above the age of 1 month, although more expensive than the normal tests. Below the age of 1 month, however, the PCR test has 100% specificity, but only 70% sensitivity.^{6,7} This has resulted in the term 'HIV-exposed'.

Surgical problems

Infectious diseases

Necrotising enterocolitis (NEC). The preliminary results of our own research on the incidence of NEC among HIV-exposed babies suggests that they are more prone to develop NEC with a worse outcome. This is consistent with other findings.⁸ The possibility exists that these patients' disease is complicated by the cytomegalovirus (CMV) – a source of concern in the adult group as well. This results in CMV enteritis, a disease that is notoriously difficult to treat surgically, because a large proportion of the bowel is usually involved in the inflammatory process, with several perforations along its tract. Peritoneal drainage traditionally used for NEC seems appropriate in these circumstances. In our own series 49% of patients escaped an operation.

Tuberculous adenitis and peritonitis.

Tuberculosis (TB) is endemic and pandemic in sub-Saharan Africa. There are also high rates of resistant disease (RTB), as well as extremely resistant (XRTB) strains. We also see other strains, such as bovine tuberculosis, especially where patients present with the peritonitic variant of the disease.

- TB peritonitis is notoriously difficult to diagnose: the textbook clinical picture of peritonitis in the presence of pulmonary tuberculosis is not often seen, because commonly these patients have tuberculosis of the gastroenteric tract only – often of the bovine type. If suspected, a tuberculin skin test is useful in younger children; however, if the patient's immune system

is under severe pressure from underlying HIV, it may be falsely negative. We use computed tomography (CT) scans in our institution to help with the diagnosis, but often a histological diagnosis is necessary. Here, minimal access surgery (MAS) becomes particularly useful, because these children are often too sick for a traditional laparotomy. Tissue and fluid for histology, microbiology, as well as PCR testing should be taken. Adenosine deaminase (ADA) testing on ascitic fluid is also helpful.

- Lymphadenopathy is a reality in our everyday practice. This poses a real diagnostic dilemma: it may be that the patient has recently seroconverted and therefore has generalised lymphadenopathy, but it also may be due to tuberculosis or even lymphoma. All of these are highly treatable conditions and not necessarily terminal. It is therefore important that the paediatric surgeon does lymph node biopsies in HIV-positive children with the following criteria: more than 2 cm in diameter, present for longer than 2 months, and/or caked together.

Malignancies

Lymphoma. As in adults, the incidence of the lymphomas is vastly increased in HIV-infected children. For instance, the incidence of primary central nervous system lymphoma (PCNSL) is more than 1 000 times that of the normal population.⁹ In a series by Bonnet in France, 11% of deaths in HIV-infected patients were caused by lymphoma.¹⁰ Still, it appears that the prognosis of these malignancies compares very favourably with those in uninfected patients, especially when the patients are on antiretroviral therapy.

Kaposi's sarcoma. Likewise, Kaposi's sarcoma is treated very successfully in children. One should remember that antiretroviral therapy is the first line of treatment, combined with other forms of ablation, such as cryotherapy and radiation, as well as different regimens of chemotherapy.¹¹

Other malignancies. Incidental findings of seropositivity and even AIDS are found among our patients with different forms of malignancy. These patients are put on antiretroviral therapy at the time that they start chemotherapy. Care should be taken, because these patients are known to develop immune reconstitution inflammatory syndrome (IRIS).¹²

References available at www.cmej.org.za

The impact of HIV/AIDS on orthopaedic surgery

PEET VAN AARDT, MB ChB, MMed (ORT)

Consultant, Department of Orthopaedic Surgery, University of the Free State, Bloemfontein

Correspondence to: Peet van Aardt (peetvan@mweb.co.za)

As is the case with other surgical disciplines, orthopaedic surgery was dramatically influenced by the HIV pandemic. Early experience, reporting complication rates of 140% and mortality rates of 55 - 70%, led to a pessimistic approach to surgery in HIV-positive patients. The initial perception was that these patients were prone to:

- poor wound healing¹
- high postoperative complication rates
- a protracted postoperative period
- higher mortality rates.

These early studies were skewed by the fact that these procedures were usually performed as emergencies presenting as direct consequence of HIV infection. Later follow-up work changed this perspective dramatically. The success of antiretroviral therapy has further led to a change in the initial approach to the HIV positive.

The impact of HIV can be divided into orthopaedic diseases caused by HIV/AIDS and problems or potential complications with orthopaedic surgery and implants in HIV-positive patients.

HIV-related orthopaedic diseases

Osteonecrosis, osteopenia, and osteoporosis are conditions seen increasingly in patients with HIV. These conditions may be caused by the infection itself, antiretroviral therapy or lipodystrophy.

Osteopenia and osteoporosis

A change in bone turnover occurs in HIV-positive patients. This is probably because of deregulation between osteoclast and osteoblast function. Studies reported increased cytokine levels (IL, TNF) and increased osteoprotegerin levels, leading to deregulation of RANKL-RANK interaction.²

Antiretroviral therapy (specifically protease inhibitors) and lipodystrophy caused by antiretrovirals have also been linked to bone loss, but conclusive evidence remains lacking. The incidence of osteopenia is 14 - 84% and that of osteoporosis is up to 45% in HIV patients, but no difference in fracture rates could be demonstrated between patients

receiving and not receiving a protease inhibitor regimen.²

Approach to emergency and elective orthopaedic surgery

When dealing with an HIV-positive patient presenting with an orthopaedic complaint, one has to distinguish between the asymptomatic seropositive patient and the symptomatic AIDS patient. Staging the disease, using the WHO staging system based on CD4 counts and clinical information, led to a more aggressive surgical approach in these patients.³ Furthermore, the surgical approach is dictated by whether it is an emergency or an elective case.

Trauma

Polytrauma

HIV is reported as a significant prognostic indicator for an adverse outcome in acute lung injury and adult respiratory distress syndrome in ICU patients. It is also reasonable to expect higher secondary infection rates in HIV-positive patients.

Closed fracture

Initial unrefined studies reported infection rates as high as 24 - 40%, but recent studies^{3,4} showed infection rates of 3.5% in patients with CD4 counts as low as 200 cells/ μ l. The recommendations are effective prophylactic antibiotic use (first-generation cephalosporin), clean operating environment, strict theatre discipline and careful soft-tissue handling.

Open fracture

Depending on the level of contamination, infection rates as high as 42% can be expected compared with 11% in controls. Open tibia fractures are particularly prone to deep chronic infection and the use of external fixation seems well advised.⁵

Fracture union

A higher incidence of HIV was found in patients presenting with delayed union or non-union, but this seems to respond to stable internal fixation and autologous bone grafting.

Late sepsis

An increased risk of late sepsis was found in trauma and arthroplasty patients and removal of instrumentation may be indicated as the disease advances. These late infections can be due to reactivation of latent bacteria or may be because of late haematogenous seeding.

The approach to trauma should be guided by the merits of the patient's injury, and the established priorities of early and adequate

debridement and fracture stabilisation still hold. It might be worthwhile to prefer external immobilisation when dealing with open fractures in HIV-positive patients, especially open tibia fractures.

Elective surgery

Arthroplasty

Most of the research in this regard was on HIV-positive haemophilic patients. A large retrospective multicentre study found an increased rate of deep sepsis – as high as 18.7%. These patients are also at risk for bleeding in and around their joints as well as bacteraemia associated with regular factor transfusions. Both of these factors may contribute to late sepsis. HIV-positive haemophilic patients may not be a true reflection of the infection risk associated with HIV-positive arthroplasty. HIV-positive non-haemophilic patients may also have a need for arthroplasty because of a higher incidence of avascular necrosis. The risk of sepsis seems to be lower in these patients, but literature remains lacking.^{3,6}

Spinal surgery⁷

Young and others found no major complications on a small series of HIV positive patients undergoing spinal surgery.⁷ The mean CD4 count in these patients was 279 cells/ μ l.

Other implants and elective surgery

A prolonged course of prophylactic antibiotics (10 days of cefuroxime) was found to be beneficial in WHO group A patients. Otherwise elective surgery seems to be safe in HIV-positive patients.⁸

Wound healing

Harrison *et al.*⁹ found that in the absence of preoperative wound contamination, there is no higher incidence of wound infection regardless of the CD4 count. Buehrer confirmed this in a similar HIV-positive haemophilic study. The same was found by Harrison *et al.*, but they also found a more rapid progression to AIDS in patients who had a lower CD4 count.⁹

Conclusion

The initial nihilistic surgical approach to HIV-positive patients seems to have been too cautious. With a few exceptions, most orthopaedic surgery can be undertaken safely in these patients, provided that one adheres to proper surgical principles.

References available at www.cmej.org.za