

Social entrepreneurship in health

WILL MAPHAM, MB ChB

Medical Officer, Good Shepherd Hospital, Swaziland

SAUL KORNIK, BBSucSc (Hons Finance), BCom (Hons Accounting), MCom, CA(SA), CFA
Chief, Africa Health Placements, South Africa

Correspondence to: Will Mapham (william.mapham@gmail.com)

A growing number of social entrepreneurs are being recognised for creating social change. The magazine *Fast Company* has aptly defined social entrepreneurial organisations as those 'using the disciplines of the corporate world to tackle daunting social problems.' Although there are similarities between social entrepreneurs and entrepreneurs in the traditional sense (e.g. both create new organisations and employment opportunities), the former are driven primarily by an intrinsic desire to solve societal problems, while business entrepreneurs measure performance by profit and return. With their focus on collective change and development, social entrepreneurs have a significant impact on the community and the economy. Florence Nightingale, who founded the first nursing school and developed modern nursing practices, is an historical example of positive social entrepreneurship. A modern South African organisational example is Africa Health Placements, which reverses the 'brain drain' by recruiting health professionals for rural hospitals.

The terms social entrepreneur and social entrepreneurship were first used in literature on social change in the 1960s and 1970s. The terms came into widespread use in the 1980s and 1990s and figures from the past, such as Florence Nightingale, are now being retrospectively recognised as examples. Social entrepreneurs are most commonly associated with non-governmental organisations (NGOs); however, social entrepreneurial ventures can also make a profit. There is debate over precisely who qualifies as a social entrepreneur. Definitions range from founders of organisations that primarily rely on earned income to those

founding organisations that are solely funded by grants, donations or the state. Peter Drucker, a management consultant, once wrote that there was nothing as entrepreneurial as creating a new university; yet in most countries the majority of university funding comes from the State.

Social entrepreneurial organisations tackle problems in creative ways. 'We are all faced with a series of great opportunities brilliantly disguised as impossible situations' (Charles Swindoll). The lack of human resources in the South African public health care system, especially in rural areas, may be viewed as an impossible situation. South Africa is in desperate need of health workers in rural areas and the statistics speak for themselves. The eight medical schools in South Africa cumulatively graduate approximately 1 200 doctors annually. However, over their career half of these doctors will move to work overseas. This mass exodus leaves about 600 new doctors in South Africa per year. Three-quarters of the remaining doctors work in the private sector, leaving only 150 doctors to work in the public sector within the country. Of those remaining in public service, the vast majority will work in urban centres. Therefore, as few as 35 doctors from any single year of graduation serve the rural areas of South Africa. Africa Health Placements is a local South African example of how this particularly daunting social problem can be met using a corporate social entrepreneurial approach. Their main achievement has been finding, placing and retaining qualified and equipped medical professionals in areas of need. Since its inception in 2005, it has stationed over 1 800 doctors in rural hospitals in South Africa. It operates in a business-minded manner with an aim to ultimately help medical professionals view employment in the public sector as a feasible and an exciting career option.

While entrepreneurs change the face of business, social entrepreneurs act as the change agents for society by seizing previously neglected opportunities, improving systems, inventing new approaches and creating ethical solutions. In the same way that business entrepreneurs may create entirely new industries, social entrepreneurs develop new solutions to social problems on a macro scale. Social entrepreneurs are normal,

everyday people who forego the pursuit of private wealth in order to create social value. These passionate industrialists serve as 'building blocks' for the development of their community and civil society as a whole. The health sector in South Africa is full of challenges and requires motivated people who are willing to solve them, particularly in rural areas where the options appear at first to be limited. To develop proactive visionaries one must foster a social entrepreneurial culture that inspires all people to innovate, create, catalyse, solve problems, utilise resources, and ethically take advantage of opportunities.

For more inspiring examples of social entrepreneurship see the following websites: <http://www.schwabfound.org>, <http://www.ashoka.org>, <http://www.skollfoundation.org>, <http://www.echoinggreen.org>. To read more about Africa Health Placements see www.ahp.org.za.

Further reading available at www.cmej.org.za

Snake antivenoms in southern Africa

THEA LITSCHKA-KOEN¹
DAVID J WILLIAMS², BSc,
GDipRMeth

¹*Simunye Country Club, Simunye, Swaziland*

²*Australian Venom Research Unit, Department of Pharmacology, University of Melbourne, Parkville, Australia and School of Medicine & Health Sciences, University of Papua New Guinea, Boroko, Papua New Guinea*

Correspondence to: Thea Litshka-Koen (tlitschka@rssc.co.sz)

Antivenoms have been available for the treatment of snake bites for more than 110 years, and are considered to be the most effective treatment with which to neutralise injected venom. They are included in the World Health Organization's (WHO) List of Essential Medicines (<http://apps.who.int/emlib/Default.aspx?Language=EN>), and hence should be available for the treatment of snake bites in all countries in which venomous snakes pose a public health risk. In southern Africa there is currently only

Table I. Resuscitation preparations before giving antivenom

Minimum requirements* for equipment and drugs that should be available at the bedside, prior to the commencement of antivenom treatment:

Equipment

- Basic airway and breathing devices (oxygen supplies, masks, tubing, Guedel's airways, Ambu-bags)
- Manual (hand/foot-operated) or mechanical suction pumps, tubing, suction catheters (Yankaeur, tracheal, etc.)
- Large-bore IV cannulas, additional IV giving sets, and associated paraphernalia

Drugs

- Labelled, pre-drawn adrenaline doses (1:1 000 for adults, 1:10 000 for children) for use in the event of adverse reactions to antivenom
- Labelled, pre-drawn antihistamine (promethazine) and hydrocortisone doses
- Crystalloid or other fluids suitable for volume expansion

* Larger, better-equipped hospitals with appropriately trained personnel and equipment should also have necessary equipment and drugs for performing emergency intubation of the upper airway and ventilation available.

one antivenom manufacturer, South African Vaccine Producers (Pty) Ltd (SAVP), based in Johannesburg, SA (<http://www.savp.co.za>). SAVP manufactures three antivenom products, two of which are relevant to the treatment of envenomation in southern Africa. The first and most widely used of these is SAVP polyvalent antivenom, which provides specific protection against eleven species:

- puff adder (*Bitis arietans*)
- eastern gaboon viper (*Bitis gabonica*)
- Angolan adder (*Bitis heraldica*)
- eastern green mamba (*Dendroaspis angusticeps*)
- Jameson's mamba (*Dendroaspis jamesoni*)
- black mamba (*Dendroaspis polylepis*)
- rinkhals spitting cobra (*Hemachatus haemachatus*)
- snouted cobra (*Naja annulifera*)
- forest cobra (*Naja melanoleuca*)
- Mozambique spitting cobra (*Naja mossambica*)
- Cape cobra (*Naja nivea*).

Less frequently used is monovalent antivenom for treatment of boomslang (*Dispholidus typus*) bites, which although rare, can be life-threatening in the absence of antivenom therapy.



Black mamba.

Recently there have been moves by antivenom manufacturers in India and Mexico to introduce other antivenom products into African markets, but these have in some cases been disastrous, in one case leading to a 6-fold increase in case fatality rates.¹⁻⁴ None of these products have been clinically trialled as treatments for bites by any snake species that occur in southern Africa, yet attempts are being made to market them. Such problems highlight the critical need for appropriate regulatory control and careful scrutiny of licensing applications, particularly where published preclinical and clinical studies of new antivenoms are lacking. In an effort to improve the production of antivenoms, the WHO published Guidelines for the Production, Regulation and Control of Snake Antivenom Immunoglobulins in 2010.⁵ These guidelines and an accompanying website resource (http://apps.who.int/entity/bloodproducts/snake_antivenoms/en) are a valuable guide that can assist regulators, health managers and clinicians to identify the correct antivenoms for their countries or regions.

For clinicians the use of antivenom often poses questions and uncertainties that can, if left unresolved, result in a reluctance to use antivenom. This may delay specific venom neutralisation, leading to further complications and poorer outcomes for patients. Some of the more common concerns of doctors dealing with snake bites are centred on questions such as those discussed below.



Black mamba.

The risk that the treatment may be worse than the disease

Antivenoms are solutions of animal (usually equine) immunoglobulins and like any foreign protein, they can cause adverse reactions, ranging in severity from mild cutaneous eruptions to life-threatening anaphylaxis. A study of antivenom reactions reported urticaria, vomiting, fever, bronchospasm, angio-oedema and hypotension among a cohort of patients treated with SAVP polyvalent antivenom.⁶ All these reactions were treated successfully, and all the patients survived their snake bites.



Boomslang.

The risk of a potentially severe reaction to antivenom should be balanced against the need to neutralise circulating venom, particularly after envenomation by species with neurotoxic venoms, such as black mambas (*Dendroaspis polylepis*) or snouted cobras (*Naja annulifera*). Clinicians should include appropriate preparation for treating adverse events such as anaphylaxis in their protocols for antivenom administration. For example, adequate supplies of adrenaline should be drawn up and ready for use, and resuscitation equipment, drugs and volume expanders kept close at hand (Table I). Premedication with subcutaneous adrenaline should be considered, as some studies suggest that it is effective in reducing incidence of antivenom reactions caused by some antivenoms.⁷ However, premedication with antihistamines and hydrocortisone has been found to be ineffective.^{8,9}



Boomslang fangs.

Antivenom doesn't seem to be effective

Use of antivenom in patients with well-established cytotoxicity or advanced neurotoxicity may appear not to be particularly effective, due to the inability of antivenom to rapidly reverse the local effects of cytotoxins or the profound respiratory depression of paralysed patients. A common reason for apparent ineffectiveness is inadequate dosage – see below. Clinicians should be realistic in their expectations of what antivenom can and cannot do. It is important to remember that the role of antivenom is to neutralise injected venom. Antivenom does not repair destroyed tissues or nerve cells. Neutralising the injected venom may prevent further progression of cell injury, but will not undo the damage that has already been done. Early administration of antivenom leads to the best clinical outcomes.



Puff adder.

It is also important that antivenoms be properly stored and transported. SAVP antivenoms require adherence to strict cold chain requirements, with temperatures between 4°C and 8°C at all times. They must not be frozen, and antivenoms that have been subjected to freezing or to higher than optimal storage temperatures may no longer be effective.

Table II. Indications for antivenom administration in Africa⁵

Systemic envenomation

- Neurotoxicity
- Spontaneous systemic bleeding
- Incoagulable blood (20MWBCT)
- Cardiovascular abnormality: hypertension, shock arrhythmia, abnormal electrocardiogram

Local envenomation by species known to cause local necrosis*

- Swelling of the whole hand or foot occurs in 1 hour
- Swelling extends 15 cm or more per hour
- Swelling extends to the elbow or knee in 3 - 4 hours
- Swelling to the whole limb within 12 hours
- Bites to fingers or toes

* *Bitis* spp. and spitting cobras in southern Africa.

Table III. Guide to initial dosage of antivenoms for some southern African snake species⁵

Species	English name	Antivenom	Initial dose
<i>Bitis arietans</i>	Puff adder	SAVP Polyvalent	50 - 100 ml
<i>Bitis gabonica</i>	Gaboon viper	SAVP Polyvalent	50 - 100 ml
<i>Dendroaspis polylepis</i>	Black mamba	SAVP Polyvalent	50 - 200 ml
<i>Dendroaspis angusticeps</i>	Eastern green mamba	SAVP Polyvalent	50 - 100 ml
<i>Dispholidus typus</i>	Boomslang	SAVP Boomslang	20 ml
<i>Naja annulifera</i>	Snouted cobra	SAVP Polyvalent	50 - 120 ml
<i>Naja haje</i>	Egyptian cobra	SAVP Polyvalent	50 - 120 ml
<i>Naja mossambica</i>	Mozambique spitting cobra	SAVP Polyvalent	100 ml
<i>Naja nigricollis</i>	Black-necked spitting cobra	SAVP Polyvalent	50 - 100 ml
<i>Naja nivea</i>	Cape cobra	SAVP Polyvalent	80 - 120 ml



Snouted cobra.

Uncertainty about the suitability of antivenom for particular species

Polyvalent antivenoms are designed to enable treatment of bites by a number of species, and this negates to considerable degree the need to identify the culprit, although this additional knowledge can greatly assist in the planning for the management of the patient. If the biting species is unknown, but the patient has signs of envenomation sufficient to warrant antivenom, its use should not be delayed (see below). In most

cases polyvalent antivenom is the appropriate choice. The important exception follows bites by the boomslang, a slender, often arboreal, snake that causes significant coagulopathy, including internal and external haemorrhage, defibrination, thrombocytopenia, and widespread ecchymoses over a period of days (rather than hours). Selection of SAVP boomslang antivenom is indicated in such cases. This needs to be ordered from Pretoria and arrangements made to administer it in an ICU setting, which usually means transferring the patient to an urban centre, to which the antivenom can be sent.



Mozambique spitting cobra.



Snouted cobra.

When should it be used?

The earlier antivenom is administered, when indicated, the greater the clinical benefit to the patient in terms of the potential to save life and limb. Nevertheless, it is never too late to give antivenom, and delayed presentation to hospital is not grounds to withhold antivenom therapy. Antivenom is not needed for every snake bite, as many cases result in no clinical illness, even after bites by dangerous species. This is because ejection of venom upon biting is voluntary, and many snakes bite defensively without injecting venom. However, clinical signs of neurotoxicity, coagulopathy, signi-

ficant cytotoxicity or cardiovascular effects are important indications for antivenom which should never be ignored (Table II). All snakebite victims should ideally be observed hourly by a health professional for at least 24 hours.

How much to give, and by what route

Antivenom needs to be given in a large enough dose to neutralise all the injected venom. Under-dosing with antivenom leads to poor patient outcomes, undermines confidence in antivenom effectiveness, and may lead to prolonged hospitalisation, which ultimately exceeds the cost of an initial treatment with a therapeutically effective volume of antivenom. Dose recommendations for some southern African species are given in Table III. Antivenom should be administered intravenously, a good reason to establish early intravenous (IV) access in all patients with suspected snake bite. Actual administration may be via infusion in crystalloid intravenous fluid, or by IV 'push' injection. A paediatric burette is a useful device for mixing a diluted solution of antivenom in a volume that can be delivered by infusion over 15 - 30 minutes, and may be used with both adults

and children for this purpose. If IV 'push' is used, antivenom should be injected slowly at a rate of no more than 5 ml per minute. In both cases, antivenom administration can easily be suspended if a reaction occurs, and then resumed once the reaction has been treated successfully.



Mozambique spitting cobra.

If a patient has presented to hospital with a tourniquet, ligature or pressure immobilisation bandage, it may be prudent to commence antivenom administration

More about...

prior to loosening or removal of the restrictive item, since severe envenomation may sometimes develop very rapidly once the venom in the occluded limb is released into the circulation.⁵ Pregnant women are at risk of haemorrhage, premature labour, foetal distress and stillbirth after envenomation. Early and adequate antivenom treatment is indicated, as its benefits outweigh the risks to the mother and foetus. Because of the body mass-to-venom ratio, children must receive the same dosage as adults.

Summary

Immunotherapy with antivenom can be a highly effective treatment for snake envenomation, provided the products meet appropriate standards and have adequate potency. Caution should be exercised in the use of any product that is (i) not registered in the country where it is to be used, and (ii) has not been subjected to adequate, robustly designed and openly reported preclinical and clinical trials. Significant morbidity, disability and mortality could be prevented by using adequate antivenom as early as it is indicated by clinical evidence.

References available at www.cmej.org.za

Hand solutions: an approach to hand injuries in primary care

STEVEN MILLER, MD, FACS

General, Trauma and Hand Surgeon, Maricopa County Integrated Health System, Phoenix, Arizona, USA

Correspondence to: Steven Miller (kayakmd@cox.net)

Hand solutions for the primary care physician, particularly in rural Africa, are predicated upon prompt and skilful diagnostic acumen. Evaluating the hand is no different to examining any other organ system. However, it is perceived as both an essential part of human independence and cosmetics. The hand serves as one of our finest tools and sensory receivers. Returning your patient to independence and occupation is a noble art and hand care is critical to that purpose.

Treating a patient who has suffered a hand injury begins with an accurate history – not a simple task with language barrier and anxiety factored into the problem. Hand dominance, work history, medical history and especially

details of the injury or complaint should be identified.

Physical examination starts with the neurovascular exam. Is there a good pulse: radial and ulnar? Is the Allen's test delayed by more than 10 seconds? Is there a delayed capillary refill at the finger tip? Is two-point discrimination at the finger pulp intact? (2 - 5 mm is normal). The mechanism of trauma such as crush or laceration could explain the ischaemic hand. Documenting soft-tissue loss, degree of burn or need for skin graft is helpful.

Fractures are sometimes subtle, but can be identified with a good history and by carefully examining the suspicious area on X-ray (Fig.1). A three view X-ray is necessary. However, if X-ray is not available then palpation and inspection, observing open fractures or feeling crepitus can aid in the diagnosis. An open fracture is best treated promptly with intravenous antibiotics and then sterile irrigation. Further repair would depend on available surgical care.

The shotgun blast in Fig. 2 resulted in catastrophic tissue loss. As noted, the index

finger could not be salvaged but using available skin and soft tissue, a flap was mobilised to afford a functional hand despite the extensive injury (Fig. 3).

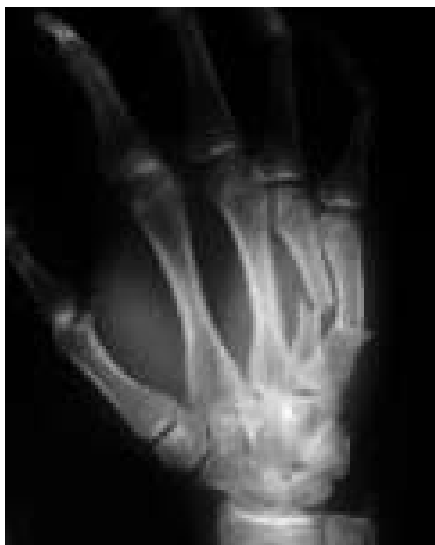

Fig. 1. Metacarpal fractures.

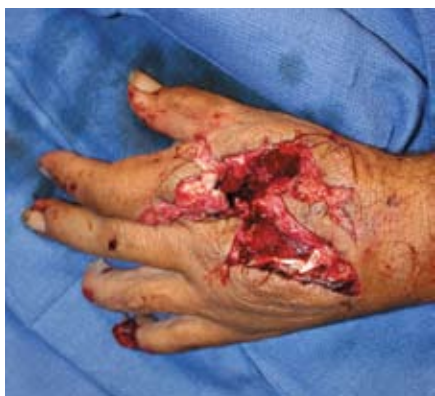

Fig. 2. Shotgun wound.

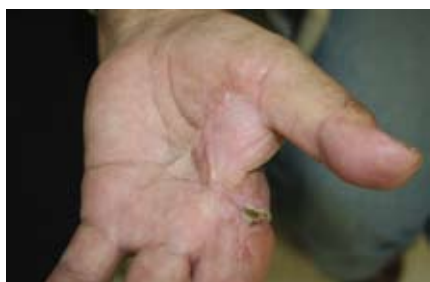

Fig. 3. Shotgun follow-up.

Wrist injuries are particularly troublesome as they can result in subtle fractures with disability. A scaphoid fracture (Fig. 4), the most common carpal bone fracture, can result in proximal bone non-healing because most (80%) of the blood supply is from a single vessel that begins distal to the proximal bone. It is likely this small twisted peanut-shaped bone is fractured at its 'waist' and will cause a non-union or even avascular necrosis. The scaphoid supports the trapezium outside the plane of the palm, which supports the first

metacarpal. The thumb is thereby enabled to oppose all other digits outside the plane of the palm. Encourage your patient to stop using any form of tobacco, and keep them in a thumb spica cast a minimum of 6 weeks followed by 6 weeks of range of motion with a splint. The scaphoid can be repaired but most healthy patients will heal this injury without surgical intervention providing it is aligned and promptly immobilised.

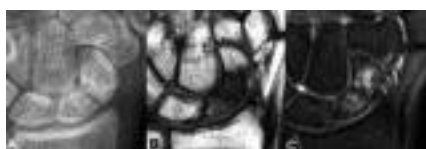


Fig. 4. Scaphoid fracture.

The most common wrist fracture, the distal radius fracture, is fortunately likely to heal well with good care. Reducing the fracture, providing it is not severely malaligned with intra-articular fragments, should be straightforward after placing the hand in finger traps and infiltration of the fracture line haematoma with 1% lidocaine without adrenaline. A 'sugar tong' splint will keep the wrist stable and accommodate swelling until a short arm cast can be applied 7 - 10 days later. If the fracture is non-reducible and especially if the neurovascular status of the hand is questionable this patient needs prompt orthopaedic and hand surgical evaluation.

Finger trauma is expected in a primary care situation. An effective finger block with xylocaine without adrenaline injected at the radial then ulnar side (not circumferential) will help resolve the patient's pain problems while you can treat the finger. A glove tourniquet may be necessary to permit a dry field for examination. Finger-tip amputations distal to the distal interphalangeal (DIP) joint can be simply debrided and coated with antibiotics in a child. They will grow a new finger-tip - honestly! In adults, however, debridement and closure is best after approximately age 16. Severe tissue loss in critical finger pulps can be resolved with either a thenar or cross-finger flap.

Foreign bodies, splinters and glass, can be vexing. Take your time. Use good lighting and magnification. Advise your patient that you may not be successful. Go with the money: where does the patient feel the most pain? X-rays are seldom helpful, unless the foreign body is metal.

Although I do not advise a full Brunner incision for exposure of a finger in a primary care situation, this is a technique with tourniquet and anaesthesia that affords excellent exposure for tendon repair, foreign-body removal and abscess drainage. If no other surgical care is available nearby then consider talking over your intended procedure with an experienced colleague before proceeding (Fig. 5).

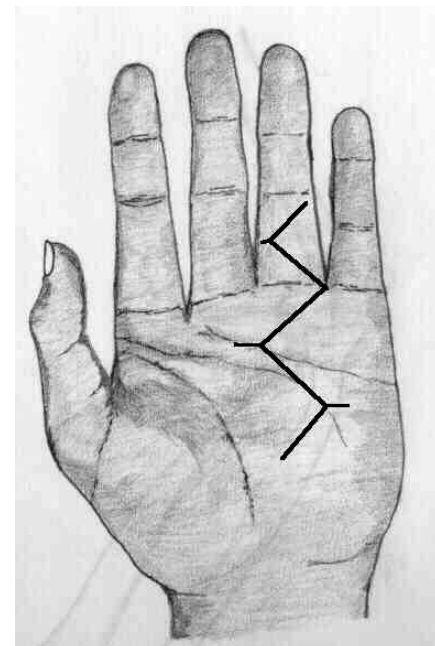


Fig. 5. Zig-zag incisions.

In the western USA rattlesnake bites are not uncommon. Like every venomous bite, especially in Africa, patients are first treated with antivenom then, as the patient systemically improves, attention is directed to the affected tissue. In over 85% of rattlesnake bites in the USA the upper extremity is injured. Debridement of necrotic tissue as shown in the thumb debridement in Fig. 6 a week after the bite is necessary, followed by tissue coverage.

Paronychia and felons are likewise surgical problems easily solved in a primary care office with a finger block, glove tourniquet and strict attention to delicate surgery. The felon should never be drained with the 'fish mouth' incision. I prefer a small longitudinal incision over the pulp finger abscess followed by drainage, irrigation and daily soaks. Dakins solution (dilute bleach: approximately 28 g bleach to 28 g sterilised water or normal saline) is an excellent irrigant and soaking solution for fingers. Fig. 7 shows paronychia drainage with the scalpel blade always parallel to the nail.

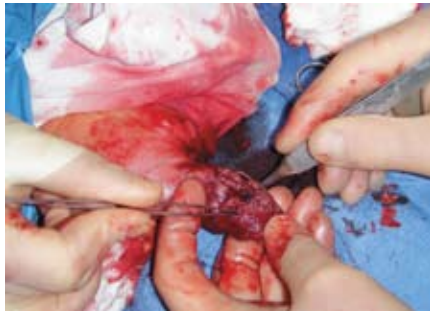

Fig. 6. Rattlesnake debridement.

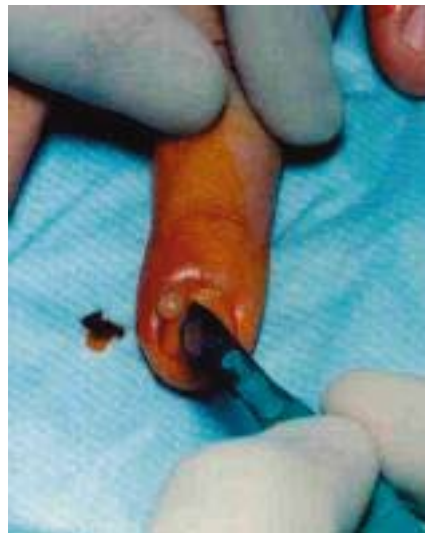

Fig. 7. Paronychia.

Hansen's disease is considered rare except in sub-Saharan Africa and India. The hallmark ulnar anaesthetic fingers and absorbed finger tips can progress to absent intrinsic muscles of the hand (interosseus and lumbricals), resulting in a 'claw hand'.

Transferring functional tendons (i.e. flexor digitorum superficialis) can reconstruct the co-ordinated grasp lost with the absent intrinsic muscles. The patient can become independent, even functional again, despite neurological defect. Your patient with longstanding ulnar or median nerve trauma may need similar transfers due to muscle wasting. Step one is recognising the deficit

and then enabling your patient with a solution: an available experienced surgeon to do the transfers.

Hand solutions are essential in rural care medicine. Hand solutions can assist you in returning your patient to a healthy independent life.

SINGLE SUTURE

A fat tummy shrivels your brain

Having a larger waistline may shrink your brain.

Obesity is linked to an increased risk of type 2 diabetes, which is known to be associated with cognitive impairment. So Antonio Convit at the New York University School of Medicine wanted to see what impact obesity had on the physical structure of the brain. He used magnetic resonance imaging to compare the brains of 44 obese individuals with those of 19 lean people of similar age and background.

He found that obese individuals had more water in the amygdala – involved in eating behaviour. He also saw smaller orbitofrontal cortices in obese individuals, important for impulse control, and also involved in feeding behaviour. 'It could mean that there are less neurons or that those neurons are shrunken,' says Convit.

Eric Stice at Oregon Research Institute, Eugene, thinks that the findings strengthen the 'slippery slope' theory of obesity. 'If you overeat, it appears to result in neural changes that increase the risk for future overeating,' he says. Obesity is associated with a constant, low-level inflammation, which Convit thinks explains the change in brain size.

New Scientist, 8 January 2011.