

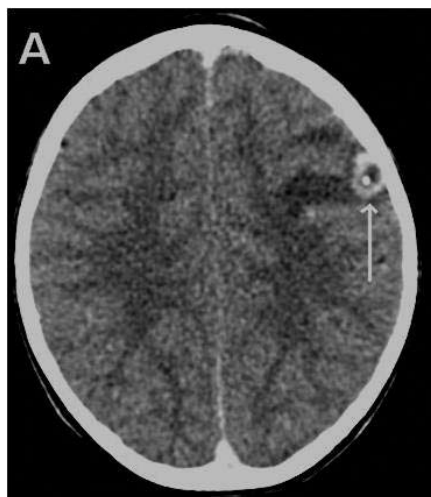Fig. 1. A CT scan showing neurocysticercosis with a calcified nodule representing a scolex, and surrounding oedema.

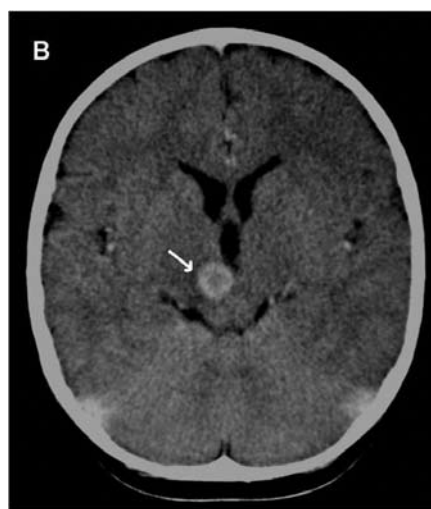


Fig. 2. Tuberculoma in the right midbrain showing ring enhancement after contrast administration.

granuloma, most radiologists do not opt for a specific diagnosis. Depending on clinical findings, the differential diagnosis includes glioma, brain abscess and toxoplasmosis.

Investigations supporting a tuberculous aetiology include a positive tuberculin skin test, a chest radiograph suggestive of pulmonary tuberculosis and a cerebrospinal fluid (CSF) picture characteristic of tuberculous meningitis. Identification of acid-fast bacilli and culture of *Mycobacterium tuberculosis* from gastric washings and/or CSF specimens confirm a tuberculous aetiology. Serological tests are positive in only a small number of cases of neurocysticercosis and are generally not helpful in the diagnosis.

Management

If a diagnosis of tuberculoma is made, the treatment is 6 months of high-dose anti-tuberculosis treatment, i.e. rifampicin 20 mg/kg/day, isoniazid 20 mg/kg/day, ethionamide 20 mg/kg/day and pyrazinamide 40 mg/kg/day.

day. Prednisone 2 mg/kg/day is given for 1 month. It has previously been documented that most tuberculomas disappear after 6 months of antituberculosis therapy. A repeat CT scan is therefore advocated after 6 months of therapy.² Treatment is complete once the lesion is no longer visible, is calcified or shows no contrast enhancement. It is important to remember that tuberculomas may paradoxically enlarge on treatment before reducing in size.

Treatment of neurocysticercosis should be individualised and the decision to use anthelmintics should be based on the number, location and viability of the parasite in the central nervous system. There is no consensus regarding the use of anthelmintics in children with neurocysticercosis.¹ Arguments against treatment include CT-demonstrated enhancing lesions that represent dying parasites and lesions that tend to resolve spontaneously. There is some evidence that radiological clearance may be accelerated in children with viable lesions. However, this does not affect seizure recurrence. Albendazole has become the anthelmintic of choice and offers good CSF penetration.⁴ There is not enough evidence regarding the optimal dose or duration of treatment with albendazole. The published dose schedule is 15 mg/kg/day and short courses of 7 days or less are as effective as longer courses.⁵ Adverse events during treatment are common and include headache, dizziness and gastrointestinal symptoms. Corticosteroids are frequently used in children with multiple neurocysticercosis lesions because of the possibility of cerebral oedema after drug-induced cyst death. The drug of choice is either dexamethazone 0.5 mg/kg/day or prednisone 1 mg/kg/day 24 hours before anthelmintic treatment and for the duration of such treatment. There is some evidence that corticosteroids reduce adverse effects associated with albendazole. Children presenting with single lesions do not require steroid cover.

There is consensus that anti-epileptic therapy is indicated in all children with symptomatic seizures and carbamazepine is the drug of choice. The starting dosage is 5 mg/kg/day in 2 - 3 divided doses, increasing by increments of 5 mg/kg/day, if clinically indicated, to a recommended dosage of 15 - 20 mg/kg/day in 2 - 3 divided doses. Often therapy can be withdrawn after 6 months if the child remains seizure free. In such cases, repeat imaging is not recommended. If seizures recur after the acute phase of inflammation and involution of the cyst, a diagnosis of epilepsy should be considered, and anticonvulsant therapy should continue until a 2-year seizure-free period has elapsed.

References available at www.cmej.org.za

Approach to headaches in children

REGAN SOLOMONS, MB ChB, DCH (SA), MMed (Paed), Cert Paed Neur (SA)

Consultant Paediatric Neurologist, Tygerberg Children's Hospital, Department of Paediatrics and Child Health, Faculty of Health Sciences, Stellenbosch University

JOHAN SCHOEMAN, MB ChB, MMed (Paed), FCPaed (SA), MD

Professor and Head, Paediatric Neurology, Tygerberg Children's Hospital, Department of Paediatrics and Child Health, Faculty of Health Sciences, Stellenbosch University

RONALD VAN TOORN, MB ChB, MRCPCH (UK), FCPaed (SA), Cert Paed Neur (SA)

Consultant Paediatric Neurologist, Tygerberg Children's Hospital, Department of Paediatrics and Child Health, Faculty of Health Sciences, Stellenbosch University

Correspondence to: R Solomons (regan@sun.ac.za)

Headache is a common problem in childhood – up to 25% of schoolchildren suffer from chronic, recurrent headaches. Although primary headaches are far more common than those with a secondary cause, it is the latter that result in the most anxiety for families.¹ A logical approach to investigating and managing headaches is needed.

Classification

According to the *International Classification of Headache Disorders*, 2nd ed., headaches are divided into those with primary and those with secondary causes. Primary headaches occur independently of any other medical condition, while secondary headaches are directly attributed to an underlying medical cause.²

History

A detailed history is vital to identify the characteristics of the headache and to exclude secondary causes. Pertinent questions that need to be answered are set out in Table I.¹

Examination

The general examination should include vital signs, including blood pressure and temperature. Meningitis should be excluded in all children with pyrexia. The skin must be examined for features of neurocutaneous syndromes. An increased head circumference may be a reflection of chronically raised intracranial pressure. Exclusion of other non-neurological causes entails examination of the ears, nose and throat (ENT), sinuses, teeth, temporomandibular joint and cervical spine. It is useful to evaluate visual acuity by means of a Snellen's chart to exclude refractive errors that may cause headache.

More about

In addition to measuring the head circumference, clues in the neurological examination that indicate a secondary cause would include depressed or altered level of consciousness, meningism, papilloedema (useful in older children to confirm raised intracranial pressure) and focal signs, including cranial nerve palsies and hemiparesis. Headache associated with papilloedema and an abducens palsy as the only abnormal neurological finding is a common presentation of benign intracranial hypertension.

In the majority of children presenting with headache the neurological examination will be completely normal.

Investigations

Investigations should be guided by the history and clinical findings. Most headaches are idiopathic in nature. Brain tumour is a rare cause of headache in children – the incidence is 3 - 5 per 100 000, and of these only 10% will present with headache as the only symptom. Therefore, for every child with a brain tumour presenting with headache as the only feature, there are at least 50 000 children with recurrent headache.² Investigating all children with chronic headache and a normal neurological examination by computed tomography (CT) scanning of the brain is therefore not a feasible option. Neuro-imaging is nevertheless indicated in certain

situations (Table II). Magnetic resonance imaging (MRI) is the neuro-imaging of choice, but in resource-limited settings CT is the logical alternative.

Management of primary headache

The management of headaches in children demands a multidisciplinary approach involving the general practitioner or paediatrician, schoolteacher, dietician and psychologist. Additionally, input from the family is essential to ensure successful treatment of a condition as complex as childhood headache. Management comprises both pharmacological and non-pharmacological approaches. Keeping a headache diary is

Table I. Pertinent questions when evaluating a child with headache

Question	Clinical features	Likely diagnosis	Management pointer
When did the headache start?	Acute, non-progressive	Local cause	Not pathological, analgesics
	Acute, evolving	Possible brain tumour	Refer, neuro-imaging
	Chronic	Migraine	Non-pharmacological and pharmacological approaches
What is the pattern of headache?		Tension-type headache	Analgesics
	Intermittent	Migraine	Non-pharmacological and pharmacological approaches
	Worsening	Intracranial pathology	Refer, neuro-imaging
What is the headache frequency?	Chronic, non-progressive	Tension-type headache	Analgesics
	Daily to few times a week	Tension-type headache	Analgesics
	Weekly to monthly	Migraine	Non-pharmacological and pharmacological approaches
Do the headaches occur at a specific time?	Clusters of few times a week for a few weeks, long asymptomatic periods	Cluster headache	Analgesics
	Night or early morning	Migraine	Non-pharmacological and pharmacological approaches
Is an aura or prodrome present?		Raised intracranial pressure	Refer, neuro-imaging
	Present	Migraine	Non-pharmacological and pharmacological approaches
Where is the pain?		Intracranial pathology	Refer, neuro-imaging
	Unilateral persistent	Secondary cause	Refer, neuro-imaging
	Bifrontal	Migraine	Non-pharmacological and pharmacological approaches
Are there any associated symptoms?	Diffuse	Tension-type headache	Analgesics
	Intermittent nausea, vomiting, photophobia	Migraine	Non-pharmacological and pharmacological approaches
	Persistent nausea, vomiting, photophobia	Intracranial pathology	Refer, neuro-imaging
Are there any aggravating or relieving factors?	Relief with analgesics	Migraine, tension-type headache	Non-pharmacological and pharmacological approaches
	Relief with sleep	Migraine	Non-pharmacological and pharmacological approaches
	Worsened by light, noise, activity	Migraine	Non-pharmacological and pharmacological approaches
	Worsened by lying down	Raised intracranial pressure	Refer, neuro-imaging

Table II. Indications for neuro-imaging in children with headache

1. Abnormal neurological examination (focal neurological signs, abnormal eye movements, ataxia, hemiparesis, papilloedema)
2. Headache characteristics, such as headache on awakening; headache always occurring on the same side of the head; headache with change of posture/sneezing/coughing; unusual location (occipital headaches); headache causing sleep interruption; worst headache of life, chronic-progressive pattern
3. Deterioration in school-work and personality change
4. Presence of ventriculoperitoneal shunt
5. Presence of neurocutaneous features
6. Headache in child under 3 years of age

useful, as it provides information regarding the pattern and frequency of headaches and response to interventions. Important non-pharmacological strategies involve good sleep hygiene, regular exercise, decreasing the amount of caffeinated drinks and relaxation methods. Obtaining a history can be difficult in young children.^{3,4} Therefore, their drawings may be very useful in the diagnosis of headaches in children. In a large study, identification of elements of children's drawings enabled differentiation between migraine, tension-type headache and other headaches (Figs 1 and 2).⁵ Diet may also play an important role in childhood headaches and is often ignored as a therapeutic option. Foodstuffs that can trigger headaches include cheese, chocolate, citrus fruits, monosodium glutamate, aspartame, ice-cream and alcohol. A headache and diet diary should be kept, and foods presumed to trigger attacks must then be excluded. However, eliminating all potential food triggers is generally not advised and a well-balanced diet is encouraged.⁶

The aim of acute pharmacological treatment is a rapid return to normal function with minimal side-effects.⁷ Ibuprofen 10 mg/kg/dose was shown to be superior to placebo^{8,9} and equivalent to acetaminophen 15 mg/kg/dose in the management of migraine in children.⁸ If non-steroidals are not effective, serotonin-receptor agonists are an option. Nasal sumatriptan 10 mg (20 - 39 kg) and 20 mg (>39 kg) has been shown to be effective in an 8 - 17-year age group, as was rizatriptan 5 mg (20 - 39 kg) and 10 mg



Fig. 1. Drawing by a child with migraine.

(>39 kg) in this age group.^{10,11} Analgesic headache occurs when drugs given for the treatment of headache aggravate headache symptoms. The condition is recognised in children and may even be induced by mild analgesics such as paracetamol used in isolation. The diagnosis is confirmed when abrupt withdrawal of analgesic drugs leads to headache resolution.¹²

Prophylactic therapy should be reserved for children with frequent headaches that interfere with daily lifestyle and result in functional disability. Prospective, randomised, controlled trials evaluating



Fig. 2. Drawing by a child with tension-type headache.

preventive treatment in children with migraine are scanty. The few studies published are hampered by placebo response rates as high as 50%. Therapeutic options most often used include: amitriptyline 10 - 25 mg at night, sodium valproate 20 mg/kg/day given as either a single dose or 2 divided doses, topiramate 1 - 4 mg/kg/day (100 - 200 mg/day) in 2 divided doses, propranolol 2 - 4 mg/kg/day (10 - 40 mg three times daily) and levetiracetam 20 - 40 mg/kg/day in 2 divided doses. These therapeutic options are based on small studies, and the definitive agent has yet to be identified.

References available at www.cmej.org.za