

Table I. Evidence-based recommendations from the American Academy of Orthopaedic Surgeons²

- Asymptomatic tears do not require surgery
- There is weak evidence for early repair of traumatic tears
- Surgical outcomes are worse with increasing age, workman's compensation cases and where the MRI findings show significant fatty changes and atrophy
- Routine acromioplasty with repair is not proven
- Weak evidence that debridement for massive tears gives adequate long-term relief
- No difference in outcomes with different surgical techniques (open surgery or arthroscopic)
- Exercise and NSAIDs work in patients with impingement
- Porcine grafts do not work in rotator cuff tears

Table II. No evidence to support or refute these recommendations

- Exercise programmes in the treatment for rotator cuff tear
- NSAIDs and other forms of conservative treatment in rotator cuff tears
- The role of cortisone in patients with a tear or impingement
- Outcomes are worse in smokers and those with diabetes or spinal problems
- Xenograft or allograft material used in repairs

Table III. Poor prognostic factors for conservative treatment

- Tears greater than 1 cm
- Symptoms longer than 1 year
- Severe weakness or functional impairment on initial presentation
- Bilateral rotator cuff tears
- Decreased active ROM preoperatively also has been associated with poor outcome after operative treatment of rotator cuff tear
- Steroid injections preoperatively have a higher failure rate after surgery

medicine available was published earlier this year.² Table I lists their recommendations where there is evidence in the literature.² Table II lists situations where there is no convincing evidence either way.² Table III lists the poor prognostic factors for conservative treatment.³

The above paper and Wolf's review paper summarises what most surgeons are practising.³ These reviews suggest that symptomatic tears can be safely treated conservatively for 6 - 12 weeks, unless there is weakness on examination, bilateral tears,

symptoms of more than a year or tear size less than 1 cm. There is evidence for early repair if there is trauma. Multiple steroid injections are detrimental.

The biological approach

As genetic influences on the development of tears have been recognised, research is now directed to using this as an intervention. The approach to preventing failed rotator cuff surgery is now being directed to biological strategies at the cellular and molecular level. The reason for this is that despite the mechanical approach of surgery with improved sutures, anchors, surgical technique and grafts there still remains failure of tendon healing of 11 - 94%.⁴

Professor Andrew Carr's group from Oxford has shown that in patients with a painful rotator cuff tear, 62% of their siblings had a tear when compared with 22.1% in the control group. They also showed the rate of progression of the tear was 16.1% in the sibling group, compared with 1.5% in the control group.⁵ Does this mean that patients who have a family history should have earlier surgery to prevent progression?

Lawrence started their research by using mesenchymal cells in a rat model, but found no difference in healing rates. These rates improved once these cells were genetically modified (transduced with adenoviral mediated scleraxis) by a transcription factor that is believed to direct tendon development during embryogenesis.⁶

At the molecular level, Millar and his group have shown in a rodent model of tendinopathy that there is upregulation of pro-inflammatory cytokines and apoptotic genes. They also showed significantly increased levels of cytokine and apoptotic genes in human supraspinatus and subscapularis tendon harvested from patients with rotator cuff tears. This allows research to be directed at neutralising the cytokines by using antibodies, etc.⁷

Kovacevic and colleagues carried out a review in which they looked at their own results using bone morphogenic proteins (BMPs) and at other investigators' use of biological interventions, confirming improved healing and strength in the tendons of rats and sheep.⁸ These are now being applied in clinical studies with a Level 1 study looking at platelet-rich plasma (PRP), which showed reduced pain in the first postoperative month and improved healing in grade 1 and 2 tears.⁹

As one can see from the above, we are possibly reaching a ceiling with respect to mechanical treatment of rotator cuff tears and that the future belongs to a biological solution to guarantee a successful repair.

References available at www.cmej.org.za

Testing for elbow instability

STEPHEN JL ROCHE, MB ChB, LMCC, FCS (SA) Orth

Head, Shoulder and Elbow Unit, Princess Alice Orthopaedic Unit, Groote Schuur Hospital, Orthopaedic Trauma Consultant, Groote Schuur Hospital and Senior Lecturer, Department of Orthopaedics, University of Cape Town

BASIL C VRETTOS, MB ChB, FRCS (Eng), FCS (SA) Orth, MMed (Orth)

Honorary Consultant, Shoulder and Elbow Unit, Department of Orthopaedic Surgery, University of Cape Town

Correspondence to: Stephen Roche (sroche@iafrica.com)

The elbow is one of the most stable joints due to the congruity of the articular surfaces and the soft tissues, which consist of the medial and lateral collateral ligaments (MCL and LCL) and muscles crossing the elbow.^{1,2}

Unlike in the shoulder, the ligaments tend to heal well following dislocations and therefore recurrent instability is unusual. However, it is postulated that the LCL does not heal quite as well as the MCL following trauma and lateral instability is therefore less rare than the medial side. This results in posterolateral rotatory instability, where the radial head subluxes posteriorly off the capitellum. Iatrogenic injury and subsequent instability may also occur following surgery, for example tennis elbow release.^{1,3}

History

Medial collateral ligament insufficiency usually presents with pain. Patients will complain of medial sided elbow pain when throwing or with similar type actions. In acute injuries patients often feel a sharp pain

More about

with a snap or pop of the ligament. There may be ulnar nerve symptoms as it is in close proximity.³

It is important to ascertain whether there has been previous elbow trauma or surgery, especially with regard to the LCL. There may be clicking, catching or occasionally a feeling of instability. They seldom complain of dislocation. They have difficulty pushing themselves out of a seat and other activities such as pushing open a heavy door.

Physical examination

Scars from previous trauma or surgery should be looked for. There usually is tenderness of the ligament involved.

Assessing the collateral ligaments requires the elbow to be flexed to 20 - 30° to relax the anterior capsule and bring the olecranon out of the fossa. Varus stress is best applied to the humerus in full external rotation. The valgus test is best examined with the arm in 10° of flexion and internal rotation.²

The milk test (Fig. 1) is the provocative test for the MCL; it is a modification of the moving valgus test.⁴ The patient's thumb is held by the examiner, with the forearm in full supination while a valgus force is applied to the radial side of the elbow. The examiner's thumb feels the medial collateral ligament (just distal to the medial epicondyle) and the elbow is taken through full flexion and extension. The maximum pain is usually between 70° to 120° and usually disappears at 30° of extension as the olecranon enters into the fossa. Opening of the joint line may occur. Careful examination of the ulna nerve is necessary as this may also be irritated. Medial epicondylitis should be excluded.

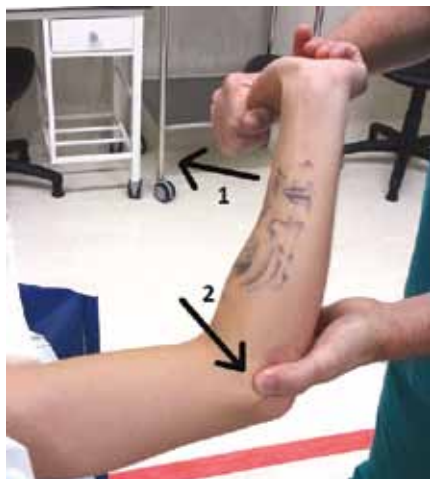

Fig. 1. Milk test. The patient's thumb is pulled radially to put stress on the MCL (arrow 1). The examiner's thumb is over the MCL while applying a valgus force (arrow 2). The elbow is taken through a full range of motion to elicit pain in the mid arc.

Three main tests for lateral collateral ligament instability have been described.

Posterolateral rotatory drawer test (Fig 2)

The patient lies supine with the shoulder flexed to 90°. The forearm is held in supination and the elbow is flexed between 45° and 90°. As with an anterior drawer test of the knee, the radius and ulna are distracted away from the distal humerus. The patient may feel apprehension or pain. The examiner's thumb over the radial head will feel the subluxation of the radial head.⁵

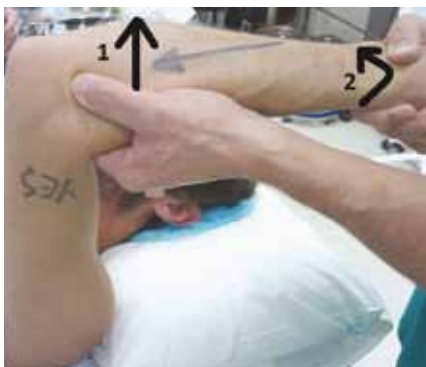

Fig. 2. Posterolateral rotatory drawer test. A distractive force is applied to the elbow (arrow 1) with the forearm in supination (arrow 2), while palpating the radial head to see if there is subluxation.

Posterolateral rotatory pivot shift test (Fig. 3)

The patient is examined in the same position with the arm flexed up to 90° and full supination of the forearm. An axial load along the arm and a valgus directed force is applied to the elbow. The elbow is now extended from full flexion. As the elbow reaches approximately 45° of flexion the radial head will sublux. As it is flexed up it will reduce again. This subluxation may be palpated by the thumb (Fig. 3) or visualised as dimpling of the skin between the radius and the capitellum. This examination may be difficult in the awake patient and very often needs to be done under anaesthetic.

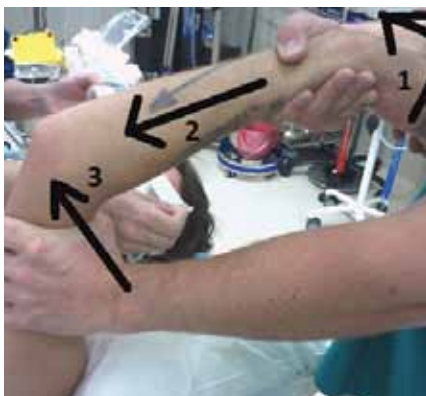


Fig. 3. Posterolateral rotatory pivot shift test. The forearm is held in full supination (arrow 1), an axial load along the arm (arrow 2) is applied while the examiner's hand applies a valgus force (arrow 3). The elbow is now flexed and extended. The subluxation of the radial head is palpated and/or visualised at about 45°.

Apprehension tests

There are 3 variations of the same test. The *chair sign* involves the patient pushing himself up from the chair handles with the forearm in full supination (Fig. 4). The other two are the *tabletop test*, where the edge of the table is substituted for the chair and the *push up sign*, where a press up is done with the forearm in supination. These are positive if there is pain or a feeling of apprehension/subluxation.^{6,7}

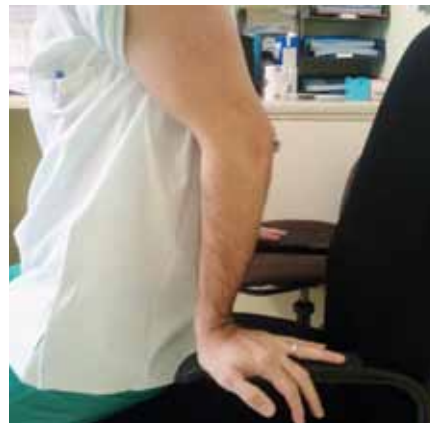


Fig. 4. Chair test. The patient is asked to push out of the chair with hands and forearm in supination, as shown.

X-rays are generally unhelpful unless they are stress X-rays. It is considered diagnostic if there is more than 2 mm opening up of the joint line. MRI is not reliable if negative and therefore examination under anaesthesia is necessary if there is doubt regarding the diagnosis.^{1,4,5,8,9}

References available on www.cmej.org.za