

# Glaucoma

**Glaucoma is a major global cause of irreversible blindness.**

SUSAN E I WILLIAMS, MB BCh, FCOphth (SA), FRCS (Edin)

Consultant Ophthalmologist, St John Eye Hospital, Ophthalmology Department, Chris Hani Baragwanath Hospital, Johannesburg

Susan Williams qualified as a specialist at the end of 2001. She has been a consultant at the St John Eye Hospital for 5 years, and lectures in the Department of Ophthalmology at the University of the Witwatersrand. Her main interest is in glaucoma but particularly in glaucoma surgery.

Glaucoma, a major cause of worldwide irreversible blindness, is a progressive optic neuropathy that is characterised by specific structural changes to the optic nerve head and associated functional (visual field) changes. This particular neuropathy involves apoptosis of the retinal ganglion cells whose axons comprise the optic nerve. The pathogenesis of this apoptosis is poorly understood, but it is thought to be a cascade set in motion by mechanical factors (elevated intraocular pressure (IOP)) or vascular factors or a combination of these two factors (Fig. 1).

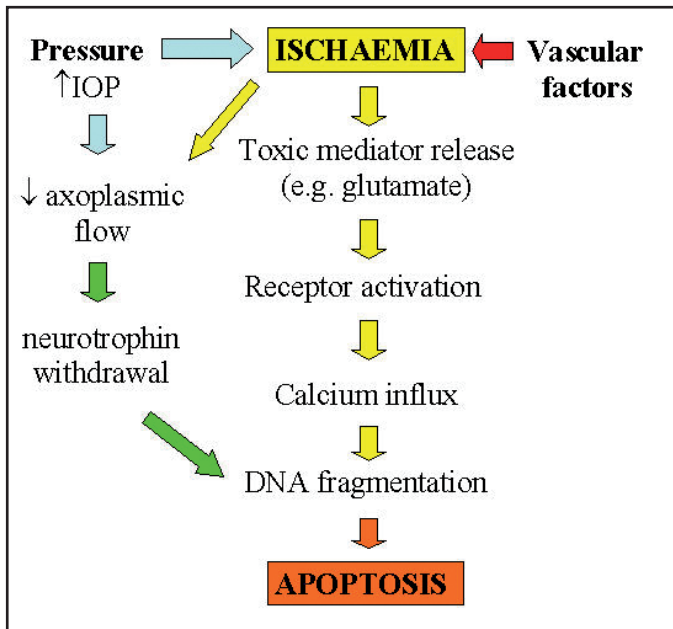


Fig. 1. The pathogenesis of apoptosis in glaucoma.

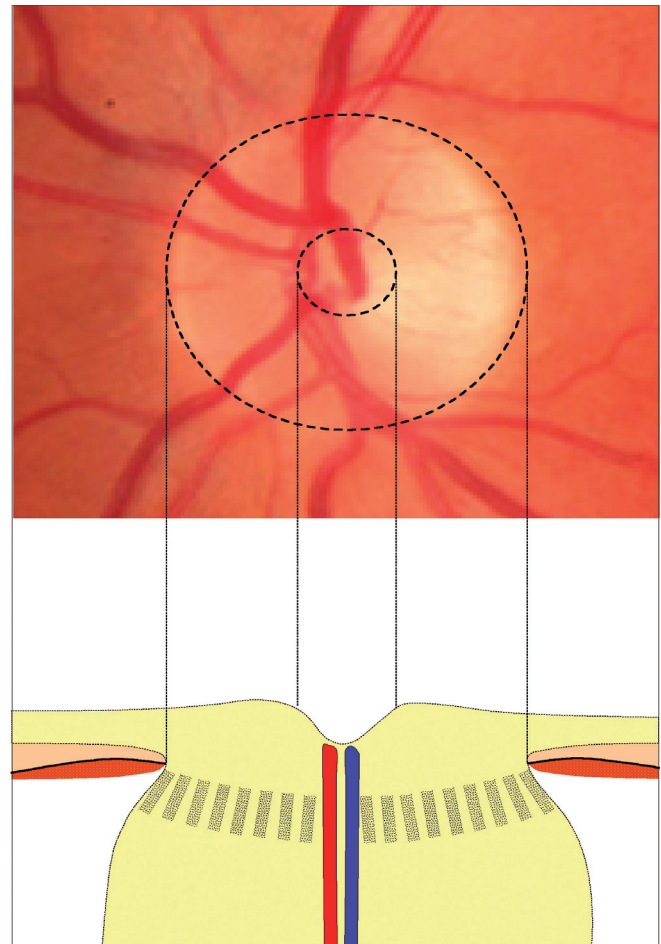


Fig. 2. Normal optic disc with a schematic cross-section demonstrating the central cup.

## Diagnosis of glaucoma

The diagnosis of glaucoma is made when both the functional and the structural changes that are the consequence of this apoptosis can be demonstrated.

### Structural changes in glaucoma

In cross-section the optic nerve head (optic disc) has a central depression where the retinal vessels enter the eye. This is known as the 'cup' (Fig. 2). As peripheral nerve fibres are lost in glaucoma, so the remaining fibres take their places, leaving a larger 'cup' (Fig. 3).

With progressive axonal loss there is progressive 'cupping' of the optic nerve head, the end result of which is the fully cupped disc – the disc with cavernous optic atrophy (Fig. 4).

Cupping of the optic disc may be appreciated on fundoscopy as an area of central pallor. The degree of cupping is measured as a ratio of the cup size to the disc size (Fig. 5).

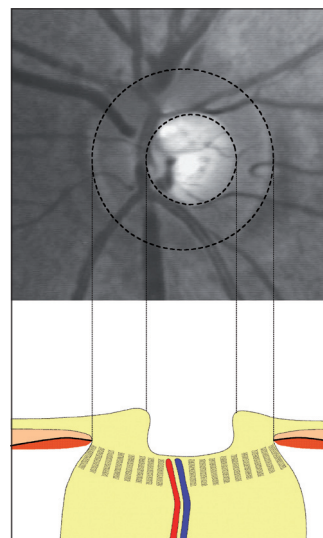


Fig. 3. Moderate cupping of the optic disc.

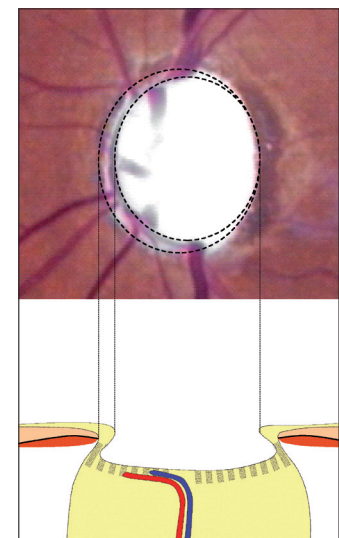


Fig. 4. Cavernous optic atrophy – fully cupped disc.




Fig. 5. A disc with a cup: disc ratio of 0.5.

Because some degree of cupping is normal and because some people have physiologically enlarged cups, the following general guidelines apply. Cupping is suspicious if:

- the cup/disc ratio is greater than 0.5
- the vertical cup/disc ratio is greater than the horizontal cup/disc ratio
- there is asymmetry between the cup/disc ratios of the two eyes of more than 0.2.

While it is possible to assess cupping subjectively on fundoscopy, it is preferable to have an objective assessment that allows proper evaluation of progression.

Objective assessments can be made with colour photography, stereoscopic photography, optical coherence tomography (OCT – high-resolution, cross-sectional imaging of the retina using optical technology analogous to ultrasonography) (Fig. 6), and confocal scanning laser ophthalmoscopy (Heidelberg Retina Tomograph or HRT).<sup>1</sup> These last two special investigations can also evaluate the thickness of the retinal nerve fibre layer (RNFL) surrounding the optic disc. The thinning of the peripapillary RNFL is a sensitive indicator of glaucomatous axonal loss. This can also be assessed using scanning laser polarimetry (Nerve Fiber Analyser or GDx VCC) (Fig. 7).

The diagnosis of glaucoma cannot be made on the basis of structural changes alone. The diagnosis rests on demonstrating the structural change in combination with a congruous functional change.

### Functional changes in glaucoma

The axonal loss that is the hallmark of glaucoma begins with axons in the periphery of the nerve. These axons have their origins in the retinal ganglion cells in the retinal mid-periphery with consequent visual field fallout in these regions. These ‘scotomas’ that develop in the visual field often go unnoticed by the patient. Formal automated perimetry (visual field testing) is the best way of detecting these defects. In this type of testing the patient is presented with targets of differing intensity at different

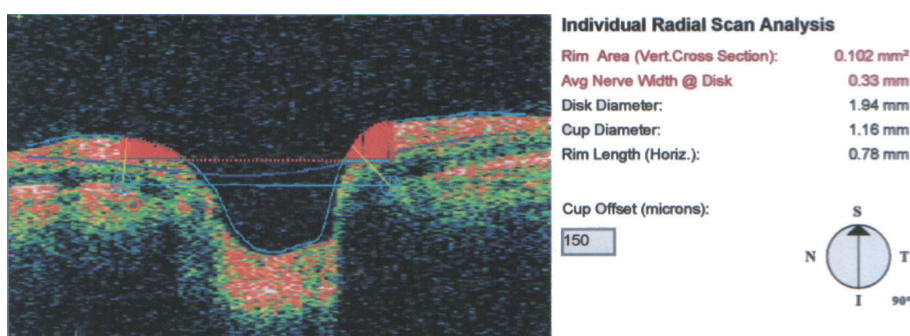


Fig. 6. OCT of the optic nerve head showing the cup.

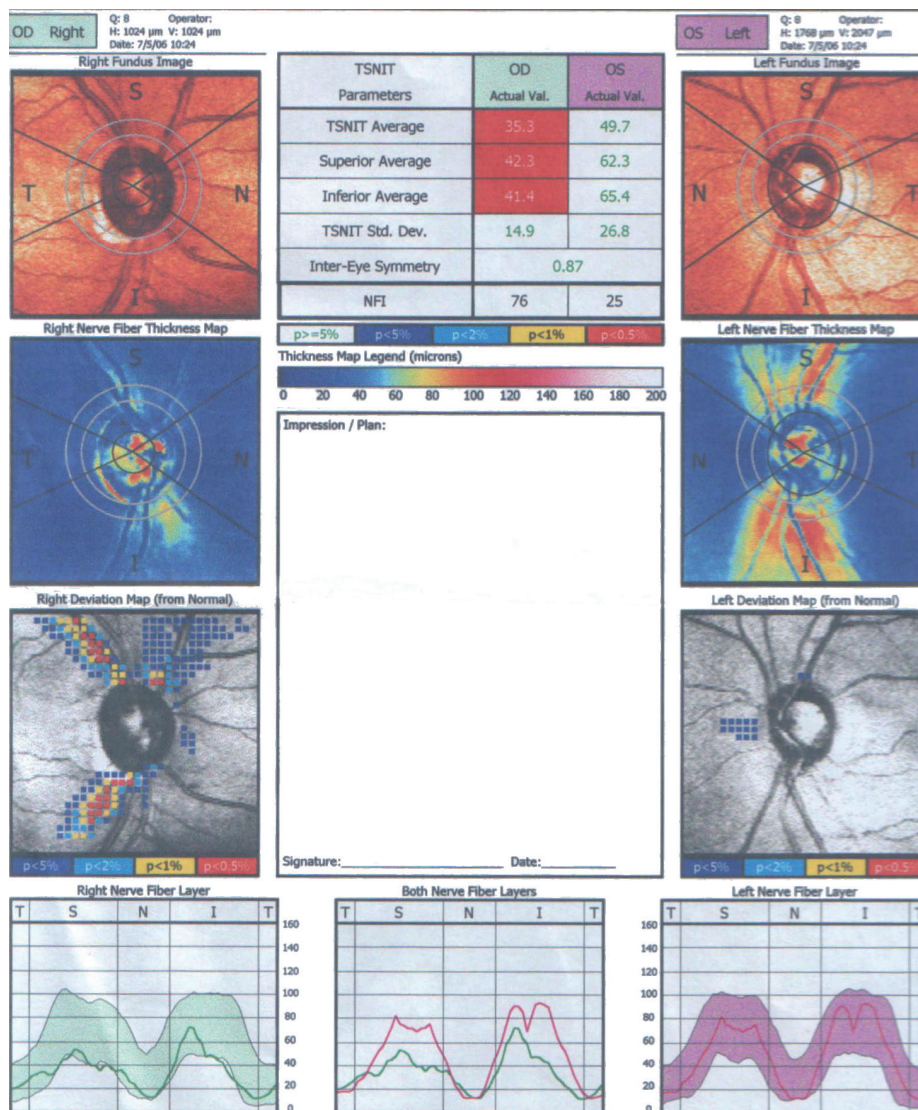


Fig. 7. Gdx showing thinning of the RNFL in the right eye.

points within their visual field. The end result is a printout of their visual threshold at these different points (Fig. 8). A quick way of assessing the visual field is to look at the grey-scale representation of the field (Fig. 9). The normal visual field is described as a ‘hill’ of vision with the best acuity at fixation tailing out to the periphery. The ‘blind spot’ corresponds to the optic nerve head and is at about 15 degrees temporal to the point of fixation.

In glaucoma there is initially an enlargement of the blind spot followed by mid-peripheral ‘arcuate’ scotomas (Fig. 10). These cross the vertical midline (distinguishing them from neurological deficits) and may be in the

superior or inferior hemispheres or both. In end-stage glaucoma the patients have tunnel vision when all but the central area of fixation is involved (Fig. 11). At this advanced stage, despite the enormous visual field fallout, the patient may still have a normal visual acuity as tested on a Snellen chart!

This type of testing has limitations:

- it is subjective
- it requires concentration and is tiring
- it does not detect early damage.

For these reasons the following tests have been developed:



## Glaucoma

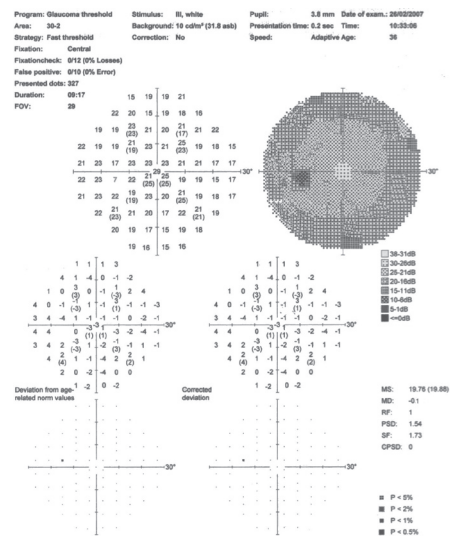


Fig. 8. A normal field on automated perimetry.

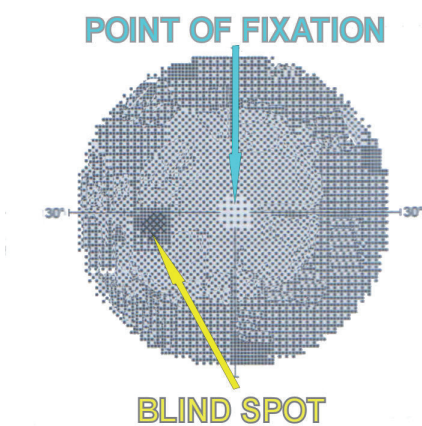


Fig. 9. Grey scale view of a normal field.




Fig. 10. A superior arcuate scotoma.

- short wavelength automated perimetry (SWAP) which uses a blue on yellow stimulus to pick up early defects<sup>1</sup>
- frequency doubling technology (FDT) which is a shorter test and uses a flickering sinusoidal grating as a target, and may detect earlier damage<sup>1</sup>
- multifocal visual evoked potentials (mVEP) use multiple recording channels to detect signals from all areas of the visual field to provide an objective map of visual function.<sup>2</sup>

The field losses are significant if they occur in the context of a cupped disc and if the degree of visual field defect corresponds with the degree of cupping. Both structural and




Fig. 11. Tunnel vision.

functional tests are invaluable in following patients with established glaucoma to assess progression, the rate of progression and/or the response to treatment.

### Intraocular pressure

So where does intraocular pressure (IOP) fit in? IOP takes no part in the diagnosis of glaucoma. In fact one may have glaucoma in the absence of a raised pressure (normal tension glaucoma) and a raised pressure without glaucoma (ocular hypertension). IOP is, however, still very important in glaucoma because it is the most important risk factor for glaucoma. In addition, lowering the IOP is currently the only way we have to treat glaucoma.

### Determinants of IOP (Fig. 12)

IOP is determined by the dynamics of aqueous humour production and outflow. Aqueous humour is produced by the ciliary body and flows over the lens into the anterior chamber of the eye. The trabecular meshwork lies circumferentially in the angle of the eye and 90% of aqueous exits the eye via this fine network of fibres into the canal of Schlemm, which connects to the episcleral venous circulation via aqueous veins. The remaining aqueous leaves the eye directly via uveoscleral outflow. Aqueous production is usually constant, so a raised IOP is usually the result of increased resistance to outflow at the level of the trabecular meshwork.

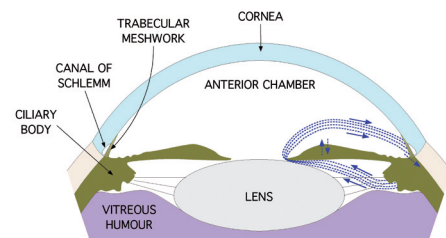


Fig. 12. The drainage angle of the eye demonstrating aqueous humour dynamics.

### Measuring IOP

The Goldmann tonometer (a slit-lamp mounted tonometer) is the gold standard for IOP measurement. It uses the principle of Fick's Law (IOP equals the force divided

by the area of application of that force) assuming that the eye is a perfect sphere. The air-puff tonometer used by optometrists works on a similar principle.

A normal IOP (based on population studies) is one between 8 and 21mmHg.

## Treatment of glaucoma

In theory there are a number of potential ways to treat glaucoma:

- **Neuroprotection.** This is the ideal treatment for a neuropathy and thus there is active research into neuroprotective agents for the treatment of glaucoma.<sup>3</sup> A prospective, placebo-controlled, multi-institutional trial of memantine (an NMDA antagonist) in glaucoma is currently underway.
- **Increasing ocular blood flow.** There is strong evidence that ocular blood flow alterations are present in patients with glaucoma, but there is no gold-standard method for its measurement.<sup>4</sup> This makes it difficult to prove that any agent can successfully increase the blood flow. This is still an area of active research.
- **Decreasing the IOP.** In practice this is the only way we currently have to treat glaucoma. This may be accomplished medically, with the use of lasers or surgically.

### Principles of glaucoma treatment

Glaucoma treatment is individualised. The first step is to set a target IOP based on the patient's age, the presenting IOP and how advanced the disease is. In general the IOP should be decreased by about 30% and should be below 18 mmHg at all times. The more advanced the disease, the lower the target IOP should be. Once therapy has been instituted the patient needs to be followed for progression. If there is progression, the target IOP needs to be lower. Usually a stepwise approach is used, beginning with medical therapy and progressing to surgical treatment only when this fails.

### Medical therapy (Fig. 13)

Acetazolamide is the only systemic treatment available for glaucoma. It is very useful in acute settings and may be used intravenously, intramuscularly and orally. The disadvantage is the numerous systemic side-effects the most common of which are malaise, gastrointestinal symptoms and paraesthesias.

The topical agents may be used alone or in combination to achieve maximum IOP lowering. Several fixed combination agents are available which improve compliance in patients on dual or triple therapy. Most of the agents have few systemic side-effects.

The group of beta blockers is a notable exception. Despite being topical agents these are well absorbed by the nasal mucosa and have the same side-effect profile as their oral counterparts. They are very effective anti-glaucoma agents and are commonly used, so the cardiac and pulmonary complications occur with regularity.

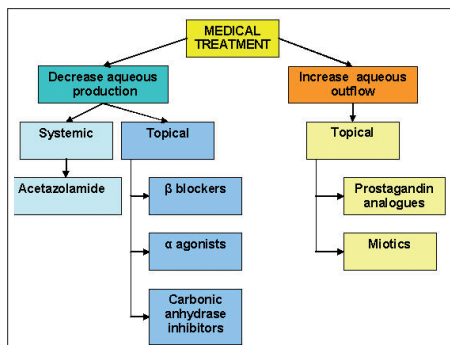


Fig. 13. Medical therapy for glaucoma.

### Laser therapy

Aqueous outflow may be enhanced by modifying the trabecular meshwork in laser trabeculoplasty.

Aqueous production is diminished by damaging the ciliary processes in diode laser cyclophotocoagulation for refractory glaucoma.<sup>5</sup>

### Glaucoma surgery

The rationale for glaucoma surgical procedures is to bypass the trabecular meshwork.

In a trabeculectomy (the most widely performed incisional glaucoma surgery worldwide<sup>5</sup>) a partial thickness flap is formed in the sclera (Fig. 14). Deep to this flap a sclerostomy is cut into the anterior chamber. A peripheral iridectomy completes an uninterrupted fistula for aqueous to pass from the ciliary body into the anterior chamber and then into the subconjunctival space where a 'bleb' of aqueous fluid forms (Figs 15 and 16).

Other glaucoma surgical procedures (including glaucoma drainage devices) use similar principles.

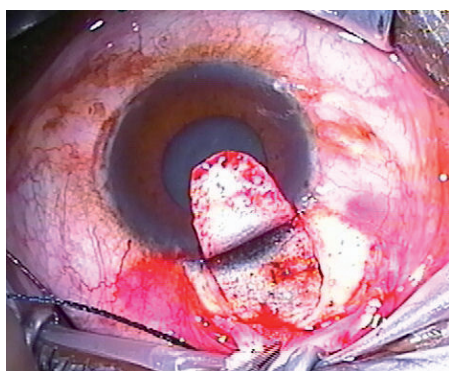


Fig. 14. Scleral flap construction during a trabeculectomy.

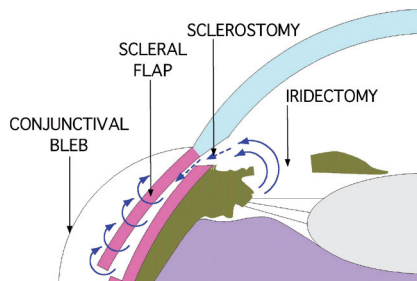


Fig. 15. The anatomy of a trabeculectomy.

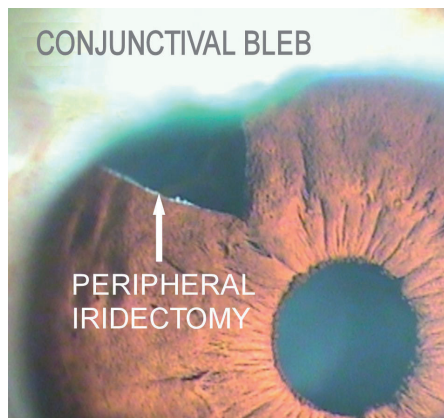


Fig. 16. A trabeculectomy postoperatively.

### Types of glaucoma

Glaucoma may be broadly classified into four groups – primary open-angle glaucoma (POAG), angle-closure glaucoma (ACG), secondary glaucoma and congenital glaucoma.

#### Primary open-angle glaucoma

POAG, the commonest type of glaucoma, typically begins in the fourth to sixth decade and affects both sexes equally. It is symptomless and is usually picked up on routine screening. There is often a family history of glaucoma. It is a bilateral, although usually asymmetrical disease. The diagnosis is made by demonstrating progressive functional and structural changes to the optic nerve in the absence of a secondary cause. The IOP may or may not be elevated. In addition, the drainage angle of the eye is visualised (gonioscopy) with a mirrored contact lens (gonioscopic lens). In an 'open' angle the trabecular meshwork is visible in the mirrored portion of the lens (Fig. 17).

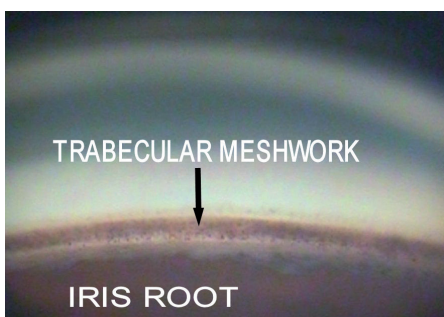


Fig. 17. Gonioscopic view of the angle of the eye.

#### Angle-closure glaucoma

On gonioscopy these patients have a 'closed' drainage angle – the trabecular meshwork is not visible because it is obscured by the peripheral iris. This can cause chronically elevated IOPs, in which case it presents similarly to POAG. A clinically completely different picture arises in acute-angle closure.

#### Acute-angle closure

This occurs in patients with anatomically narrow anterior segments. As these patients age, so their lenses increase in size. In this setting they may develop relative 'pupil block' when the pupil is in the mid-dilated position as occurs in dim lighting or may be precipitated by pharmacological pupil dilatation or by systemic drugs (Table I).<sup>6</sup>

Table I. Systemic drugs and angle closure <sup>6</sup>
• Phentothiazines and their derivatives
• Tricyclic and non-tricyclic antidepressants
• Monoamine oxidase inhibitors
• Topiramate
• Antihistamines
• Antiparkinsonian drugs
• Parasympatholytic agents
• Sympathomimetic agents

Fig. 18 demonstrates how this can occur – the pupil comes to rest on the lens, blocking the flow of aqueous into the anterior chamber. Aqueous then collects behind the iris, causing this to bulge forwards and block off the trabecular meshwork. The result is a dramatic and sudden increase in the IOP over minutes to hours causing excruciating pain, headache, nausea and vomiting and an associated red, angry eye with corneal oedema and a diminished visual acuity. This is a medical emergency.

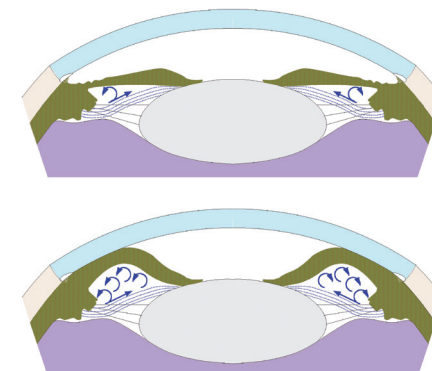


Fig. 18. The dynamics of pupil block in acute-angle closure.



## Glaucoma

### Treating acute angle closure

The first priority is to decrease the IOP. This can be achieved with 500 mg acetazolamide IVI stat, followed by 500 mg oral acetazolamide. Analgesics and anti-emetics may also be required. The patient should then be referred to an ophthalmologist who may perform a laser peripheral iridotomy. By creating a hole in the peripheral iris, aqueous is allowed into the anterior chamber, restoring the iris anatomy and aqueous outflow channels to normal. The definitive treatment may be cataract surgery to replace the enlarged lens with an intraocular lens, thus preventing the situation from occurring again.

### Secondary glaucoma

Any process disturbing the functioning of the trabecular meshwork will increase the IOP and may cause secondary glaucoma. Some of the commoner examples of this (there are numerous causes) are:

- uveitic glaucoma – peripheral anterior synechiae form between the iris and the peripheral cornea ‘closing’ the drainage angle

- rubeotic glaucoma – neovascularisation of the iris secondary to retinal ischaemia begins in the angle, causing an elevated IOP
- traumatic glaucoma – blunt trauma to the eye may tear the iris root and damage the trabecular meshwork.

### Congenital glaucoma

Some infants have congenitally abnormal drainage angles which may be unilateral or bilateral. The elevated IOP that this causes produces not only an optic neuropathy, but also an enlarged eye (buphthalmos) because the sclera and cornea are still elastic in infants. The cornea may also become opacified. Treatment of congenital glaucoma is predominantly surgical to open the drainage angle and decrease the IOP.

### Acknowledgements

I'd like to thank Julia Williams for her assistance with drawing the diagrams, and Tebogo Maleka for helping me with disc photography.

### References

1. Association of International Glaucoma Societies. Weinreb RN, Greve EL, eds. *Glaucoma Diagnosis – Structure and Function*. The Hague: Kugler Publications, 2004.
2. Graham SL, Klistorner AI, Goldberg I. Clinical application of objective perimetry using multifocal visual evoked potentials in glaucoma practice. *Arch Ophthalmol* 2005; 123(6): 729-739.
3. Osborne NN, Chidlow G, Layton CJ, Wood JP, Casson RJ, Melena J. Optic nerve and neuroprotection strategies. *Eye* 2004; 18(11): 1075-1084.
4. Grieshaber MC, Flammer J. Blood flow in glaucoma. *Curr Opin Ophthalmol* 2005; 16(2): 79-83.
5. Association of International Glaucoma Societies. Weinreb RN, Crowston JG, eds. *Glaucoma Surgery – Open Angle Glaucoma*. The Hague: Kugler Publications, 2005.
6. European Glaucoma Society. *Terminology and Guidelines for Glaucoma*, 2nd ed. Savona: Dogma, 2003: Chpt 2, p.14.

## In a nutshell

- Glaucoma is an optic neuropathy.
- The diagnosis of glaucoma is made on the basis of specific structural (cupping of the optic nerve head) and functional (visual field) changes. The monitoring of progression within these changes is essential in the follow-up of patients with established glaucoma.
- Intraocular pressure (IOP) is the most important risk factor for glaucoma, but does not form part of the diagnosis of the disease.
- Reducing IOP is currently the only way we have to treat glaucoma.
- The lowering of IOP may be achieved medically (predominantly with topical therapy), with laser treatment or surgically.
- The broad categories of glaucoma are:
  - primary open-angle glaucoma
  - primary closed-angle glaucoma
  - secondary glaucoma
  - congenital glaucoma.
- Acute-angle closure is a medical emergency requiring immediate IOP lowering with acetazolamide followed by urgent referral to an ophthalmologist for laser iridotomy.