

Common eye emergencies

The acute red eye, sudden visual loss or trauma are the most common eye emergencies.

KAVITHA NAIDU, MB ChB, FCOpt

Consultant, Department of Ophthalmology, Nelson Mandela School of Medicine, KwaZulu-Natal, Durban

Kavitha Naidu qualified in 2003 as an ophthalmologist at the Nelson Mandela School of Medicine. She is currently a consultant in the Department of Ophthalmology and is based at St Aidans Hospital. Her fields of interest include ocular trauma and retinal disease and surgery, especially diabetes and uveitis.

Common eye emergencies may present as an acute red eye, sudden visual loss or acute ocular trauma. Most eye emergencies will require referral to an ophthalmologist after initial basic examination and primary management. A relevant history of onset and symptoms of the current problem must be obtained and, in the case of trauma, the exact mode and time of injury. Any relevant medical, family or previous ocular history must also be elicited.

Acute red eye

Causes of an acute red eye include conjunctivitis, keratitis, episcleritis, scleritis, uveitis and acute-angle closure glaucoma.

Acute conjunctivitis

Acute conjunctivitis may be bacterial, viral or allergy related.

Bacterial conjunctivitis

Acute bacterial conjunctivitis begins unilaterally with hyperaemia, irritation, tearing, and a mucopurulent discharge. Common pathogens include *Staphylococcus aureus*, *Streptococcus pneumoniae* and *Haemophilus influenzae*. The latter two occur commonly in children and may occur in institutional epidemics. Treatment consists of topical broad-spectrum antibiotic drops or ointments with good Gram-positive cover such as a third- or fourth-generation fluoroquinolone, or trimethoprim-polymixin. Conjunctivitis generally lasts 7 - 10 days.

Gonococcal conjunctivitis (Fig. 1) occurs primarily in neonates and sexually active young adults. Affected individuals present with

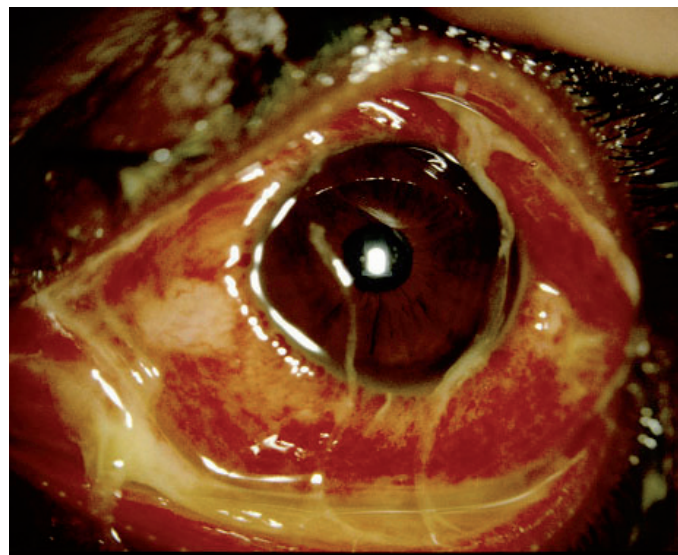


Fig. 1. Gonococcal conjunctivitis.

a painful red eye, swelling or chemosis of the conjunctiva, a profuse, thick yellow-green purulent discharge and tender pre-auricular lymph nodes. Untreated, the infection may spread to the cornea and cause peripheral corneal ulceration with eventual perforation and possible infection of the whole eye (panophthalmitis). Suspicion of this condition therefore should lead to referral to an ophthalmologist. Treatment of gonococcal conjunctivitis is with a *stat* dose of intramuscular ceftriaxone, followed by frequent instillation of topical ciprofloxacin or chloramphenicol eyedrops or penicillin, bacitracin or erythromycin ointment. This is accompanied by ocular irrigation prior to medication to remove the copious discharge. The patient and sexual contacts must also be treated with a course of oral tetracycline or erythromycin.

Viral conjunctivitis

This is an extremely common condition. It starts unilaterally and affects the second eye within 1 week, presenting with conjunctival hyperaemia, a watery discharge and pre-auricular lymphadenopathy. Most cases resolve spontaneously without sequelae within a few days to 3 weeks. Specific viruses can cause associated clinical ocular and systemic signs.

Adenovirus causes pharyngoconjunctival fever and epidemic keratoconjunctivitis. The former is characterised by a combination of pharyngitis, fever and conjunctivitis. Epidemic keratoconjunctivitis produces a more severe, extremely contagious conjunctivitis, with subconjunctival haemorrhages and ipsilateral pre-auricular lymphadenopathy and often leads to corneal involvement. Treatment is symptomatic and involves minimisation of transmission.

Acute haemorrhagic conjunctivitis presents as a painful conjunctivitis with subconjunctival haemorrhages. It tends to occur in epidemics and the conjunctivitis lasts 4 - 6 days with the haemorrhages resolving more slowly.

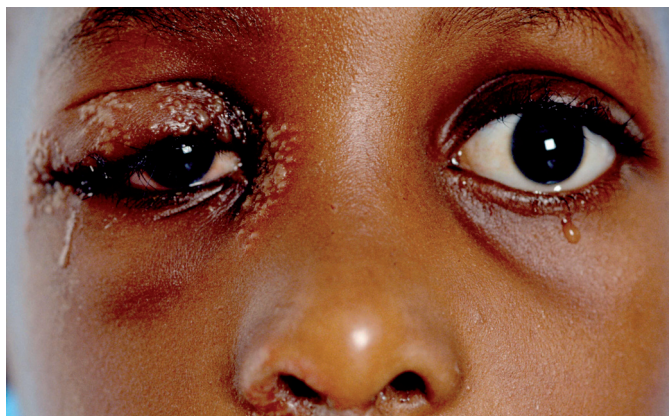

Fig. 2. Herpes simplex blepharoconjunctivitis.

Herpes simplex conjunctivitis type 1 (Fig. 2) occurs in children under 5 years and may be associated with vesicular eyelid eruptions and corneal involvement. **Type 2 herpetic conjunctivitis** is seen in newborns or adults with previous orogenital contact. Treatment is with topical antivirals. Corticosteroids should be avoided as they enhance the severity of coexistent keratitis.

Other causes of self-limiting viral conjunctivitis include rubella, rubeola, varicella zoster, Epstein-Barr and Newcastle disease viruses.

Allergic conjunctivitis

Acute atopic conjunctivitis is an IgE-mediated allergic response precipitated by airborne allergens such as dust, pollen, spores and animal dander. Patients complain of itching, burning, and may have a watery or mucoid discharge, as well as nasal and respiratory symptoms. There is usually a family history of atopy. Treatment involves the use of topical antihistamines, mast cell stabilisers, vasoconstrictors, non-steroidal anti-inflammatories and steroids where necessary. A perennial form of acute atopic disease may occur in conjunction with seasonal changes and is treated on a symptomatic basis.

Giant papillary conjunctivitis occurs in contact lens wearers and may present acutely, in spite of a long history of lens wear. Symptoms consist of ocular irritation, mucoid discharge and foreign body sensation.

Vernal keratoconjunctivitis (Fig. 3) presents similarly to perennial allergic disease, but is seen in children up to 13 years and is increasing in incidence in HIV-positive adults. Symptoms are photophobia, tearing, decreased vision, burning sensation of the eyes and a thick ropy discharge, which is worse in the mornings. Patients often have associated respiratory allergic disease such as rhinitis, asthma and/or eczema. On examination the eyelids are swollen with an injected cobblestone appearance on lid eversion. These are giant papillae, which can cause irritation and mechanical damage to the cornea, resulting in ulceration and scarring. On the corneal limbus, whitish

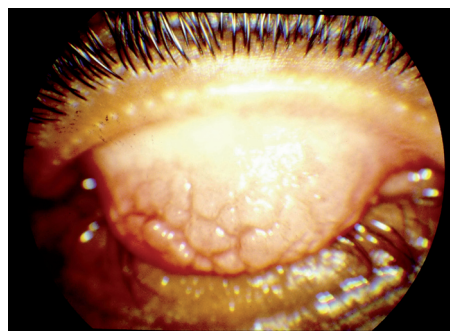


Fig. 3. Vernal keratoconjunctivitis.

inflammatory nodules consisting of hypertrophic lymphoid tissue can be seen. Due to the chronicity and sight-threatening consequences of the corneal aspect of this disease, patients must be assessed by a specialist.

Keratitis

Infectious keratitis or corneal ulceration may be bacterial, viral, fungal or protozoal. Predisposing factors include contact lens wear, corneal injury and ocular surface disease, including any condition disrupting ocular surface defence mechanisms such as dry eye, post-herpetic corneal disease, and corneal exposure. Patients who are immunocompromised are at risk of more aggressive forms of keratitis.

Corneal ulceration caused by the fresh and salt water *Acanthamoeba* species is typically seen in young patients who wear contact lenses and who wash their lenses or lens cases in tap water. It presents as an unbearably painful, injected eye with photophobia and decreased visual acuity.

Fungal keratitis is particularly severe in HIV-positive patients and diabetics. It is sometimes associated with a preceding corneal injury involving vegetable matter contact with the eye and is seen in farm labourers.

Viral keratitis is most commonly caused by HSV-1 in children with associated blepharoconjunctivitis. Herpes zoster ophthalmicus (Fig. 4) is seen increasingly in HIV-positive patients, and keratitis is particularly common if the characteristic dermatomal vesicular rash involves the tip of the nose. Patients may also have conjunctivitis, anterior uveitis, glaucoma, scleritis, optic neuritis and second to eighth cranial nerve palsies.

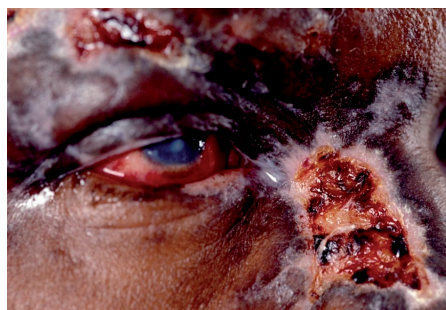

Fig. 4. Herpes zoster ophthalmicus.

General symptoms of all forms of keratitis (Fig. 5) are blurring of vision, pain, especially on blinking, tearing and a discharging eye. Clinical features include eyelid oedema and discharge, conjunctival hyperaemia, greyish-white area of defect or ulceration on the cornea, and a hypopyon (pus in the anterior chamber). The specific features of the corneal ulcer give clues to the aetiology, e.g. viral ulcers appear dendritiform (Fig. 6)

whereas fungal ulcers have poorly defined borders and satellite lesions. Patients require specialist assessment with a slit lamp to detect specific clinical features and for corneal scraping for microscopy and culture, so that antimicrobial treatment may be commenced appropriately. Under no circumstances must steroid eye drops or ointment be offered to the patient prior to referral as this will worsen the clinical outcome.

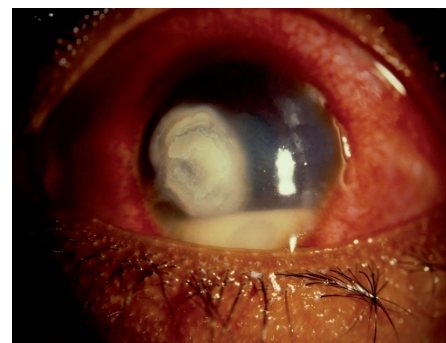


Fig. 5. Corneal hypopyon ulcers.

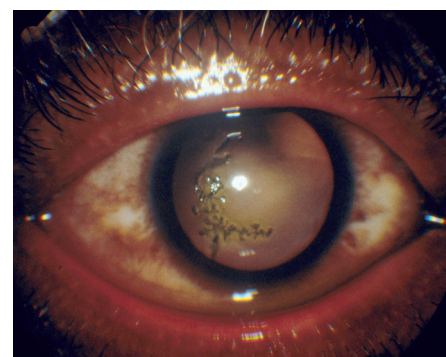


Fig. 6. Viral dendritic corneal ulcer.

Episcleritis and scleritis

Episcleritis typically affects young adults. It is self limiting, often not requiring any medication, but is frequently recurrent. It presents with unilateral mild discomfort, tenderness to the touch and a watery eye with redness over a localised or diffuse area of the sclera. Slit lamp examination is required to differentiate episcleritis from scleritis, which is much less common but may have sight-threatening consequences.

Scleritis is inflammation of the sclera which may be insignificant and self-limiting, or associated with necrosis (Fig. 7) and lead to keratitis, uveitis, glaucoma, cataract, retinal oedema and optic neuropathy. About 45% of patients with scleritis have systemic conditions such as rheumatoid arthritis, connective tissue diseases such as Wegener's disease, systemic lupus erythematosus and polyarteritis nodosa, and other miscellaneous conditions such as herpes zoster. Presentation of scleritis is similar to episcleritis, but patients may have more severe pain and associated visual impairment.

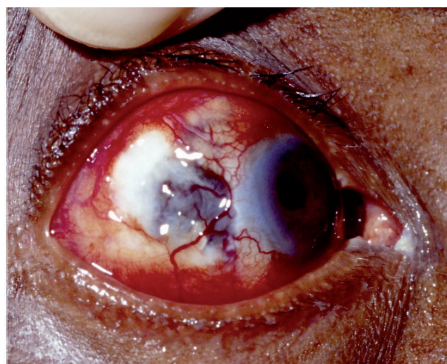


Fig. 7. Necrotising scleritis.

Uveitis

Acute uveitis presents with injection surrounding the cornea and the patient complains of photophobia, pain, tearing and blurring of vision. Slit lamp examination shows the presence of active inflammation in the anterior chamber. Inflammatory nodules may also be seen on the iris. Uveitis may be associated with infections, systemic diseases or it may be idiopathic.

Acute-angle closure glaucoma

This condition occurs due to a sudden rise in intraocular pressure, when the drainage angle of the eye becomes totally occluded by the peripheral iris. It usually occurs in patients who demonstrate an anatomical predisposition to angle closure, and is frequently bilateral. Patients complain of periocular pain and progressively decreasing vision, with associated nausea and vomiting in severe cases. There may be a history of a previous similar attack which resolved. The eye is congested and inflamed, the cornea is hazy and the anterior chamber may appear shallow with a mid-dilated pupil. The eye will feel digitally firm and will be tender. Patients require immediate intraocular pressure lowering agents and further specialist management.

Sudden visual loss

Causes of sudden loss of vision are retinal detachment, central retinal artery occlusion, retinal vein occlusion, anterior ischaemic optic neuropathy, optic neuritis, vitreous haemorrhage and posterior uveitis.

Retinal detachment

Clues as to the presence of a retinal detachment are a history of seeing flashing lights, floating opacities in the eye and the presence of a curtain or shadow of darkness with loss of vision in the eye. Patients may have risk factors such as being myopic, having a family history of retinal detachment or having had a recent contusive injury to the head or eye. Fundal examination reveals a poor red reflex and the appearance of lifted retina (Fig. 8).

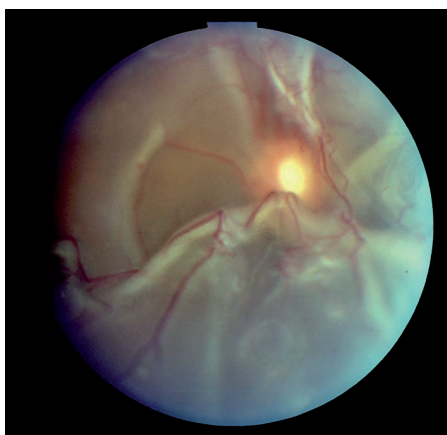


Fig. 8. Retinal detachment.

Central retinal artery occlusion

A patient with a central retinal artery occlusion will complain of sudden total visual loss. On history, certain systemic risk factors such as carotid artery disease, hypercholesterolaemia and giant cell arteritis may be present. On examination, the pupil will be non-reactive to light and the fundus appears pale with a central ‘cherry-red spot’ at the fovea (Fig. 9). Preliminary emergency treatment involves applying firm ocular massage intermittently for at least 15 minutes, in the hope that intraocular pressure will decrease and blood flow will increase, dislodging the emboli causing the occlusion. The patient must then be promptly referred for further management.

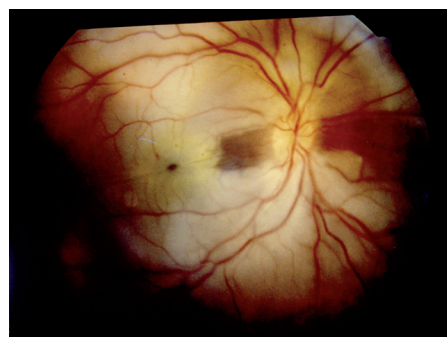


Fig. 9. Central retinal artery occlusion.

Retinal vein occlusion

Patients with a suspected retinal vein occlusion will complain of decreased vision in part of or the whole visual field, which may be accompanied by distortion in vision. Systemic predisposing factors are increasing age (6th to 7th decades), systemic hypertension and blood dyscrasias such as chronic leukaemia, polycythaemia, Waldenstrom’s macroglobulinaemia and sickle cell disease. Ocular risk factors are raised intraocular pressure, hypermetropia, congenital central retinal vein anomaly and periphlebitis as seen in sarcoidosis and Bechet’s disease. The pupil of the affected eye may be sluggish or non-reactive. On fundal examination, the veins look dilated and tortuous and there are flame-shaped and dot and blot haemorrhages with retinal oedema and cottonwool spots in the area of the retina drained by the obstructed vein (Fig. 10).

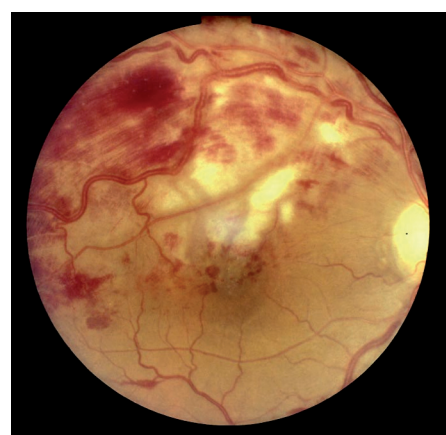


Fig. 10. Retinal vein occlusion.

Anterior ischaemic optic neuropathy

This condition occurs as a result of infarction within the optic nerve. It may be associated with giant cell arteritis and systemic vascular diseases, in which case it occurs typically in the elderly. In patients between 45 and 65 years old who are hypertensive or healthy, anterior ischaemic optic neuropathy can occur as an isolated event. Presenting features are uniocular, sudden and sometimes profound visual loss, with periocular pain, visual obscurations and flashing lights. The involved pupil may be non-reactive to light. There may be a defect of half of the visual field, and colour vision is diminished. The optic nerve appears pale and swollen and may be surrounded by splinter-shaped haemorrhages (Fig. 11).

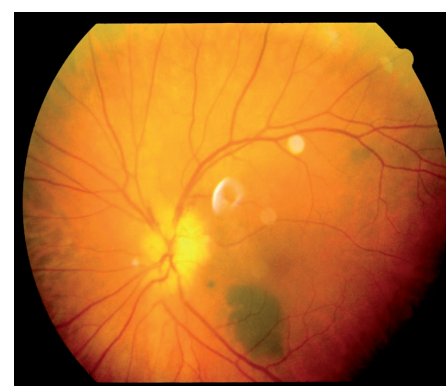

Fig. 11. Anterior ischaemic optic neuropathy.

Optic neuritis

Optic neuritis is a condition where there is inflammation in the optic nerve, and therefore decreased vision. It may be associated with multiple sclerosis or may be related to systemic infection, especially in children, where it follows viral infections such as measles, mumps, chickenpox, whooping cough, glandular fever and immunisation. Patients have monocular visual loss, which frequently is accompanied by periocular discomfort, which is worse on eye movement. Associated globe tenderness and frontal headache can occur. In children both eyes may become involved and other

neurological features such as seizures or ataxia may occur. On ocular examination the pupil is sluggish or non-reactive, and there is diminished colour vision and sensitivity to light in the affected eye. Ophthalmoscopy reveals a swollen optic nerve head or papillitis (Fig. 12).

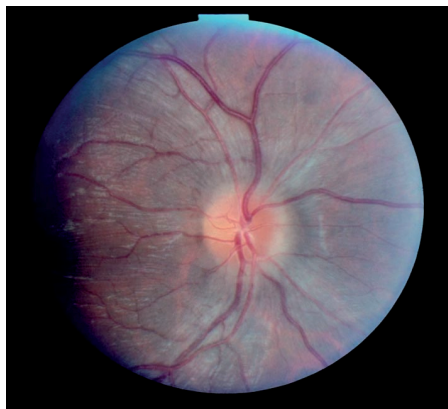

Fig. 12. Optic neuritis.

A vitreous haemorrhage, especially in diabetics, and posterior uveitis, can also cause sudden visual loss and clinically have a poor red reflex on examination.

Acute ocular trauma

Acute ocular trauma consists of mechanical, chemical, thermal and combination eye injuries.

Mechanical eye injuries

These present as non-penetrating or penetrating/perforating eye injuries.

Non-penetrating eye injuries

The commonest non-penetrating injuries seen are a foreign body on the eye and a corneal abrasion. Patients may have felt something enter their eye, may have been grinding, hammering or chiselling, mowing the lawn or may present with an uncomfortable feeling on closing the eye, tearing and redness of the eye.

On examination there may be a visible break in the epithelial surface which can be confirmed by seeing yellow-green staining on installation of fluorescein eye drops. A foreign body may be seen on the corneal surface, in the fornices or on eversion of the upper lid.

Most superficial foreign bodies can be removed; however, some may be deeply embedded in the cornea and these patients will require referral for removal under slit lamp magnification. Topical anaesthetic drops should be instilled and a cotton-tipped applicator is used to manipulate the foreign body off the eye. Further management after removal of corneal foreign bodies and of corneal abrasions entails using an antibiotic

ointment such as chloramphenicol and padding the eye for 24 hours to encourage epithelial healing.

If there is a suspicion that a foreign body may have penetrated the eye, the patient should be promptly referred to an ophthalmologist who will do a dilated funduscopy, X-ray and CT scan to confirm the presence and exact location of the foreign body and plan surgical removal of it.

Welding may result in a condition called 'arc eye', which occurs when a patient is not wearing protective eyewear, causing painful, injected eyes. Treatment is with topical anaesthetic eye drops, double eye padding, oral analgesia and a non-steroidal or weak steroid eye drop depending on the degree of inflammation.

Contusive eye injuries caused by a blow to the eye can result in a wide range of intraocular damage which can only be detected with a slit lamp or with dilated fundus examination. Orbital blowout fractures (Fig. 13) result from a blow to the eye which produces a sudden rise in the intraorbital pressure. This causes the walls of the orbit to fracture, sometimes entrapping extraocular muscles in the process. Patients have periocular ecchymosis and oedema, subcutaneous emphysema, a restrictive strabismus, decreased ocular motility, enophthalmos, anaesthesia of the cheek and complain of double vision. An X-ray examination may show orbital fractures but a CT scan and specialist assessment are required for possible surgical orbital repair.

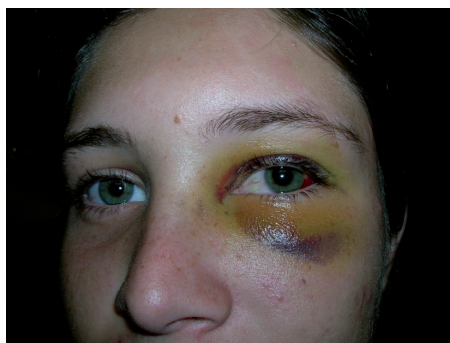

Fig. 13. Orbital blowout fracture.

Any proptosis (Fig. 14) must be referred for an orbital CT scan to exclude the presence of a retrobulbar haematoma after careful documentation of the pupillary response, which indicates the presence of pressure on the optic nerve.

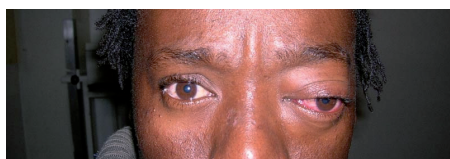

Fig. 14. Traumatic proptosis with retrobulbar haematoma.

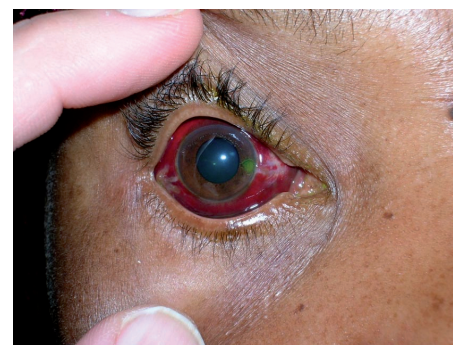

Fig. 15. Subconjunctival haemorrhage with corneal abrasion staining with fluorescein dye.

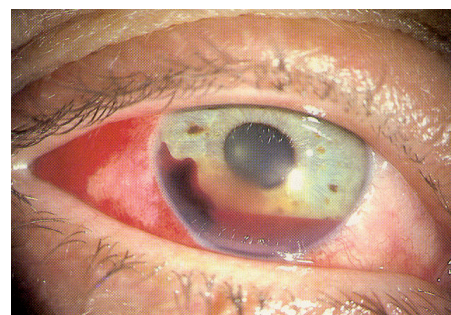

Fig. 16. Hyphaema.

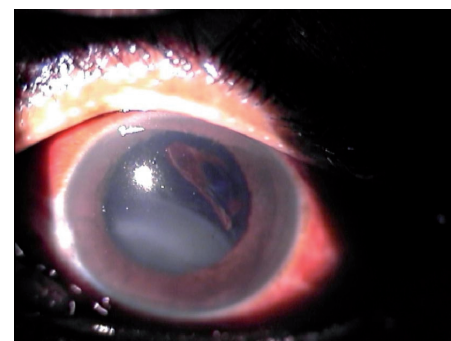


Fig. 17. Contusive eye injury with mid-dilated pupil with blood in the vitreous and lens dislocation.

Globe injuries will all require specialist intervention except subconjunctival haemorrhages (Fig. 15), which are self-limiting and require only reassurance to the patient. A hyphaema (Fig. 16), which is blood in the anterior chamber of the eye, can be recognised as a level of blood or a blood clot obscuring the iris and sometimes the pupil. Any irregularities in the iris, lens (Fig. 17) or on fundus examination or any non-penetrating injury where there is visual affectation must be seen by a specialist.

Penetrating and perforating eye injuries

Minor lid lacerations may be sutured, but those involving the lid margin, tarsal plate or lacrimal drainage system must be referred.

Ocular lacerations are recognised as a break in the cornea (Fig. 18) or scleral continuity (Fig. 19) and may have protruding iris, vitreous or brown uveal tissue visible. There may also be a hyphaema present, shallow anterior chamber of the eye, distortion of the pupil, iris and lens damage.

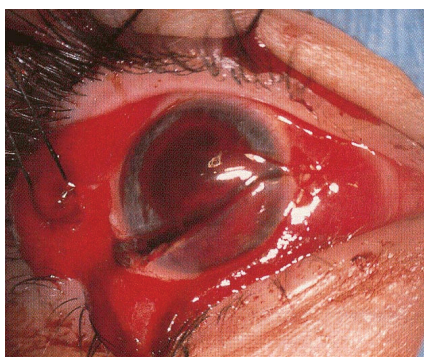


Fig. 18. Corneal laceration.

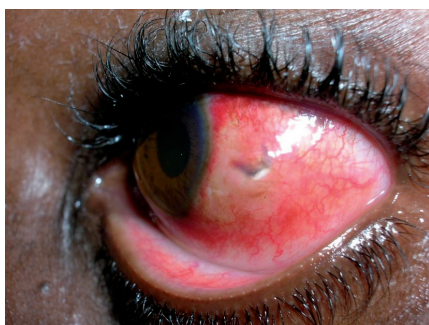


Fig. 19. Scleral laceration with visible uveal tissue.

Stab injuries to the orbit are particularly prone to severe infection of the globe (panophthalmitis) and orbital sepsis which may spread to the brain. Patients should therefore be commenced on systemic antibiotics as prophylaxis.

Gunshot wounds to the orbit cause perforating or through-and-through globe injuries, sometimes damaging the eye to the extent that it becomes disorganised. Surrounding orbital tissue and bones are also severely damaged in the process. Patients' general condition must be primarily attended to, due to the high risk of concurrent intracranial injury.

Being a surgical emergency, penetrating or perforating injuries require prompt referral after the patient has received topical antibiotics, systemic analgesia, tetanus prophylaxis, and eye padding.

Chemical injuries

Chemicals commonly responsible for eye injuries are household detergents, bleaches and disinfectants. Fertilisers, pesticides and industrial chemicals in the occupational sector are potent and can cause severe ocular damage, especially alkaline solutions which tend to penetrate the eye long after contact. It is crucial to establish the chemical responsible and to irrigate the eye with normal saline or sterile water immediately. Topical anaesthetics should be used for eye pain, the eye must be padded and the patient referred.

Thermal injuries

Injuries caused by sparks from a fire, match or boiling water vary, depending on the degree of contact with the eye. Corneal abrasions commonly result and surrounding skin and scalp may also need attention.

Combination injuries

These comprise eye trauma related to fireworks, blasts and motor vehicle accidents, all of which require referral after initial assessment to exclude other injuries to the body and pain control.

Further reading

Kanski JJ. *Clinical Ophthalmology – A Systematic Approach*. Oxford: Butterworth-Heinemann, 2003.

Kuhn F, Pieramici DJ. *Ocular Trauma – Principles and Practice*. New York: Thieme Medical Publishers, 2002.

Kirk RW, Andrew JW, et al. *External Disease and Cornea. Basic and Clinical Science Course*. San Francisco: American Academy of Ophthalmology, 1998.

Visser L. *Common Eye Emergencies and Procedures – Lecture Notes for General Practitioners 2005* (unpublished).

Yanoff M, Duker J. *Ophthalmology*. 2nd ed. St Louis: Mosby, 2003.

In a nutshell

- Common eye emergencies comprise the acute red eye, sudden visual loss and acute ocular trauma.
- The acute red eye can present as conjunctivitis, keratitis, episcleritis, scleritis, uveitis and acute-angle closure glaucoma.
- Sudden visual loss can be due to retinal detachment, central retinal artery occlusion, retinal vein occlusion, anterior ischaemic optic neuropathy, optic neuritis, vitreous haemorrhage and posterior uveitis.
- Acute ocular trauma can be due to mechanical, chemical, thermal or combination injuries.
- Most emergencies will require a general and ocular assessment before referral to a specialist.

single suture

Coffee may delay dementia

Evidence from a sample of adults in the community aged at least 65 shows that caffeine intake seems to reduce cognitive decline in women who do not have dementia, especially in older women, according to Karen Ritchie and colleagues writing in *Neurology*. They studied 4 197 women and 2 820 men from three French cities. No effect on the incidence of dementia was seen, but drinking more than 3 cups of coffee a day may be able to prolong the period of mild cognitive impairment in women before a formal diagnosis of dementia is made.

Ritchie K et al. *Neurology* 2007; 69: 536-545.