

Diabetes and the eye

Diabetes is a common cause of eye problems.

VANESSA THUNSTROM, MB ChB, FCOphth (SA)
Private practitioner, Entabeni Hospital, Durban

Vanessa Thunstrom qualified MB ChB at Stellenbosch University in 1996. She specialised in ophthalmology at the University of KwaZulu-Natal in 2000 - 2003 and was awarded the Justin van Selm medal for part 2 of the FCOphth examination. She worked as a consultant at Inkosi Albert Luthuli Central Hospital (IALCH) and St Aidan's Hospital until the end of 2006. Dr Thunstrom has a special interest in vitreoretinal disorders. She is currently in private practice at Entabeni Hospital and does sessions at IALCH. She also runs a weekly fluorescein angiogram clinic at Entabeni Hospital.

Diabetes causes a wide spectrum of diseases in and around the eye. Diabetic damage is not limited to the lens and retina, but also includes other orbital, ocular and neurological complications. The WHO estimates that there are 150 million people worldwide living with diabetes, and expects this figure to double by 2025. More than 90% of these patients are type 2 diabetics. According to WHO and CDC statistics there are about 7.5 million undiagnosed diabetics in the USA.

Orbit and lids

Mucormyces mucor is an anaerobic fungus which is a commensal organism in immune-competent individuals. In diabetic patients with immunoparesis it can cause an invasive life-threatening infection. It invades endothelial cells and causes necrotising vasculitis. The patient may present with orbital cellulitis. The hallmark of this disease is a black eschar on the eyelids or palate. A high index of suspicion and prompt referral to an ear, nose and throat specialist or an ophthalmologist are required. A biopsy or pus swab will confirm the diagnosis. Treatment is surgical débridement to the border of viable tissue and intravenous amphotericin B. Hyperbaric oxygen may also be beneficial.

Cornea

Neurotrophic keratopathy

Corneal sensation is supplied by the first branch of the trigeminal nerve and may be affected in long-standing diabetics. This predisposes the patient to recurrent corneal erosions and infectious keratitis.

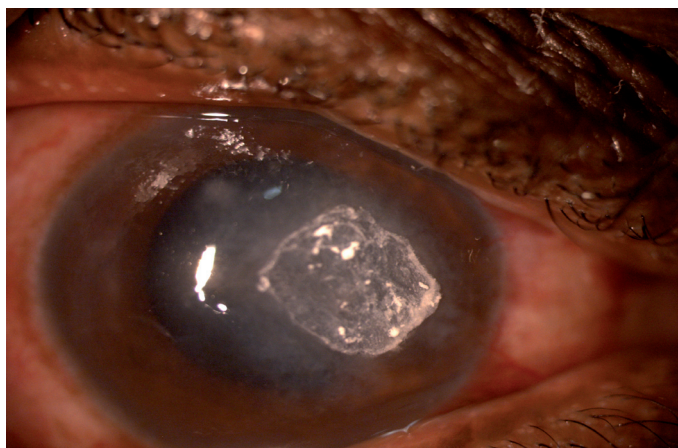


Fig. 1. Fungal keratitis.

The WHO estimates that there are 150 million people worldwide living with diabetes.

Infectious keratitis

This may occur in a neurotrophic cornea. As part of the immunoparesis, or because of microtrauma, diabetics are predisposed to fungal keratitis (Fig. 1), especially with *Candida* spp. The patient presents with a gradual onset of a painful eye, with conjunctival injection and a white, well-circumscribed corneal infiltrate. There may be a pus level in the anterior chamber (hypopyon). The diagnosis is made by an ophthalmologist on corneal scraping and culture of the specimen. Antifungal treatment is with amphotericin B or fluconazole.

Lens

Refractive instability

Fluctuations in blood glucose level may cause swelling of the lens because of osmotic changes. Patients may be aware of intermittent blurring in vision as their refractive status may fluctuate until blood glucose levels are stabilised. This may occur in newly diagnosed diabetics or in those whose blood glucose levels are unstable.

Cataract

Diabetics are prone to pre-senile cataract formation (Fig. 2). Before cataract surgery the retinal status must be evaluated thoroughly, as both diabetic maculopathy and diabetic retinopathy may be worsened by cataract surgery.

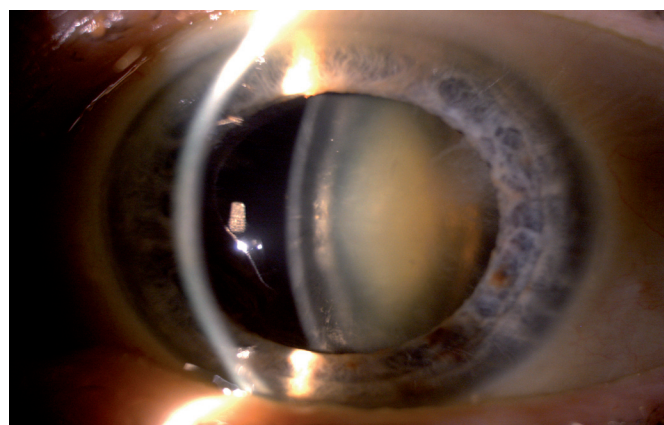


Fig. 2. Cataract.

It is essential that all diabetics are educated about ocular complications of their disease.

Small-incision phacoemulsification is the technique of choice, with careful follow-up of retinopathy status and macular oedema.

Diabetic retinopathy

This is by far the most important form of ocular complication in diabetes. Patients must be well educated at an early stage of their disease, so that the appropriate interventions may be performed timeously. When patients start complaining of visual symptoms, they often already have serious eye complications and visual recovery is not always possible.

Diabetic retinopathy may be present at diagnosis in type 2 diabetics, but nearly all type 1 diabetics have some form of retinopathy by 10 years.¹ Diabetic women who are contemplating pregnancy should be seen before falling pregnant, as pregnancy accelerates diabetic retinopathy, and laser treatment should be commenced timeously.

Pathogenesis

Diabetic retinopathy is categorised into either diabetic maculopathy, or proliferative changes (Fig. 3).

Maculopathy is the most common cause of moderate to severe visual loss, while proliferative diabetic retinopathy (PDR) is the most common cause of severe, irreversible visual loss.

Damage is on a microvascular level, and mirrors damage to kidney, heart and limbs. Loss of pericytes leads to loss of vessel integrity, with the formation of microaneurysms. These are prone to leakage and form the basis of diabetic maculopathy, mostly manifested as intraretinal oedema and hard exudates that appear as hard, yellow glistening bodies. Microvascular occlusion occurs secondary to sorbitol damage and increased erythrocyte adhesion. This leads to retinal ischaemia and production of vascular endothelial growth factor (VEGF). This in turn leads to retinal neovascularisation, vitreous haemorrhage, gliosis and traction retinal detachment. 'Cotton wool' spots are fluffy white areas of the retinal nerve fibre layer that represent micro-infarcts.

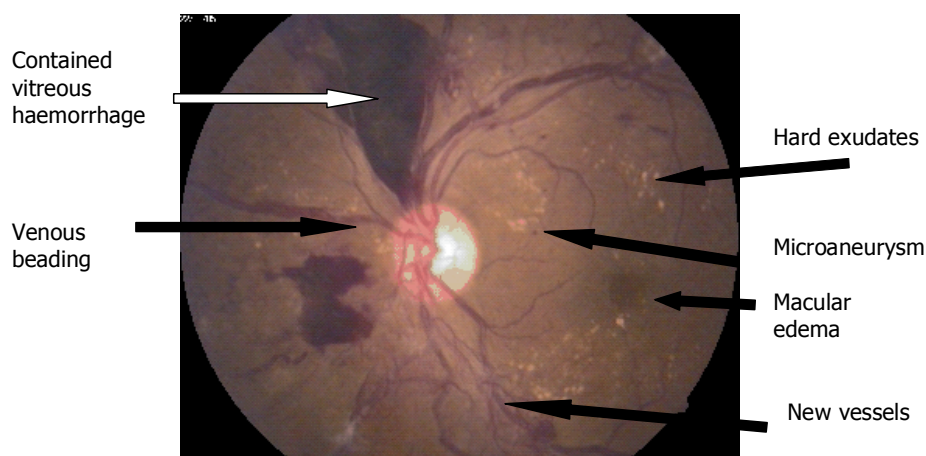


Fig. 3. Spectrum of changes in diabetic retinopathy in a patient with advanced proliferative changes and macular oedema.

Screening

It is essential that all diabetics are educated about ocular complications of their disease. Screening before onset of symptoms is the only way to manage problems at the appropriate stage. All type 2 diabetics should be screened at diagnosis and yearly thereafter. This is due to possible delayed diagnosis of the onset of diabetes. Patients may even present with vitreous haemorrhage and not be aware that they are diabetic. Type 1 diabetics should be screened 10 years after diagnosis and yearly thereafter.

With the use of non-mydratic fundus cameras fundal pictures can be gathered from a large diabetic population and can then be screened by a skilled individual. Those with diabetic retinopathy and those ungradable because of media opacity should be referred to an ophthalmologist. The Early Treatment Diabetic Retinopathy Study showed that early laser treatment decreased the risk of visual loss by 90%.²

The aim of laser treatment in proliferative diabetic retinopathy is to induce regression of retinal neovascularisation, and may be performed over a number of sessions.

Maculopathy may be of the exudative or ischaemic type. Ischaemic maculopathy is diagnosed on fluorescein angiogram (Fig. 4), where there is loss of retinal capillaries supplying the fovea. The degree of visual loss correlates with that of vascular fall-out seen on angiography, and is irreversible.

Exudative maculopathy is diagnosed by the loss of normal macular light reflex and presence of haemorrhages and exudates around the macula.

The use of argon laser for maculopathy is aimed at stabilising vision, which may improve in 20 - 30% of patients. Laser treatment is applied in a C-shaped grid around the fovea, or else focal burns are applied to leaking microaneurysms. A fluorescein angiogram may be useful in identifying leaking aneurysms, in order that the aneurysms may be treated with laser.

Optical coherence tomography

Optical coherence tomography (OCT) is a new imaging technique using near infrared frequency light to obtain an almost live histological picture of the retina. It can also quantify retinal thickness exactly.

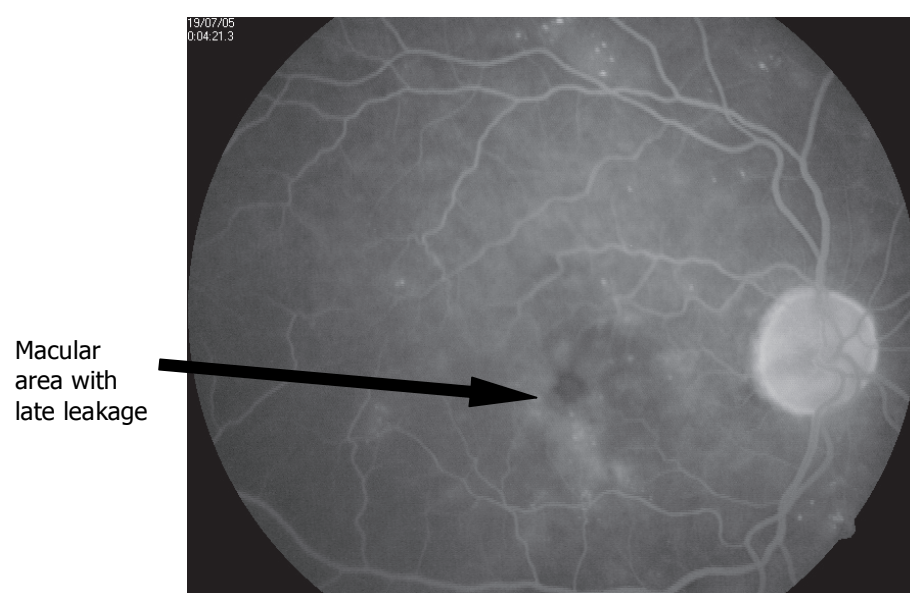


Fig. 4. Fluorescein angiogram showing late-phase macular oedema.

Diabetes

This is very useful in following up cases of diabetic macular oedema (DME) to assess whether or not retinal thickness has responded to laser treatment.

Another essential cornerstone in the prevention of visual loss and systemic end-organ damage is good, long-term control of glycaemia, and of blood pressure and cholesterol levels.

New medical treatments

Triamcinolone acetonide

This is a long-acting steroid preparation which is delivered to the posterior segment of the eye by intravitreal injection. The main indication is DME non-responsive to conventional argon laser treatment. It has been shown to decrease macular thickness for about 3 months.³ It may be more efficacious if given early during the course of the oedema, before the onset of chronic ultrastructural changes.

Bevacizumab

Bevacizumab is an antibody fragment to VEGF and has potent antiproliferative and antipermeability activity. It was developed for use in patients with metastatic colorectal cancer. Its greatest ocular use to date has been for exudative age-related macular degeneration. Its application in diabetes is mainly related to DME, where its antipermeability effects are used to reduce macular thickness. Even though it is effective for only a short time, it shows much promise.

The future ...

Widespread screening programmes need to be instituted where non-mydratic pictures are taken and screened by a suitably qualified person. The future will probably centre around medical treatment, with less need for laser treatment, with anti-VEGF agents currently showing the most promise.

Surgical treatments

Vitreous haemorrhage

Unfortunately, there are still many patients with PDR who either have very aggressive

disease or who present late and develop complications requiring vitrectomy. Vitreous haemorrhage presents in varying degrees of severity – up to the most severe where the fundus is not visible. These patients complain of sudden, but painless, severe loss of vision. They must be referred immediately to exclude retinal detachment (RD). A short period of observation may be warranted, whereafter pars plana vitrectomy may be performed, the blood is cleared and laser treatment applied from inside the eye.

Tractional retinal detachment

Tractional RD occurs when retinal neovascularisation, with its associated fibrous proliferation and vitreous haemorrhage, organises into a gliotic membrane overlying the retina and undergoes contraction. This membrane then elevates the retina at various points. Surgery is indicated if the traction is very high, if the macula is detached or if the traction on the macula is direct. The aim of surgery then is to clear the vitreous gel, resect the gliotic membrane, and apply endolaser as required.

Other retinal abnormalities

Branch retinal vein occlusion (BRVO)/central retinal vein occlusion (CRVO)

As diabetics usually have elevated blood pressure, high erythrocyte adhesion and high cholesterol levels, they are more prone to BRVO or CRVO. Patients typically present with sudden onset of blurred vision, which may be severe. The fundus shows dilated tortuous veins, with scattered flame-shaped retinal haemorrhages. Ophthalmic assessment is required for diagnosis. Fundus fluorescein angiography may be indicated to assess the degree of retinal ischaemia. Patients may require laser therapy, to treat neovascularisation or macular oedema.

Cranial nerve palsies

As mentioned above diabetics tend to have a host of problems, including raised cholesterol levels and hypertension. As such they may be prone to vasculopathic complications. A micro-infarct of one of the cranial nerves supplying the extraocular muscles (3rd, 4th or 6th) may cause double

vision. A full neurological examination is required, including an examination of all the cranial nerves. Once it has been confirmed that there is only a mononeuropathy present, a period of observation is warranted. Full recovery usually occurs after 3 - 6 months. During this time, one of the eyes can be covered with a patch to prevent troublesome diplopia. If at any time there is progression of the palsy, or if the patient does not fully recover, it is warranted for the patient to undergo neuro-imaging to exclude any other intracranial process.

References

1. Yanoff M, Duker JS. *Ophthalmology*. 2nd ed. St Louis: Mosby, 2004: 877.
2. ETDRS Research Group: Focal photocoagulation treatment of diabetic macular edema; ETDRS report 19: *Arch Ophthalmol* 1995; 113: 1144-155.
3. Patelli G, Fasolino P, Radice S, Russo G, Zumdo FM, di Tizio FM. *Retina* 2005; 25: 828-841.

In a nutshell

- Diabetes can cause severe, irreversible visual loss.
- The incidence of diabetes is on the rise.
- Early education and screening are mandatory to prevent visual loss.
- Good metabolic control is vital to prevent end-organ damage.
- Type 2 diabetics may have retinopathy at the time of diagnosis of their diabetes.
- Older diabetics are vasculopaths and prone to micro-infarcts.
- Decreased humoral immunity makes diabetics prone to severe corneal and orbital infections.
- Diabetic patients wishing to fall pregnant should have their eyes evaluated before pregnancy.
- Visual loss may be prevented by early laser treatment.