

Office skills for the general practitioner*

A GP needs only a few basic tools to conduct an adequate ophthalmic examination and appropriately refer cases.

M F ADAMJEE, MB BCh, DA, DCH, FCOphth (SA)

Department of Ophthalmology, Nelson R Mandela School of Medicine, University of KwaZulu-Natal, Durban

Farouk Adamjee qualified in 2003 as an ophthalmologist at the Nelson R Mandela School of Medicine, University of KwaZulu-Natal. He worked as a consultant at St Aidan's Hospital in Durban until February 2007. He has a special interest in vitreoretinal disorders. He is currently employed as a consultant in the Department of Ophthalmology, University of the Free State, Bloemfontein.

Eye disorders are relatively common. In most cases, the patient would present to a general practitioner for the initial eye assessment. A thorough ophthalmologic evaluation is therefore vital in order to uncover common abnormalities of the visual system and related structures, as well as less common but extremely serious ones, such as ocular tumours. Often, an adequate evaluation can also uncover evidence of many forms of systemic disease with ophthalmic manifestations.¹ A comprehensive medical eye evaluation includes history, examination, diagnosis, and initiation of management. The tools that are essential for an adequate eye examination are listed below and pictured in Figs 1 - 3.²

SIX ESSENTIAL GP TOOLS FOR EYE EXAMINATION

- Snellen or E chart appropriately illuminated
- Pinhole device
- Penlight
- Fluorescein stain
- Topical anaesthetic agent
- Ophthalmoscope (with reliable batteries)

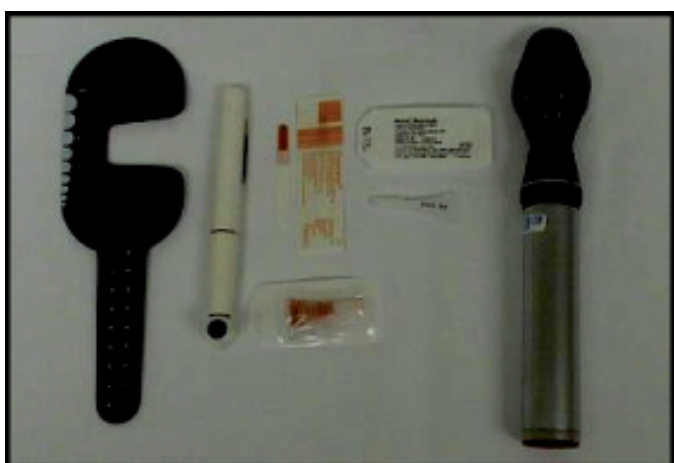

Fig. 1. Essential GP tools for eye examination.

Visual acuity

The first part of the eye examination is an assessment of visual acuity. This can be done with either a standard Snellen chart or a 'Tumbling (illiterate) E' chart. With the patient standing a distance of six metres away, each eye is tested independently. First, the vision is tested without the prescription glasses or contact lenses and

thereafter with them.³ The numbers at the end of the line provide an indication of the patient's acuity compared to that of normal subjects. Finally, a pinhole testing device can be used to determine whether a problem with acuity is the result of refractive error (and thus correctable with glasses) or due to another aetiology.

In clinical practice, the patient is instructed to view the Snellen chart through a single pinhole. Theoretically, each pinhole allows a narrow beam of light to pass through, thus forming a clear retinal image irrespective of the refractive state of the eye.⁴ If the deficit corrects with the pinhole in place, the decreased acuity is due to a refractive problem.

If the patient is unable to read any of the lines, a gross estimate of what they are capable of seeing should be determined (e.g. the ability to count the number of fingers placed in front of them, detect motion or perceive light).

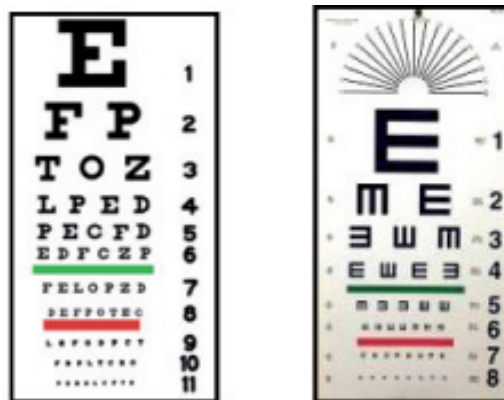


Fig. 2. Snellen and E charts.



Fig. 3. Pinhole.

*This article has been reprinted with permission from SA Fam Pract 2006; 48(7): 20-26.