

The ageing eye

Most people's eyes change as they age.

RIZWANA CASSIM AMOD, MB ChB, BMedSc (Hons) Pharmacology, MMedOphth, FCOphth (SA), BBus & Admin (Hons)

Senior Specialist and Head of Retinal Surgery Unit, Tygerberg Academic Hospital and Faculty of Health Sciences, Stellenbosch University

Rizwana Amod is a retinal specialist, practising full-time at Tygerberg Hospital. Her main interests in ophthalmology are retinal trauma surgery, surgery for diabetic retinopathy, age-related macular degeneration (AMD) and infectious disease of the eye. Her long-term vision for ophthalmology is to help eradicate serious diabetic retinopathy.

As people age, most will inevitably encounter some changes in their vision that may be attributed solely to the ageing process. These processes are distinct from age-related eye diseases, although the visual changes they produce may be similar. One of the truest signs of ageing is the gradual loss of accommodation and the onset of presbyopia.

With an increasing elderly population, age-related eye diseases are becoming the leading causes of vision impairment in the developed world. Many elderly patients are afflicted by more than one ageing eye condition, and these have a tremendous impact on their mental and social health and overall quality of life. Enormous strides are being made in understanding and preventing eye diseases. This article will focus on both the normal ageing processes of the eye and the common eye diseases that afflict the ageing patient.

Normal ageing of the eye

The natural quality of vision gradually declines with the anatomical and physiological processes that occur with ageing of the human eye and visual system. These changes include presbyopia, changes in the eyelids and tearfilm, and changes in the various intraocular structures contributing to the integrity of the visual system.

Presbyopia

Presbyopia refers to the reduced ability to focus at close range as a result of loss of accommodation. It is the most common ocular affliction in the world and is due to the decreased elasticity of the crystalline lens and reduced ciliary body tone that occurs with ageing. The extent to which the lens power can be increased with accommodation slowly declines over the years and the innate ability to focus on objects located at varying distances becomes increasingly difficult.

The average adolescent can comfortably accommodate up to 14D, and by age 45 this drops to about 4D and is completely gone by the age of 50 - 55.¹ The rate of decline of accommodative amplitude occurs with very little inter-individual variability and is considered to be one of the most reliable biomarkers of human age known.²

Presbyopia usually manifests after 40 - 45 years of age. Patients usually complain of increasing difficulty with near visual tasks such as reading fine print and find that small objects need to be held further from the eye in order to be seen clearly.

Treatment of presbyopia

In the early stages of presbyopia simply extending the arms and improving the lighting is adequate for reading. Later, help in the form of reading glasses (plus lenses) becomes necessary. If distance corrective lenses are worn then the presbyopic correction may be incorporated as bifocal or multifocal spectacle lenses. If corrected

with contact lenses the options include monovision, where one eye is corrected for distance vision and the other for near vision or bifocal contact lenses. Refractive surgery for presbyopia has not yet been perfected.

Eyelids

Ageing causes laxity of the eyelids due to involuntional changes of the skin, orbicularis and levator muscles, tarsus and the canthal tendons. These changes contribute to the aetiology of several eyelid disorders such as lower lid inversion (entropion), lower lid eversion (ectropion) and aponeurotic ptosis of the upper lid. These conditions usually necessitate surgical correction.

Lens

As the human eye ages, the lens continues to grow and becomes thicker due to the increasing deposition of outer cortical lens fibres. This is accompanied by a gradual yellowing of the lens and a change in the refractive index – even before the development of cataract. As a result, the sensitivity of the eye to shorter blue wavelengths of light and the ability to discriminate blues and blue-greens becomes reduced.²

Cornea

The clarity of the cornea is maintained throughout life by the corneal endothelial cells. With ageing, the density of the endothelial cells decreases and their morphology changes, rendering the aged cornea more vulnerable to the stress of injury or intraocular surgery.

Ageing and degeneration of the peripheral cornea is more benign and commonly manifests as the prominent white ring of arcus senilis.

Aberrations of the corneal surface also increase with age, resulting in refractive error, glare and reduced contrast. Referral to an optometrist for refraction is often beneficial. Dry eye also manifests frequently due to diminished aqueous tear production and this is treated with tear supplements.

Vitreous

Progressive liquefaction of the vitreous gel occurs, manifesting as the occasional floater. These are benign and tend to be more of an annoyance than a visual impairment. However, the age-related separation of the vitreous gel from the retina, i.e. posterior vitreous detachment (PVD), may also manifest with floaters and may be complicated by retinal tears and retinal detachment. Hence any new-onset floaters and visual disturbances (flashes) mandate referral to an ophthalmologist for a dilated fundal examination and careful scrutiny of the peripheral retina.

Retina

Ageing causes a general decline in retinal function (colour and contrast) due to the gradual loss of neuronal elements and an accumulation of waste material under the retina, called lipofuscin. Regeneration of rhodopsin in photoreceptors slows down and there is reduced retinal illuminance due to the gradual reduction in pupil size (senile miosis), giving rise to night vision problems. Therefore a 60-year-old receives about one-third of the light a 20-year-old receives – similar to wearing medium-density sunglasses in bright light.³

Age-related eye disease

Good visual acuity depends on the integrity of the various structures in the eye and visual pathways. Therefore it is natural to expect that maintenance of good visual acuity into old age is an exception rather than the rule. As the average life expectancy in developed countries is climbing, age-related eye diseases are becoming increasingly common, creating an enormous economic burden. These include cataract, glaucoma, age-related macular degeneration and the retinal complications of vascular diseases.

Age-related cataract

Cataract refers to opacity of the crystalline lens of the eye and is the leading cause of treatable visual impairment affecting approximately 16 million people worldwide. Risk factors for developing cataract include increasing age, genetics, diabetes, ultraviolet exposure, nutrition, steroid use, smoking and trauma.⁴

Symptoms

- Cataract typically produces gradual loss of vision in the affected eye.
- Scattering of light by the cataract may cause monocular diplopia.
- Subcapsular cataracts may cause troublesome glare, especially when driving.

Signs

- Loss of the red reflex or the presence of opacities in the red reflex.

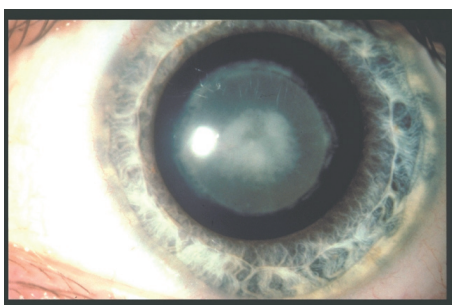


Fig. 1. Senile cataract.

- An untreated mature white cataract is easily visible through the pupil.

Morphological types of age-related cataract (Fig. 1)

- Nuclear sclerosis – progressive yellowing of the centre of the lens.
- Cortical cataracts – peripheral spokes and radial water clefts.
- Posterior subcapsular cataract – opacity just beneath the posterior lens capsule.

Treatment

As yet no effective method exists to prevent or halt the development of cataract. Studies to evaluate the role of nutritional supplements (carotenoids) or antioxidants (vitamins C and E) to delay cataract have been inconclusive.² In the early stage the induced refractive change from the cataract can often be corrected with spectacles and may delay the need for surgery.

Surgery

Surgery is indicated when:

- visual improvement is likely or
- the cataract is a risk to the eye, e.g. precluding a view of the retina in retinal disease or the cataract is inducing inflammation or angle closure glaucoma.

Tremendous advances have been made in cataract surgery in the last decade. Surgery is performed under topical anaesthesia via a small (< 3 mm) self-sealing corneal incision. High-frequency ultrasound (phaco-emulsification) is used to remove the cataract and a foldable intraocular lens (IOL) is then positioned within the capsular bag. Usually monofocal IOLs selected for optimal distance vision are implanted and reading glasses are used for near vision. The newer multifocal and accommodating IOLs allow for unaided near and distance vision.

Visual rehabilitation after cataract surgery is rapid and in the absence of co-morbid ocular disease, 92% of patients achieve a vision of 6/12 or better.⁵ Complications of cataract surgery are infrequent, with a 0.01% risk of blindness from infection. Late secondary deterioration of vision may result from new retinal pathology or opacification of the posterior lens capsule. The opaque posterior capsule is easily excised using a photo-disruptive Nd:YAG laser and the visual axis is cleared.

Glaucoma

Glaucoma describes a group of conditions characterised by progressive optic nerve damage with elevated intraocular pressure (IOP) being the major risk factor (see the article on glaucoma, p. 464 of this issue).

Age-related macular degeneration

Age-related macular degeneration (AMD) is defined as central vision loss attributable to degenerative atrophic and/or neovascular changes in the macula. The macula is the highly specialised central area of the retina used for fine visual acuity and colour vision.⁶ Damage to this makes reading, writing and driving very difficult.

AMD is the leading cause of irreversible visual impairment in the elderly worldwide, affecting an estimated 14 million people.⁶ The disease tends to be bilateral although one eye may be affected long before the other. The risk to the second eye is around 50% within 5 years.

The exact aetiology of AMD is not known but advancing age is a major risk factor. A number of studies have linked smoking to the development of AMD. Other associated risk factors include ultraviolet exposure, nutritional factors and genetic susceptibility. Compelling evidence is emerging that the innate immune system and the complement factor H gene play a vital role in the pathobiology of AMD.⁶

Clinical features

Early AMD is characterised by the presence of yellow deposits (drusen) and pigmentary abnormalities in the macula. It is usually asymptomatic or causes mild visual impairment. It denotes the risk of progression to late AMD (Fig. 2).

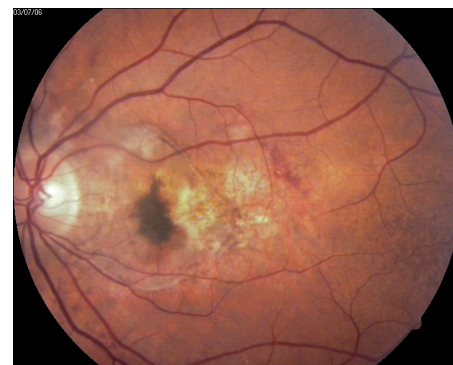


Fig. 2. Age-related macular degeneration.

Late AMD is divided into two types, i.e. wet (neovascular) and dry (non-neovascular) based on the clinical appearance of the macula.

- **Dry AMD** is most common and accounts for 85% of all cases of late AMD. It develops slowly and causes gradual loss of central vision. It is characterised by geographic atrophy of the retinal pigment epithelium (RPE). There is no treatment for dry AMD and patients usually require vitamins and low-vision aids.
- **Wet AMD** is less common and accounts for 10 - 15% of all cases of late AMD. The onset is fairly rapid with an acute drop in central vision and distortion (metamorphopsia).

The ageing eye

Wet AMD is characterised by the development of new vessels beneath the retina (choroidal neovascular membranes (CNV)), serous elevation (detachment) of the neurosensory retina and/or pigment epithelium and macular haemorrhages. End-stage disease demonstrates macular scarring.

Neurospecial investigations

- **Fluorescein angiography** confirms and localises the presence of CNV. Two major forms of CNV membranes may be defined, i.e. classic (well-defined) and occult (poorly defined).
- **Optical coherence tomography (OCT)** involves non-invasive retinal imaging technology depicting the layers of the retina and the underlying RPE. It is used as an adjunct to fluorescein angiography to diagnose, monitor and guide treatment.

Management of AMD

There is neither a cure nor a means to prevent AMD. Early detection is crucial as all interventions are largely palliative and directed purely at minimising the vision loss associated with neovascular (wet) AMD.

An Amsler grid may be given to patients for early detection of any change in their central vision. This test is performed monocularly, wearing their near correction. The grid is held at 33 cm and any distortion is noted (Fig. 3). Any new distortion or field loss requires urgent specialist referral.

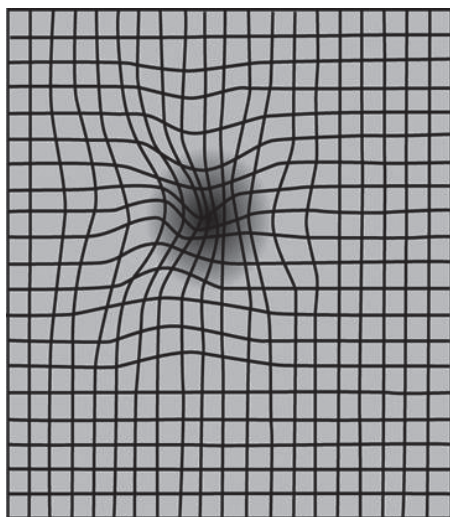


Fig. 3. The Amsler grid with distortion.

High-dose antioxidants and zinc have been postulated to prevent AMD and their role was explored in a large multicentre study (AREDS). The outcomes suggest that high-dose supplements (Table I) can help to delay the progression of AMD in patients with either CNV in one eye, geographic atrophy or bilateral drusen, and long-term use is recommended in these patients. The benefit

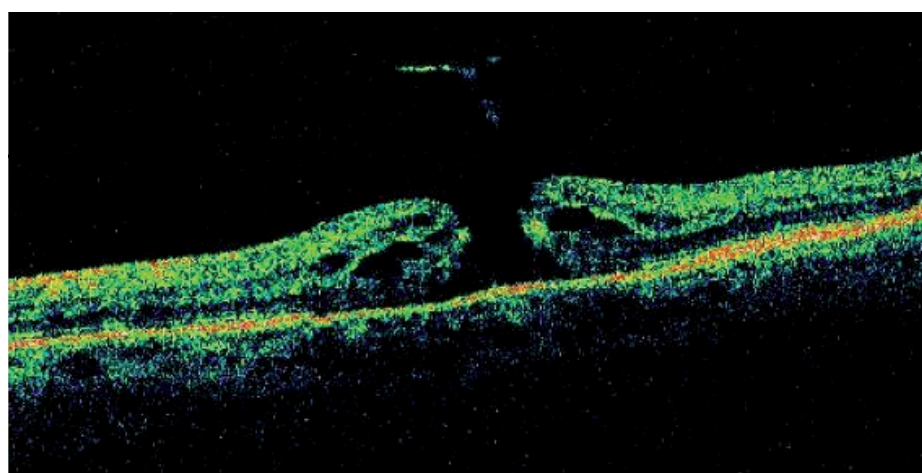


Fig. 4. Optical coherence tomography demonstrating a macular hole.

of this formulation in patients with bilateral early AMD is less certain.

Beta carotene is thought to confer a higher risk of lung cancer to smokers and is contraindicated. Cessation of smoking is also strongly advised.

Current and upcoming therapies for AMD are outlined in Table I. The optimal timing and specific combination of therapy are not yet known. Factors influencing the choice of regimen include the angiographic lesion type, the lesion composition and location and the patient affordability.

Macular hole (Fig. 4)

Senile macular holes occur spontaneously in the macula of elderly patients and result in loss of central vision (scotoma). They are believed to be caused by focal shrinkage of the vitreous and traction in the foveal area. They usually affect one eye although there is a 10% chance that the other eye will eventually be affected. Formation of the hole tends to occur in stages and may arrest at any stage. A stage 4 macular hole refers to a full-thickness hole in the presence of a PVD.

Vascular disease and the ageing eye

Age-related systemic vascular diseases are important risk factors for the development of ischaemic retinal diseases and the associated complications. Common presenting diseases include diabetes, hypertension, carotid artery disease, hyperlipidaemia, systemic vasculitis and hypercoagulability states. Management of the ocular disease is directed towards the underlying cause and possible concurrent antiplatelet therapy to reduce systemic cardiovascular risk.⁷

Diabetes

Manifests as diabetic retinopathy and/or maculopathy (see article on diabetes and the eye, p. 476 of this issue).

Retinal vein occlusion (branch (BRVO) or central (CRVO))

Retinal vein occlusions are the most common retinal vascular disease after diabetic retinopathy (Fig. 5). These patients present with acute vision loss or floaters. Typical ophthalmoscopic features include dilated and tortuous veins, intraretinal haemorrhages, cotton-wool spots, lipid exudates and retinal oedema. In CRVO these changes are widespread and in BRVO they are localised to the quadrant.

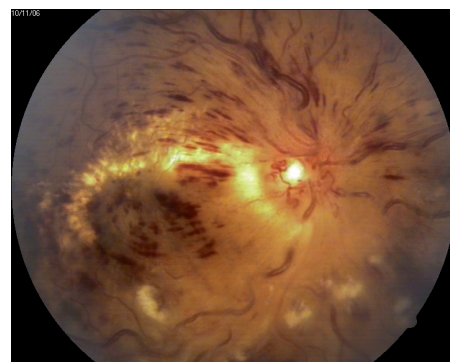


Fig. 5. Central retinal vein occlusion.

Management

Treatment is directed at:

- diagnosis and management of the underlying cause and
- prevention and management of complications, i.e. macular oedema and neovascularisation; complications depend on the extent of ischaemia and whether a collateral circulation is established.

In CRVO, severe ischaemia usually results in neovascularisation of the iris (NVI), often complicated by neovascular glaucoma – a serious and blinding disease. In BRVO neovascularisation of the optic disc (NVD) and elsewhere in the retina (NVE) occurs and may result in vitreous haemorrhage. Treatment of neovascularisation is with retinal laser photocoagulation to prevent further complications. Laser treatment of macular oedema is only indicated in selected cases of BRVO. However, ongoing

Table I. Current treatment options for wet AMD

Treatment options	Indications	Outcomes
Vitamin therapy (AREDS formulation) 500 mg vitamin C, 400 IU vitamin E, 15 mg beta-carotene and 80 mg zinc Copper 2 mg	<ul style="list-style-type: none"> Severe AMD in fellow eye (foveal atrophy, CNV) Moderate AMD (large drusen; extrafoveal atrophy) 	Risk of developing advanced AMD in the fellow eye at 5 years reduced by 20 - 25% NB! Beta carotene contraindicated in smokers
Argon laser (thermal laser)	<ul style="list-style-type: none"> Extrafoveal CNV Limited role in juxtafoveal membranes 	Reduced risk of severe visual loss Risk of recurrence 50%
Photodynamic therapy (PDT) IV Visudyne over 10 mins Non-thermal diode laser (689 nm) for 83 secs	Subfoveal and juxtafoveal CNV: <ul style="list-style-type: none"> all small membranes predominantly classic 100% occult lesions 	Stabilises lesion: <ul style="list-style-type: none"> limits size of scotoma limits more vision loss Re-treatment required at 3-monthly intervals
VEGF inhibitors PegaptinibNa (Macugen) Bavacizumab (Avastin) Ranizibumab (Lucentis) Serial injections in eye 4 - 6- weekly indefinitely	Any lesion type or location	<ul style="list-style-type: none"> Stabilises vision May improve vision Frequent injections – small risk (< 1%) of cataract, infection, retinal detachment
Macular translocation Retina repositioned surgically so macula lies on healthy RPE/choroid	Subfoveal CNV – preferably no previous laser	<ul style="list-style-type: none"> Successful cases have visual improvement Complication rate high Risk of total visual loss

Table II. Indications for urgent referral

Vision <ul style="list-style-type: none"> Acute vision loss not correctable with pinhole Acute-onset visual phenomena – floaters, flashes New-onset visual field defect Central scotoma, metamorphopsia or diplopia
Anterior segment <ul style="list-style-type: none"> Presence of RAPD Dull cornea or positive staining with fluorescein Hard eye, shallow anterior chamber Neovascularisation of iris
Posterior segment <ul style="list-style-type: none"> Total loss of red reflex Disc swelling, pallor New haemorrhages – retinal or vitreous Neovascularisation of retina or disc

novel treatment options are being proposed, including intravitreal injections of vascular endothelial growth factor (VEGF) inhibitors or triamcinolone and decompression surgery.

Anterior ischaemic optic neuroathy (AION) – arteritic and non-arteritic

AION is an infarction of the optic nerve head caused by occlusion of the short posterior ciliary arteries. It is characterised by profound unilateral visual loss, optic disc swelling, relative afferent pupil defect and altitudinal visual field loss.

- Non-arteritic (NAION) may occur in isolation or in association with systemic vascular disease. The risk to the other eye is 5% per year. The management is to treat the vascular risk factors and initiate antiplatelet agents such as aspirin.
- Arteritic AION is due to giant cell arteritis (temporal arteritis/giant-cell arteritis (GCA)) and typically affects patients over the age of 70. The common presenting features include temporal headache with scalp tenderness, jaw claudication manifesting as pain on chewing, polymyalgia rheumatica and fever, weight loss and malaise.

Management

Vision loss from GCA is an ophthalmological emergency as the risk of blindness in the fellow eye is almost 40% within 10 days if left untreated.⁷ The diagnosis of GCA is made on clinical grounds and verified with an elevated erythrocyte sedimentation rate (ESR) (> 60 mm/hr) and /or C-reactive protein.

Treatment with high-dose steroids is usually instituted on clinical grounds while awaiting biopsy of the superficial temporal artery to confirm the diagnosis.

Role of the GP in age-related eye disease

Many elderly patients do not actively seek medical attention and accept that poor vision is an inevitable consequence of ageing. General practitioners therefore have an important role to play in screening for, appropriately referring and co-managing visual impairment in older patients. These responsibilities include:

- To assess the severity and urgency of visual symptoms and refer appropriately (Table II).
- To become thoroughly familiar with the examination of the ageing eye and the clinical morphology of common diseases (Table III). Regular dilated fundal

Table III. Examining the ageing eye – specific features

Visual acuity tests

- Snellen visual acuity with pinhole vision
- Near vision assessment, colour vision

Eyelids

- Entropion or ectropion, horizontal lid laxity
- Elevated lid crease and ptosis

Pupils

- Relative afferent pupil defect

Anterior segment

- Arcus senilis, dry eye, corneal opacities
- Assessment of IOP (digital/tonometry)

Red reflex

- Opacities, loss of red reflex

Optic nerve

- Cupping, disc haemorrhages, nerve fibre layer
- Disc swelling, pallor, vasculature

Retinal vasculature

- Tortuosity, venous beading, new vessels

Retinal pathology

- Haemorrhages, hard exudates, cotton wool spots, macular oedema, degeneration, retinal detachment

Visual fields

- Distortion on Amsler grid
- Altitudinal defect, central scotoma

examination in high-risk patients evaluating the retina, macula and optic disc.

- Important role in continued prescription of long-term eye drops and monitoring for systemic side-effects which may not be evident to the ophthalmologist.
- Patients with high-risk factors, e.g. family history of primary open-angle glaucoma (POAG), should be informed of their risk and referred to an ophthalmologist for screening.
- Control of systemic risk factors (hypertension and diabetes) prior to

elective surgery to avoid complications and cancellation of surgery.

- General medical evaluation, screening and co-management of patients with eye manifestations of systemic diseases.
- Supportive management for visually impaired patients in their occupation and daily activities and facilitating the best use of their remaining vision.
- Ongoing advice and encouragement to maintain ocular health, stop smoking and avoiding co-morbidities like falls, hip fractures, accidents and depression.

Conclusion

As the average life expectancy increases worldwide, age-related eye diseases are becoming increasingly important and account for significant morbidity. Age is an important predictor of visual impairment and active screening for visual loss in the elderly should become part of the routine examination. Prompt referral to the ophthalmologist for the treatment of visual disorders may considerably reduce morbidity from eye disease.

References

1. Kaufman PL. *Accommodation and Presbyopia in Adlers Physiology of the Eye*. Missouri: Mosby, 1999: 9.
2. Meyer CH, Sekundo W. Nutritional supplementation to prevent cataract formation. *Dev Ophthalmol* 2005; 38: 103-119.
3. Hammond CJ, Sneider H, Spector TD, Gilbert CE. Factors affecting pupil size after dilation: The twin eye study. *Br J Ophthalmol* 2000; 84: 1173-1176.
4. West SK, Valmadrid CT. Epidemiology of risk factors for age-related cataract. *Surv Ophthalmol* 1995; 39(4): 323-334.
5. Desai P, Minassian DC, Reddy A. National cataract surgery survey 1997- 8: a report of results of clinical outcomes. *Br J Ophthalmol* 1999; 83(12): 1336-1340.
6. Kanski JJ. *Clinical Ophthalmology*. Oxford: Butterworth-Heinemann, 1994:3.
7. Gehrs KM, Anderson DH, Johnson LV, Hageman GS. Age related macular degeneration – emerging pathogenetic and therapeutic concepts. *Ann Med*. 2006; 38(7):450-71.
8. Ramkissoon YD, Sagoo MS, Charteris D. Managing disorders of the ageing eye. *The Practitioner* 2007; 251(1693)50,54,56.

In a nutshell

- Active screening for visual loss in the elderly should become routine.
- The evaluation of visual impairment should include visual symptoms, visual acuity testing and detection of visual field changes.
- Dilated fundal examination in high-risk groups is mandatory for early detection and timeous referral of treatable eye diseases.
- Presbyopia usually presents adults over 40 years of age and is easily treated with reading glasses.
- Cataracts are detected by the vision loss and opacities in the red reflex.
- Early POAG is asymptomatic and the diagnosis is based on raised IOP > 21 mmHg, increased cupping of the optic disc and visual field changes.
- Wet AMD is not curable or preventable and current treatments are largely directed at minimising visual loss.
- The management of retinal vascular diseases is directed towards early detection, treating the systemic cause and instituting antiplatelet therapy.
- Retinal vascular occlusions may be complicated by neovascularisation and macular oedema.
- In giant-cell arteritis, treatment with high-dose steroids should not be delayed because the risk of fellow eye blindness is very high.