

# Gastritis and gastropathy: more than meets the eye

*This paper discusses the different types of gastritides and gastropathies, focusing on their wide range of aetiologies.*

**Willie Nel, MB ChB, M Med (Anat Path)**

*Anatomical pathologist, Ampath Pathology Laboratories, Pretoria*

*Willie Nel did his undergraduate training at the University of the Free State and postgraduate training at the University of Pretoria. He joined the private practice of doctors Du Buisson and partners (Ampath) after two years as a consultant at the Institute of Pathology in Pretoria. Amongst his special interests are motorcycling and cattle breeding.*

Correspondence to: Willie Nel ([drnelw@ampath.co.za](mailto:drnelw@ampath.co.za))

Gastrointestinal symptoms such as dyspepsia, heartburn, epigastric pain, nausea and vomiting are extremely common and have been experienced by the majority of people at some stage in their lifetime. These complaints are often as a result of pathology in the upper gastrointestinal tract. Correlation between the clinical presentation (symptoms, signs and endoscopic findings) and pathology, including the degree and precise localisation of the disease process, is unfortunately notoriously poor. This is mainly due to the absence of a somatic nerve supply to the gut wall. The stomach is a common site of pathology responsible for upper gastrointestinal symptoms, which may have an extremely wide range of causes.

## **In pathological terms, gastritis is defined as inflammation of the gastric mucosa.**

In pathological terms, gastritis is defined as inflammation of the gastric mucosa. It is, however, a term often used loosely for clinical conditions associated with any upper gastrointestinal symptoms without clinical or radiological signs. Gastropathy, on the other hand, refers to a nonspecific microscopic injury pattern of stomach mucosa, with minimal or no inflammatory cell infiltration. Both gastritis and gastropathy may be clinically asymptomatic.

Acute gastritis is an acute mucosal inflammatory process, usually of transient nature, while chronic gastritis refers to

chronic inflammatory changes which may eventually lead to mucosal atrophy and epithelial metaplasia. Gastritis is a dynamic process, which can vary from acute to chronic (active or inactive), present in different stages of recovery or atrophy and may lead to complications. The inflammation may be diffuse, or affect predominantly the antrum or corpus.

The mucosa of the stomach is covered by a thin surface mucus layer serving, in conjunction with bicarbonate-secreting surface epithelial cells and local prostaglandin production, as a protective barrier against autodigestion and noxious agents. The gastric mucosa also has the ability to proliferate and replace damaged epithelium very rapidly.

In 1990 the Sydney system was developed as a guideline for the classification and grading of gastritis by a group of international experts in Sydney, Australia. This system combines topographical, morphological and aetiological information into a scheme that helps generate a reproducible and clinically useful diagnosis. Four years later this system was updated and subsequently modified to improve the criteria for evaluating atrophy. It recommends that at least five biopsy specimens (two from the greater and lesser curvatures of the corpus, one from the incisura angularis and two from the larger and lesser curvatures of the antrum) with mucosa and muscularis mucosae represented in each biopsy be evaluated. In practice, however, pathologists are usually asked to make a diagnosis on one or two biopsy specimens as most types of gastritis can be diagnosed without extensive tissue sampling.

The different types of gastritides and gastropathies and their wide range of aetiologies will now be discussed.

## **Acute gastritis**

### **Acute haemorrhagic gastritis**

Acute haemorrhagic gastritis is characterised by the presence of hyperaemic, oedematous mucosa, erosions/ulcers and active bleeding, and is usually seen in stress situations (e.g. severe burns), patients in ICU and after ingestion of large doses of aspirin, and other types of NSAID or large quantities of alcohol.

### **Acute gastritis in *Helicobacter pylori* infection**

The initial phase of *Helicobacter* infection causes an acute inflammatory reaction and degenerative changes in the surface epithelial cells of the gastric mucosa. Symptoms may include epigastric pain, a bloated feeling and nausea; these most often resolve within a week. After approximately two weeks the reaction evolves into an active chronic gastritis.

### **Acute bacterial or phlegmonous gastritis**

This is exceedingly rare and in many cases only identified at postmortem examination. Predisposing factors include immunosuppression, disability and chronic alcoholism. The most common infective organism is *Streptococcus*, but *Staphylococcus*, *Haemophilus influenzae*, *Escherichia coli* and *Proteus* spp have also been implicated. These bacteria cause an intense acute inflammatory response with ulceration and abscess formation involving the full thickness of the gastric wall. Patients present with nausea, vomiting,

## Gastritis and gastropathy

upper abdominal pain and tenderness, usually associated with a neutrophilic leukocytosis. The condition has a high mortality, but patients treated surgically have a better chance of survival.

### Chronic gastritis

#### *Helicobacter pylori* (HP) gastritis

These tiny spiral-shaped bacilli in the stomach were described for decades by pathologists, but were dismissed as irrelevant contaminants. In 1984 Warren and Marshall proposed their aetiological role in chronic idiopathic gastritis due to toxins released by the organisms directly affecting the gastric epithelium and local microcirculation.

**Gastritis is a dynamic process, which can vary from acute to chronic (active or inactive), present in different stages of recovery or atrophy and may lead to complications.**

HP gastritis has a high prevalence in developing countries, but has been declining in areas due to improved sanitary conditions and the widespread use of antibiotics. Natural acquisition of HP infection usually occurs in childhood and may persist for life. However, transient infections often occur. Direct person-to-person spread is the most likely mode of transmission, as no significant reservoir has been shown to exist outside the human stomach. Ingestion appears to be the most common means of acquiring HP. Routes of transmission include gastric-oral (by refluxed gastric juice or vomitus), and the faecal-oral route (during episodes of diarrhoea). Poor hygiene standards, crowded households, deficient sanitation and the absence of running water in the home are associated with a high prevalence of HP infection.

The endoscopist may find mucosal hyperaemia, erosions, hypertrophy and

even atrophy, but there are no distinctive endoscopic patterns of chronic HP gastritis. In the early phase an acute inflammatory response is elicited, which usually progresses to an active chronic gastritis. This may be antral-predominant, corpus-predominant or diffusely affect the stomach as a pangastritis (Fig. 1). After treatment, neutrophils disappear rapidly; their continued presence in biopsies is considered a valuable indicator of unsuccessful HP eradication. After successful treatment the intensity of the chronic inflammation declines, but patients may show persistence of chronic inactive gastritis for several years. Persistent infections may eventually lead to atrophic gastritis, which may be antrum-restricted or involve the stomach more extensively.

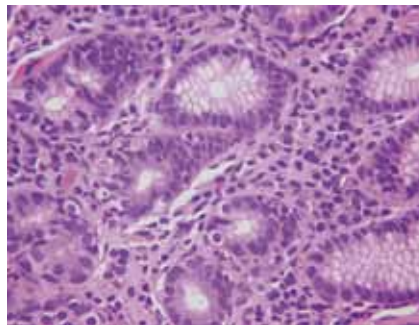


Fig. 1. A biopsy demonstrating chronic active gastritis — a background of chronic inflammation, with neutrophils present between the glandular epithelium.

Diagnosis of HP infection can be rendered using invasive and noninvasive tests. Invasive tests are based on endoscopy and histological examination of gastric biopsies (Fig. 2). These have the advantage of allowing direct evaluation the upper GI tract for any superimposed complications. The number of organisms in biopsy material may be markedly reduced (even absent) due to antibiotic treatment prior to biopsy, the use of proton pump inhibitors (PPIs) or in chronic atrophic gastritis. Noninvasive diagnostic tests include the C-urea breath test (only performed in certain centres), detection of serum IgG antibodies directed against HP and stool HP antigen tests, some of which can also be used for follow-up. As a method to evaluate HP eradication, the C-urea breath test should preferably

be performed 4 weeks after the end of therapy, as the test may produce a false-negative result with persistent infection due to temporary inactivation of the pathogen shortly after treatment. HP serology is relatively sensitive and specific with no interference due to the intake of bismuth, antibiotics and PPIs. There is no correlation between the IgG antibody titres and the severity of the HP gastritis, however, and a decrease in titres less than 6 months after therapy is of no diagnostic value in verifying successful eradication.

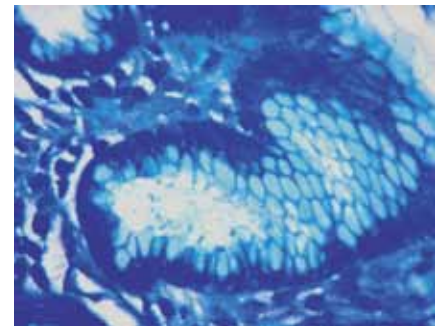


Fig. 2. Curved *Helicobacter pylori* bacilli adjacent to the gastric epithelium on a methylene blue stain.

More than 50 species of *Helicobacter* have been described, but only a few have been shown to cause gastritis. In about 0.1 - 2.7% of cases *H. heilmannii* is identified. These organisms are twice as long as HP and usually cause a milder and patchier gastritis. Treatment is similar to that for HP infections.

**The initial phase of a *Helicobacter* infection causes an acute inflammatory reaction and degenerative changes in the surface epithelial cells of the gastric mucosa.**

Some patients with HP are asymptomatic and go undetected, but all patients in whom HP infection is identified should undergo treatment. If untreated, HP gastritis confers

## Gastritis and gastropathy

a 15 - 20% lifetime risk of developing peptic ulcer disease (Fig. 3). Eradication of HP facilitates healing of these ulcers and prevents their recurrence. More than 90% of primary gastric mucosa-associated lymphoid tissue (MALT) lymphomas are seen in patients with HP gastritis, and more than 75% will regress for extended periods upon successful eradication of the infection. Atrophic gastritis is also a risk factor for dysplasia and intestinal type adenocarcinoma.

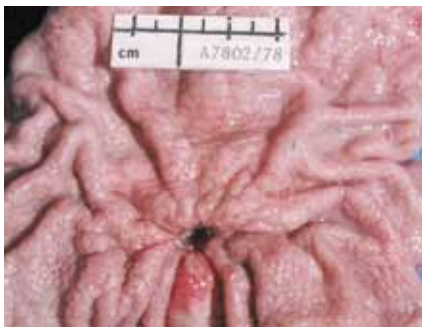

Fig. 3. Macroscopic appearance of a gastric chronic peptic ulcer (courtesy of Dr M Louw, Department of Anatomical Pathology, University of Pretoria).

Triple therapy with either amoxicillin or metronidazole, clarithromycin and a PPI given twice daily for 7 - 14 days is recommended as first-line therapy. As second line therapy levofloxacin, amoxicillin and PPI for 10 -14 days or bismuth-based quadruple therapy are recommended. Increasing HP resistance to various antibiotics is a significant concern, however.

### Autoimmune gastritis

This corpus-restricted gastritis is associated with circulating autoantibodies against the microsomes of parietal cells as well as intrinsic factor. Intrinsic factor plays a key role in the absorption of vitamin B<sub>12</sub>, and gastric acid is important for absorption of iron. Destruction of the cells producing hydrochloric acid and intrinsic factor, respectively, results in hypochlorhydria and a reduction in pepsin activity within gastric juices and may lead to pernicious or iron deficiency anemia. The finding of a low pepsinogen I level in the serum is a sensitive and specific indicator of gastric atrophy.

Endoscopically, the mucosa of the corpus is thinner than normal. Often a reduction or absence of rugal folds and small mucosal elevations due to the presence of islands of intestinal metaplasia are seen. In the florid phase microscopy reveals a dense infiltrate of lymphocytes and plasma cells involving the entire thickness of the corpus mucosa with destruction of the oxyntic glands. As atrophy sets in, the mucosa shows a marked reduction of these glands, reduced inflammation and increasing degrees of intestinal and pyloric metaplasia. Metaplasia refers to replacement of normal gastric epithelium by modified cells of intestinal or pyloric variety. The hypo-/achlorhydria cause physiological hypergastrinaemia, which in turn stimulates proliferation of neuroendocrine cells and can lead to development of neuroendocrine tumours ('carcinoids'). These tumours are relatively innocuous, in contrast to the less common solitary, sporadic type which is more aggressive.

### Lymphocytic gastritis

A diagnosis of lymphocytic gastritis can only be made on histology, but many patients have the endoscopic features of varioliform gastritis with mucosal nodules, chronic persistent erosions and thickened mucosal folds. The disease is characterised by an infiltrate of lymphocytes in the lamina propria with large numbers of lymphocytes among the epithelial cells lining the surface and foveolae.

**More than 50 species of *Helicobacter* have been described, but only a few have been shown to cause gastritis.**

The aetiology remains uncertain, although an allergic or autoimmune pathogenesis is proposed. Lymphocytic gastritis may be found in association with coeliac disease (gluten-sensitive enteropathy), Menetrier's disease (hypertrophic gastropathy characterised by a hypertrophic gastric mucosa with convoluted, thickened mucosal folds and protein-losing enteropathy), as an abnormal response to HP infection

or NSAID use, or in association with lymphocytic/collagenous colitis. Treatment is steroids and management of any underlying cause.

### Collagenous gastritis

This is a rare entity characterised by a thickened subepithelial band of collagen and chronic inflammatory infiltrate in the gastric mucosa, similar to that seen in collagenous colitis. The disease may be limited to the stomach, then usually in children and young adults presenting with anaemia due to gastric bleeding, and demonstrate focal nodularity of the gastric mucosa on endoscopy. It may also be found in adults with collagenous colitis and present with a chronic watery diarrhoea.

### Eosinophilic gastritis

Eosinophilic gastritis and gastroenteritis may affect all age groups and present with failure to thrive (in children), abdominal pain, irritability, gastric dysmotility, vomiting, diarrhoea, dysphagia and (in severe cases) protein-losing enteropathy. Many patients are atopic and have increased serum total IgE and food-specific IgE, as well as blood eosinophilia. This entity is characterised by eosinophil-rich inflammation of all or

a portion of the GI tract wall. Gastroscopy may reveal antral mucosal swelling and redness with narrowing of the pylorus and diminished peristalsis.

### Chemical gastropathy refers to endoscopic and histological changes caused by chemical injury to the gastric mucosa.

Improvement after elimination of certain foods from the diet supports an allergic aetiology. Parasites and drug reactions are a much less common cause.

#### Granulomatous gastritis

This group of conditions is characterised by multiple granulomas in the gastric mucosa and has a long list of possible causes. This includes infections such as tuberculosis and histoplasmosis, foreign body reaction directed against postoperative sutures or food trapped in ulcers, tumours such as mucus-producing adenocarcinomas and lymphomas, as well as systemic granulomatous diseases such as sarcoidosis, Crohn's disease and Wegener's granulomatosis.

#### Opportunistic infections of the stomach

Immunocompromised patients are at risk for opportunistic GI infections, with the stomach relatively rarely affected in comparison to the rest of the gut.

Fungal infections include gastric candidiasis, which may appear as a white plaque which can be removed to reveal a reddened underlying mucosa, or as a saprophyte colonising the necrotic debris in an ulcer base, aggravating the disease. GI phycomycosis (zygomycosis, mucormycosis) is rare, may be associated with diabetes mellitus and results in ulceration and invasion of blood vessels by the fungus. Cryptococcus and Histoplasma gastric infections are seen in conjunction with disseminated disease. Viral infections

such as cytomegalovirus and herpes simplex virus more commonly affect the oesophagus, but may also demonstrate gastric involvement with ulceration. Toxoplasmosis and cryptosporidiosis (Fig. 4) are protozoal infections which may affect the stomach.

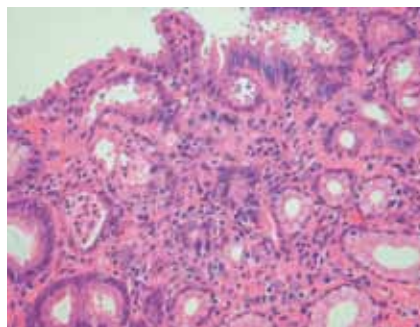


Fig. 4. Gastric biopsy showing *Cryptosporidium* spp. infection, with large numbers of small spherical parasitic organisms adjacent to the epithelium.

#### Gastropathy

##### Chemical (reactive) gastropathy

Chemical gastropathy was recommended as the preferred term to synonyms such as chemical gastritis, type C gastritis and reactive gastropathy, and refers to endoscopic and histological changes caused by chemical injury to the gastric mucosa.

### Immunocompromised patients are at risk for opportunistic gastrointestinal infections, with the stomach relatively rarely affected in comparison to the rest of the gut.

Chemical agents commonly associated with mucosal damage include:

- Medications, particularly NSAIDs, but also drugs such as PPIs, iron, kayexalate, colchicine, antineoplastics and corticosteroids. NSAIDs cause mucosal damage by reducing prostaglandin synthesis. Second-generation and selective NSAIDs and COX-2 inhibitors

are better tolerated by the gastric mucosa. Endoscopically, long-term users of NSAIDs may show mucosal erythema, congestion, erosions and ulcers. Histologically the mucosa reveals oedema, foveolar hyperplasia, smooth-muscle proliferation, regeneration and, on occasion, erosion with a relatively mild inflammatory cell response.

- Duodenopancreatic (bile) reflux is seen particularly in patients with a Billroth II partial gastrectomy. A chronic gastritis with marked foveolar hyperplasia, which may be cystic or polypoid, develops proximal to the stoma.
- Acids, alkalis and large quantities of alcohol. Most of these cause extensive severe, necrotising lesions.

#### Vascular gastropathy

Vascular gastropathy refers to a group of disorders characterised by distinct alterations in the gastric mucosal blood vessels and a paucity or absence of inflammation.

- Gastric antral vascular ectasia (GAVE or 'watermelon stomach') is a rare condition

Table I. Aetiology of gastritis and gastropathy

#### Gastritis

- Acute
  - Stress
  - NSAIDs
  - Alcohol
  - Helicobacter* (early phase)
  - Bacteria (phlegmonous)
- Chronic
  - Helicobacter*
  - Autoimmune
  - Allergy
  - Tuberculosis
  - Opportunistic infections
  - Idiopathic

#### Gastropathy

- Chemical
  - Medications
  - Bile reflux
  - Acids, alkalis, alcohol
- Vascular
  - Portal hypertension
  - Vascular ectasia (idiopathic)



## Gastritis and gastropathy

of unknown aetiology. Endoscopy shows longitudinal mucosal folds with ectatic vessels converging from the proximal antrum into the pylorus. Histology reveals marked dilated mucosal capillaries, some of which may be thrombosed, and features of reactive gastropathy. Patients may present with occult bleeding, melaena, haematemesis and anaemia.

- Portal hypertensive gastropathy is seen in patients with portal hypertension who may present with gastric haemorrhage due to dilatation, congestion and proliferation of mucosal blood vessels,

most prominent in the proximal stomach. The endoscopic appearance may resemble snake skin, cherry red spots or have a mosaic pattern. Decompression of the portal hypertension by means of bypass surgery reduces the risk of haemorrhage.

The varied aetiologies of gastritis and gastropathy are summarised in Table I.

### Conclusion

Gastritis and gastropathy may be clinically silent or present with central upper abdominal symptoms, and have a wide

range of causes. *H. pylori* infection is common worldwide and, if left untreated, is associated with complications including peptic ulcer disease, atrophic gastritis and gastric neoplasms. Chemical injury to the gastric mucosa due to medications such as NSAIDs, bile reflux and the intake of large quantities of alcohol is well known, as are autoimmune reactions causing atrophic gastritis and allergies to food which may result in an eosinophilic gastritis.

Further reading available at [www.cmej.org.za](http://www.cmej.org.za)

## IN A NUTSHELL

- Gastritis and gastropathy are common causes of upper gastrointestinal symptoms.
- Correlation between clinical presentation, endoscopic features and biopsy findings is poor.
- Gastritis refers to inflammation of the gastric mucosa, whereas gastropathy is a nonspecific microscopic injury pattern with little or no inflammatory cell infiltration.
- Gastritis and gastropathy are associated with a wide range of aetiologies (causes).
- Gastritis is divided into acute and chronic forms.
- The commonest form of acute gastritis is acute haemorrhagic gastritis.
- *Helicobacter*-associated and autoimmune gastritis are the commonest types of chronic gastritis.
- Less common and more unusual forms of gastritis include eosinophilic, lymphocytic, collagenous and granulomatous gastritis.
- Opportunistic gastric infections may be caused by numerous fungi, parasites and viruses.
- Gastropathy is most often due to chemical irritation of the gastric mucosa.