

More about...Ophthalmology

Vision 2020 – the right to sight

COLIN COOK, MB ChB, FCS (Ophth) SA,
FRC Ophth

Professor, Division of Ophthalmology, Faculty
of Health Sciences, University of Cape Town

What is it? – The concept

Vision 2020 is an initiative of the World Health Organization (WHO) and the International Agency for the Prevention of Blindness (IAPB), for the global elimination of avoidable blindness (by the year 2020) – ‘to eliminate the main causes of avoidable blindness in order to give all people in the world, particularly the millions of needlessly blind, the right to sight.’ It is a global programme that has been developed as a partnership between the IAPB member NGOs, the WHO, and WHO member governments or ministries of health. It was launched by the WHO in 1999.

Why is it? – The rationale

In 2000, the estimated global prevalence of blindness was 50 million, with an annual incidence of 6 million and an annual increase in the backlog of 1 - 2 million. It was estimated that if present trends continued, the prevalence would increase from 50 million in 2000 to 75 million in 2020. As much as 80% of blindness is avoidable – 60% is treatable (as in blindness due to cataract) and 20% is preventable (as in blindness due to glaucoma). While 70% of global blindness occurs in Asia and 20% in Africa, Africa has the highest burden of blindness. 80% of blindness occurs in people over 50 years of age. The prevalence is higher in females. The prevalence in particular communities or health districts correlates with the socio-economic level, varying from 0.25% in communities with a good economy to 1% or more in communities with a very poor economy.

Cataract is the leading cause of global blindness, responsible for an estimated 50% of blindness. Other important causes are chronic glaucoma, age-related macular degeneration, and diabetic retinopathy. Trachoma and onchocerciasis (‘river blindness’) are important focal causes in some regions of Africa, Asia, and Latin America. Childhood blindness is also

an important cause of blindness if one considers the burden of blindness as ‘blind person years’.

As much as 80% of blindness is avoidable, and yet the numbers are increasing. This has been the imperative for Vision 2020. It is estimated that, with the successful implementation of Vision 2020, the numbers of blind people can be halved from 50 million to 25 million by the year 2020.

How is it? – The structure

The key strategies recommended for the Vision 2020 programme are:

- human resource development
- infrastructure development
- disease control.

While it is recommended that each country should have a national Vision 2020 programme to set policies and guidelines, it is recommended that there should be a programme for each service unit (district or province) of about 1 million population. This programme should comprise both a hospital-based component (a Vision 2020 surgical centre, which should be an ophthalmology department in a hospital) and a community-based component (which should comprise screening and management activities at the community, primary, and secondary levels). The programme should be in a horizontal format, and its activities should be integrated into the existing health service structures.

A chain of training, supervision, support, and referral that extends from the community level to the primary, secondary, and tertiary levels is recommended. Guidelines are provided for the human resources needed at the different levels, with recommendations for the numbers required, their training, and their skills. For a health district of 1 million population, 100 clinic nurses trained in primary eye care are required. This training should be a 3 - 5-day workshop, and could be incorporated into a primary health care training. For the same health district, 10 mid-level ophthalmic nurses are required. Their training should be of 1 year duration, and they should be able to function as independent clinicians, to examine, diagnose, and treat people presenting with eye problems. It is recommended that there should be 4 optometrists and 2

ophthalmologists or ophthalmic medical officer cataract surgeons in such a health district. In South Africa, the ophthalmic medical officer cataract surgeons would be general practitioners who have a diploma in ophthalmology and who are trained to do routine uncomplicated cataract surgery.

The priority diseases for the first phase of Vision 2020 are cataract and refractive error. While refractive error is an insignificant cause of blindness (visual acuity less than 3/60 in the better eye with available refractive correction), it is an important cause of visual impairment (visual acuity 6/24 - 6/60) and severe visual impairment (visual acuity 5/60 - 3/60). Like cataract, it occurs everywhere, and the strategies to deal with it are well understood. Patients with cataract need surgery, and patients with refractive error need refractive correction! Cataract surgery is the most cost effective of all surgeries, and is one of the most cost effective of all health interventions. A cataract surgery rate of 2 000 or more per million population per year should eliminate blindness due to cataract over a 5-year period. It is possible for 1 cataract surgeon doing surgery on 4 mornings each week to do this number of surgeries each year.

In areas where they occur, trachoma and onchocerciasis are also prioritised for the first phase of Vision 2020. Once structures and systems are in place to deal with cataract and refractive error, glaucoma and diabetic retinopathy are prioritised for the second phase of Vision 2020.

Reference

1. World Health Organization. *Global Initiative for the Elimination of Avoidable Blindness*. Geneva: WHO, 1997. WHO/PBL/97.61.

Refractive surgery – where do we stand?

POLLA ROUX, MB ChB, DVG, MPraxMed,
MMed (Ophth), FCO (SA), FRC Ophth (UK)

Head, Department of Ophthalmology,
University of Pretoria

Refractive surgery corrects myopia, astigmatism and hyperopia. Spectacles and contact lenses are still a good option for patients who tolerate them well. However, the modern method of refractive correction is with surgery. Excimer laser

More about...

ablation of the cornea, or lens implants, are the procedures most widely used.

LASIK (laser-assisted *in situ* keratomileusis) is the procedure of choice to correct myopia of 1 - 7 diopters (D), hyperopia of 1 - 3 D and astigmatism up to 5 D. Above these parameters, lens implants are the best option and up to 20 D of myopia and 10 D of hyperopia can be corrected with good visual results. Presbyopia (blurring of near objects in people over the age of 45 years) has no successful long-term surgical remedy to date. Reading spectacles, multifocal spectacles and monovision are still recommended as the best options for the correction of presbyopia.

As refractive surgery has grown in popularity over the last decade, the types of surgical options available to correct a patient's refractive error have also increased in number and become more complex. In a recent annual survey that evaluated the variety and volume of refractive surgery the American Society of Cataract and Refractive Surgery (ASCRS) reported that LASIK is still the number one technique being performed in the USA (approximately 1.5 - 2.0 million LASIK procedures are performed annually in the USA). In South Africa LASIK similarly remains the procedure of choice for patients requesting refractive surgery.

Laser refractive surgery: new trends

Mechanical and laser LASIK flap creation

During LASIK a thin corneal flap of about 150 microns is created by means of a keratome. The keratome is a mechanical device similar to a dermatome (used to create skin grafts) but is much smaller and more precise. The flap is 8 - 9 mm in diameter and is hinged on the nasal or superior side of the cornea. Once the flap has been cut, it is elevated to the side of the hinge and the excimer laser then ablates the desired refractive correction into the stroma of the cornea. After the ablation is completed in about 15 - 60 seconds, the flap is replaced in the exact same position as before the cut with the keratome. This is called lamellar surgery because of the creation of a flap. Rarely the flap creation can be complicated by being too thin, incomplete, buttonholed etc. Photorefractive keratectomy (PRK) refers to excimer laser done without first creating a flap. The epithelium then needs to heal, which takes a few days following the procedure.

Many potential complications of lamellar surgery may be minimised with laser flap-

cutting techniques (femtosecond lasers), which allow greater predictability of flap shape, integrity, and thickness, and are less dependent on the anatomy of an individual cornea.

Ultra-short pulsed femtosecond (FS) lasers now offer an alternative to blade-assisted mechanical microkeratomes for the creation of lamellar keratectomy flaps. This has led to the term all-laser LASIK, which is a relatively new technology.

Visual outcomes

As visual results of modern LASIK surgery are excellent, it is difficult to demonstrate clear superiority of one flap creation technique over another. However, two recent peer-reviewed publications (one of which was a prospective, randomised, double-blinded study) suggested that FS laser-assisted LASIK produced both subjective and objective visual outcomes superior to mechanical LASIK in terms of both uncorrected visual acuity and magnitude of induced higher-order aberrations.¹⁻³ Cost is however an important factor and the additional outlay of the FS laser and disposables is dampening the wider use of this technology.

Phakic intraocular lens (IOL) implant

Patients with higher refractive errors of 7 and more diopters of myopia or 4 and more diopters of hyperopia, have other options like IOL implants and refractive lensectomy.⁴

The Artisan lens is an iris-fixated lens and is now also available in South Africa in the Artiflex model, which is a foldable lens and can be inserted via a 3 mm corneal incision.

Long-term considerations

In the largest prospective Artisan lens clinical trial in Europe, the results were similar to the FDA clinical trials. This study consisted of 518 patients who had Artisan lenses implanted at 9 sites from 1991 to 1999. These patients had preoperative myopia of 5 D - 20 D (5-mm optic only) with a 3-year follow-up reported on 249 patients. Results demonstrated refractive stability and good predictability with a favourable risk:benefit ratio. Efficacy and safety were demonstrated in this clinical trial.⁵

Any residual refractive error can be corrected with laser enhancement PRK or LASIK. Timing is important - it is reasonable to wait 6 months before performing PRK and 1 year before performing LASIK after a phakic IOL procedure.⁶

Presbyopia

The surgical treatment of presbyopia is the next frontier to cross in the next few years. So far the surgical procedures on phakic patients, e.g. scleral expansion, have only a short-term effect of about 6 months. Multifocal excimer ablation of the cornea is possible but is not widely used. Reading spectacles, multifocal spectacles, multifocal contact lenses and monovision are still the only long-term options for patients.

Accommodating intraocular lenses

Accommodation allows the phakic eye to change focus from distant objects to closer objects. During accommodation, an interaction between the ciliary muscle and the crystalline lens allows the required optical power change to take place. In a pseudophakic eye certain IOLs are designed to provide a degree of accommodation as well.

Many problems still remain in this field of development, with lens capsule fibrosis being the major hurdle to overcome to ensure that an elastic, reactive lens capsule remains after cataract surgery.

Monovision

Indications

Monovision is an option offered to presbyopic patients when one eye (the 'reading eye') is left slightly nearsighted while the other eye is corrected for the full-distance correction. Monovision can be created with contact lenses, refractive surgery, and intraocular lenses. Not all patients are good candidates for monovision, however, and not all patients will successfully adapt to it.⁷⁻⁹

Surgical creation of monovision can be successful in a high percentage of appropriately selected patients, reducing dependence on corrective lenses. As with all refractive surgical procedures, preoperative discussion will help patients make intelligent choices between monovision and bilateral distance correction. The typical reduction of stereo-acuity should be described to patients, and a preoperative trial of monovision (ideally with contact lenses) with the reading eye typically left 1.5 D nearsighted is helpful. We strongly encourage offering monovision as an option for patients considering refractive surgery.

References

1. Kezirian GM, Stonecipher KG. Comparison of the IntraLase femtosecond laser and mechanical keratomes for laser *in situ* keratomileusis. *J Cataract Refract Surg* 2004; 30: 804-811.

- Durrie DS, Kezirian GM. Femtosecond laser versus mechanical keratome flaps in wavefront guided laser *in situ* keratomileusis: prospective contralateral eye study. *J Cataract Refract Surg* 2005; 31: 120-126.
- Tran DB, Sarayba MA, Bor Z, *et al.* Randomized prospective clinical study comparing induced aberrations with Intralase and Hansatome flap creation in fellow eyes: potential impact on wavefront-guided laser *in situ* keratomileusis. *J Cataract Refract Surg* 2005; 31: 97-105.
- Pop M, Payette Y. Refractive lens exchange versus iris-claw Artisan phakic intraocular lens for hyperopia. *J Refract Surg* 2004; 20: 20-24.
- Budo C, Hessloeh J, Izak M, *et al.* Multicenter study of the Artisan phakic intraocular lens. *J Cataract Refract Surg* 2000; 26: 1163-1171.
- Guell JL, Vazquez M, Gris O, De Muller A, Manero F. Combined surgery to correct high myopia: Iris claw phakic intraocular lens and laser *in situ* keratomileusis. *J Refract Surg* 1999; 15: 529-537.
- Maguen E, Nesburn AB, Salz JJ. Bilateral photorefractive keratectomy with intentional unilateral undercorrection in an aircraft pilot. *J Cataract Refract Surg* 1997; 23: 294-296.
- Wright KW, Guemes A, Kapadia MS, Wilson SE. Binocular function and patient satisfaction after monovision induced by myopic photorefractive keratectomy. *J Cataract Refract Surg* 1999; 25: 177-182.
- Erickson DB, Erickson P. Psychological factors and sex differences in acceptance of monovision. *Percept Mot Skills* 2000; 91: 1113-1119.

The eye and HIV/AIDS

LINDA VISSER, MB ChB, MMed (Ophthalm), FCS (Ophthalm) SA

Head, Department of Ophthalmology and Lecturer, Nelson R Mandela School of Medicine, University of KwaZulu-Natal, Durban

Chief Specialist Ophthalmology, Inkosi Albert Luthuli Central Hospital, Durban

It is estimated that there are 5.5 million people in South Africa living with HIV/AIDS.¹ A relatively small percentage of them are on highly active antiretroviral therapy (HAART). As their CD4 cell counts decrease, they become prone to developing certain opportunistic infections and tumours. A large percentage of them (70 - 75%) develop ocular disease during the course of their illness – it may be the first sign of HIV infection.

Ophthalmic manifestations are usually due to underlying microvasculopathy, opportunistic infections, neoplasms or autoimmune reactions and can be classified according to clinical presentation into anterior segment, posterior segment, neuro-ophthalmic and orbital manifestations.

Anterior segment, ocular surface and ocular adnexal manifestations

Herpes zoster ophthalmicus (HZO)

Patients under 40 years of age who present with HZO are usually HIV positive. Their clinical course is worse than that of HIV-negative patients. HZO can occur early or late in the course of the HIV disease. Ocular involvement may be severe.

Patients present with a painful vesicular dermatitis localised to the dermatome supplied by the trigeminal nerve (usually V1 or the ophthalmic division). The vesicles become pustules in 3 - 4 days, then dry and crust in 10 - 12 days. The dermatitis involves deep layers of the skin and may resolve with scarring and pigmentation. Neuralgia in the dermatome can continue for months or years.

Ocular involvement is common (> 70%). A vesicle on the tip of the nose (Hutchinson's sign) must alert one to globe involvement. This can manifest as conjunctivitis, keratitis (either dendritic or neurotrophic), episcleritis, scleritis or uveitis. Secondary bacterial infection often occurs, compounding the scarring and leading to cicatricial entropion or ectropion. Chronic inflammation may lead to corneal vascularisation, corneal opacification, lipid keratopathy, corneal thinning and even corneal perforation (Fig. 1).

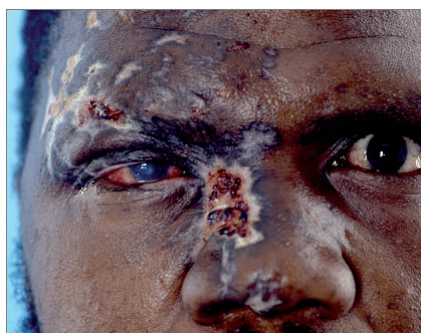

Fig. 1. Cicatricial changes following HZO.

Treatment

- Antivirals
 - Acyclovir 800 mg 5x/day or
 - Valaciclovir 1 g tid
- Analgesics for acute pain
 - E.g. ibuprofen
- Amitriptyline at night for neuralgia.

Herpes simplex virus (HSV) infection

HSV is one of the leading causes of chronic, infectious ocular disease in immunocompetent patients. Keratocon-

junctivitis, keratitis (dendritic ulcers) or kerato-uveitis can occur. In HIV these ulcers recur more frequently and dendrites are often located more peripherally on the cornea. Patients often need systemic and topical acyclovir treatment due to a relative resistance to treatment.²

Molluscum contagiosum

Molluscum contagiosum presents as small, elevated, umbilicated lesions of the eyelid. These are often multiple and occur bilaterally, in AIDS patients.

Treatment

- Surgical excision
- Curettage
- Cryotherapy
- Liquid nitrogen
- Topical phenol or trichloroacetic acid.²

Ocular surface squamous neoplasia (OSSN)

Seventy to eighty per cent of patients under the age of 50 years with OSSN are HIV positive.² Clinically it presents as an elevated, well-demarcated grey to red mass, usually in the interpalpebral area. It often straddles the nasal or temporal limbus and may have prominent feeder vessels and surface keratin. It is more aggressive in HIV-positive patients (Fig. 2).

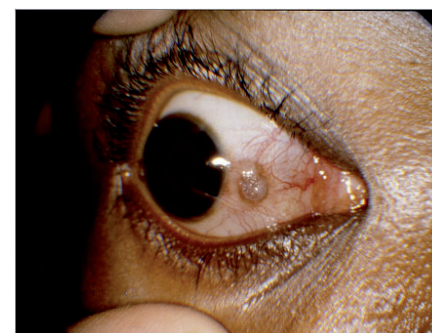


Fig. 2. OSSN with prominent feeder vessel.

Treatment includes the following:

- Surgery
 - Complete local excision with or without lamellar dissection into sclera or corneal stroma
 - Enucleation of the globe or exenteration of the orbit if neglected and tumour invades the eye or orbit
- Cryotherapy
- Radiotherapy
- Topical mitomycin-C or 5-fluorouracil.

Kaposi's sarcoma

Kaposi's sarcoma develops in almost 30% of AIDS patients – 20% of these sarcomas involve the eyelid skin or conjunctiva.

More about...

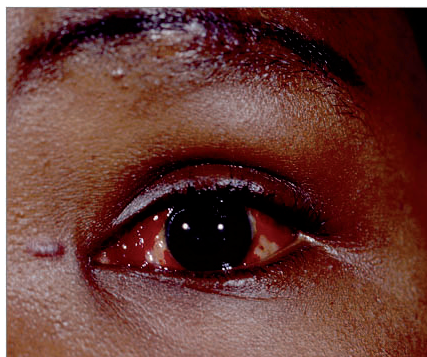

Fig. 3. Conjunctival Kaposi's sarcoma.

They are more malignant when associated with HIV and can disseminate. They present as flat or elevated red/purple subepidermal/subepithelial nodules (Fig. 3).

Indications for treatment of ocular disease include loss of eyelid function, cosmesis and discomfort, and the type of treatment depends on the size and location of the tumour.

Treatment includes the following:

- Local
 - Radiotherapy
 - Cryotherapy
 - Surgical excision
- Intralesional chemotherapy and sub-conjunctival interferon alpha-2a
- Systemic
 - Combination chemotherapy
 - Immunotherapy (interferon alpha).

Other ocular surface disorders

Dry eyes, blepharitis and atopic eyelid disease are all more prevalent in HIV-infected individuals. Artificial tear replacement and lid hygiene are of paramount importance, and in cases of severe atopic disease topical steroids are indicated.

Posterior segment manifestations

Cytomegalovirus retinitis (CMVR)

This is the most common cause of vision loss in patients with AIDS. It is typically seen in advanced stages of AIDS when the CD4 count is less than 50 cells/mm³. Approximately 25% of patients not on HAART with a CD4 count below 100 cells/mm³ will develop CMVR within 1 year. The clinical appearance can vary but usually consists of:

- full-thickness retinal opacification with or without haemorrhage (Fig. 4)
- minimal overlying vitritis, except where large areas of retina are involved or where there is partial immune recovery from HAART
- retinal vasculitis/periphlebitis.

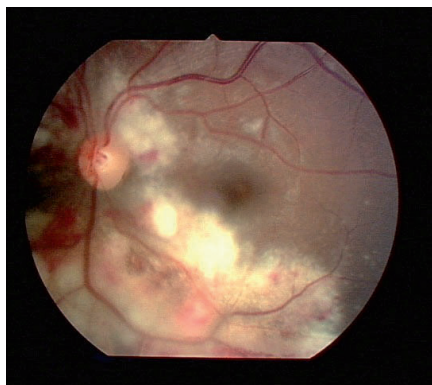


Fig. 4. CMVR with full-thickness retinal necrosis and haem.

Loss of vision occurs as a result of involvement of the optic nerve or macula, retinal detachment or immune recovery uveitis with cystoid macular oedema (CME), vitreous opacity or epiretinal membrane (seen only in patients on HAART).

Readily available **treatment** includes intravenous or intravitreal ganciclovir. Because of its cost-effectiveness, intravitreal ganciclovir is the preferred method of treatment in the public sector.³

Progressive outer retinal necrosis (PORN)

PORN is caused by infection with HSV or varicella zoster virus (VZV). Patients often have a history of cutaneous zoster infection, recent chicken pox infection or HSV ulcer on the lip or eye. There is rapid progression of retinal necrosis in a circumferential fashion with relative sparing of retinal vasculature early in the course of the infection (Fig. 5). The outcome is often poor with 67% of the patients becoming blind within 1 month, mainly due to rhegmatogenous retinal detachment.⁴

Treatment is with intravitreal ganciclovir injections.

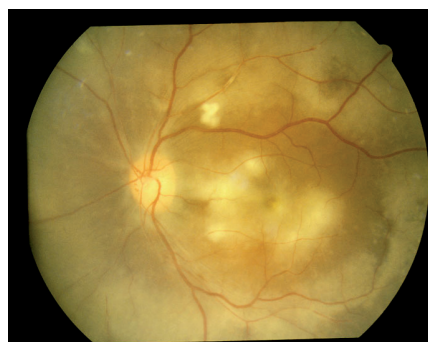

Fig. 5. Outer retinal necrosis with relative sparing of the infection.

Toxoplasmosis chorioretinitis

Infection with *Toxoplasma gondii* results in intense, white focal areas of retinal necrosis. These can be solitary, multifocal or occur in a miliary pattern. The lesions are

usually larger than in immunocompetent individuals and there may be no pre-existing retinal scarring (Fig. 6). There is always substantial inflammation in the vitreous and invariably the patient will have concomitant central nervous system (CNS) involvement.

Treatment is with megadoses of cotrimoxazole or a combination of pyrimethamine (50 - 100 mg loading dose, then 25 - 50 mg daily orally) and folinic acid (5 mg 3 times weekly - orally) and either:

- sulfadiazine 1 g qid
- clindamycin 300 - 450 mg qid
- azithromycin 250 mg daily, or
- atovaquone 750 mg tid.

Prednisone (high dose, short course) must be given if sight is threatened.⁵

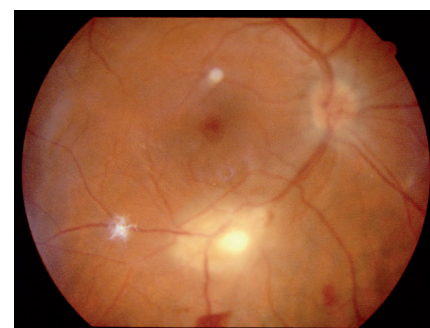


Fig. 6. Toxoplasmosis lesion along the inferotemporal arcade.

HIV microangiopathy

Nerve fibre layer infarcts or 'cotton wool spots' are part of HIV microangiopathy. The CD4 count is usually below 50 cells/mm³ when these occur. They can be seen at the posterior pole or around the optic disc and may be associated with a small intraretinal haemorrhage similar to a small focus of CMVR, which may make them difficult to distinguish from early CMVR (Fig. 7). They resolve spontaneously over several months. A repeat examination must be done every 2 weeks to distinguish them from CMVR.

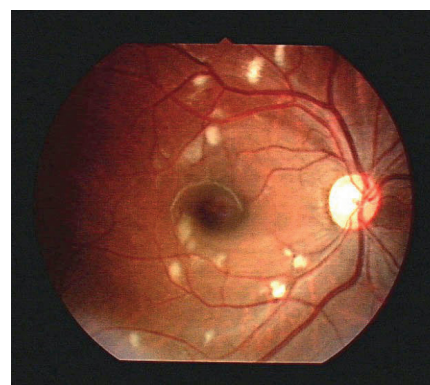


Fig. 7. Multiple cotton wool spots in the posterior pole.

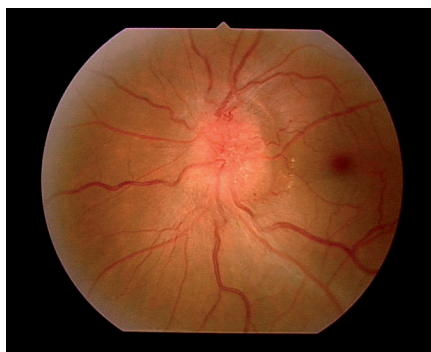


Fig. 8. Chronic papilloedema.

Neuro-ophthalmic manifestations

Optic neuritis

In immunocompromised patients, optic neuritis can be caused by HIV *per se* or it can be associated with neurosyphilis, tuberculous meningitis, cryptococcal meningitis, toxoplasmosis or viral (CMV or HSV) encephalitis. Unilateral or bilateral occurrence is possible. Severe decrease in vision is typical. As vision can be lost permanently, systemic steroids are indicated in severe cases (high dose, short course).

Cranial nerve palsies

Cranial nerve palsies usually occur as a result of CNS lymphoma or CNS infection, e.g. neurosyphilis, but can also be secondary to microvasculopathy or HIV infection *per se*. Often multiple cranial nerves are involved simultaneously.

Papilloedema

This is secondary to:

- cryptococcal meningitis

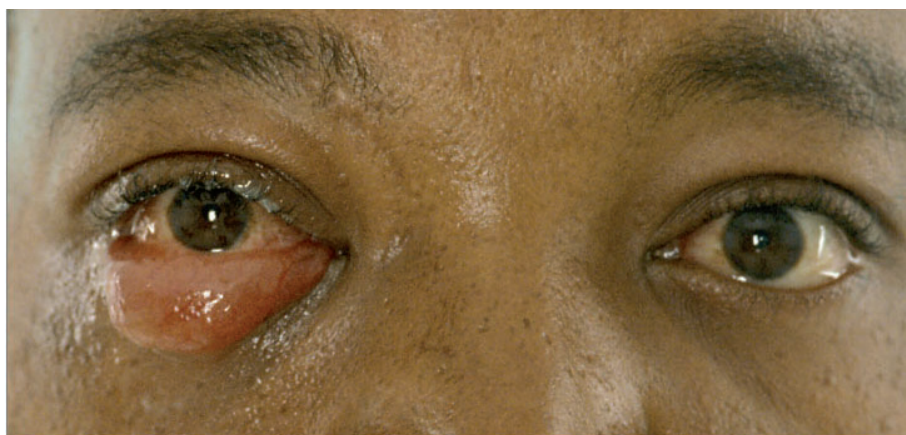

Fig. 9. Right proptosis and chemosis secondary to orbital.

- TB meningitis
- CNS toxoplasmosis
- neurosyphilis
- CNS lymphoma and other intracranial tumours.

Vision may be retained unless papilloedema is chronic (Fig. 8).

Orbital manifestations

These are rare, but include ptosis and proptosis caused by infection, inflammation and tumours arising from the paranasal sinuses or intraorbital tissues. Orbital lymphoma typically presents with a painful proptosis (Fig. 9).


Summary

HIV/AIDS is on the increase in South Africa. More than 70% of patients will develop ocular complications at some stage during their illness and sometimes the ocular disease will prompt the diagnosis of HIV.


References

1. Nelson Mandela/HSRC study of HIV/AIDS. Household survey. South African National HIV prevalence, behaviour and mass media. www.kznhealth.gov.za/italian.htm (last accessed August 2007).
2. Jeng BH, Holland GN, Lowder CY, Deegan WF, Meisler DM. Anterior segment and external ocular disorders associated with human immunodeficiency virus disease. *Surv Ophthalmol* 2007; 52(4): 329-354.
3. Morlet N, Young S, Naidoo D, Graham G, Coroneo MT. High dose intravitreal ganciclovir injection provides a prolonged therapeutic intraocular concentration. *Br J Ophthalmol* 1996; 80: 214-216.
4. Dunn JP, Martin DF. Treatment of cytomegalovirus (CMV) retinitis in the era of highly active antiretroviral therapy. A comprehensive clinical update on the treatment of CMV retinitis in the HAART era. *Clinical Review*, Medscape HIV/AIDS, Sept 2003. www.medscape.com/viewpoint/663 (last accessed October 2007).
5. Yanoff M, Duker JS. *Ophthalmology*. 2nd ed. St Louis: Mosby, 2004: 1170.


EUROTECH OPTICAL




Huvitz HRK-7000 Auto Ref - Keratometer
The all new Huvitz HRK-7000 based on WAVEFRONT technology has opened up new possibilities for proper diagnosis of ocular error, with its own developed MICRO LENSLET ARRAY creates a number of separated focal spots, of which the pattern provides valuable information about patient ocular errors, and SLD (Super Luminescent Diode) and a highly sensitive CCD system that will offer clearer images and will secure accurate measurements from ametropia, cataract and IOL with a full aberration mapping.



Neitz Halogen Ophthalmoscope
The BX-12345 is a full diagnosis with all polarized filters and corrective lenses for eye, ear, nose and throat which comes with all accessories and spares needed from a laryngoscope to a tongue depressor.



The Kowa Nonmyd Non-Mydriatic Fundus Camera
The all-in-one highly compact lightweight 10 Mega-pixel Nikon system Fundus camera employs fully advanced ergonomic operation design making fundus photography results easy giving sharper, clearer images that will guarantee outstanding performance in all clinic scenes.



The Kowa VK-2 Kowa ophthalmic Medical Imaging System
The amazingly high-volume and highly diversified medical images are the elements the VK-2, Kowa ophthalmic Medical Imaging Technology, has chosen, to design its masterpiece of high performance digital imaging system, with a massive full back-up storage imaging system and most clinic modification on pathology research.

Tonometer - For eye Pressure also available.

Please contact Eurotech on (021) 370 4175 or 082 414 1472 e-mail: sales@eurotechoptical.com
website: www.eurotechoptical.com or for more information Fabio on 072 056 6527