

NEUROLOGICAL COMPLICATIONS OF HIV/AIDS IN CHILDHOOD

The neurological complications of human immunodeficiency virus type 1 (HIV-1)/acquired immunodeficiency disease (AIDS) contribute significantly to the morbidity of HIV infection in the paediatric age group.¹

KIRSTEN A M DONALD, MB ChB, MRCPCH (UK), FCPaed (SA), MPhil (Paed Neuro), Cert Paed Neuro (SA)
Senior Specialist and Head, Division Developmental Paediatrics, Red Cross War Memorial Children's Hospital, University of Cape Town

KATHLEEN WALKER, MB ChB
Medical Officer, Division Paediatric Neurology and Kidzpositive HIV Clinic, Red Cross War Memorial Children's Hospital and Groote Schuur Hospital, University of Cape Town

GILL RIORDAN, MB ChB, FCPaed (SA), MPhil (Paed Neuro)
Senior Specialist, Division of Paediatric Neurology, Red Cross War Memorial Children's Hospital, University of Cape Town

RAJESHREE GOVENDER, MB ChB, FCPaed (SA), MPhil (Paed Neuro), Cert Paed Neuro (SA)
Senior Specialist, Division of Paediatric Neurology, Inkosi Albert Luthuli Central Hospital, University of KwaZulu-Natal

JO WILMSHURST, MD
Paediatric Neurologist, Red Cross War Memorial Children's Hospital, Cape Town

Correspondence to: K Donald (kirsty.donald@uct.ac.za)

Neurological involvement has been reported in 50 - 60% of children with central nervous system (CNS) involvement. It is the initial manifestation in up to 18% of children. During the first year of HIV infection the incidence of clinical CNS disease is higher in children than in adults (9.98% v. 0.3%).² Thereafter, the annual incidence is similar.

Neurological involvement has been reported in 50 - 60% of children with central nervous system (CNS) involvement. It is the initial manifestation in up to 18% of children.

The neurological manifestations of AIDS may result from direct neuronal infection, the cytokine-mediated effects of the virus and immune dysregulation. The spectrum of neurological manifestations of the disease is diverse. However, most published data relate to HIV encephalopathy (HIVE), with less focus on other complications, i.e. cerebrovascular disease, epilepsy and peripheral neuropathy.¹ The advent of triple antiretroviral therapy has led to improved survival of HIV-infected children and an increasing recognition of these other complications in the paediatric population.

We present an overview of the neurological complications of HIV-1 infection in children.

Neurological complications

The neurological complications of HIV-1 can be divided into those directly related to HIV-1 brain infection (primary disorders such as HIVE) and indirect complications (such as CNS opportunistic infections (OIs) and malignancies). Children infected with HIV are also at risk of CNS disorders unrelated to the underlying infection. Other causes of neurological and developmental disorders (e.g. hypothyroidism, vitamin and co-factor deficiencies, clotting disorders) should be considered where relevant. In addition, environmental and socio-economic deprivation (e.g. orphans, poverty, malnutrition) may further impact on the manifestations of any of these complications.

Direct complications

HIVE is the hallmark of CNS involvement in children with HIV and may present with the triad of acquired microcephaly, neurodevelopmental delay and progressive motor dysfunction. Clinicians should be able to

differentiate between the child with HIVE and the uninfected child with cerebral palsy.

Presentations differ according to the age of the children and mode of HIV-1 infection. Infants and younger children manifest the most severe and global neurological dysfunction, while older children have more specific signs. Children with onset of HIVE before 1 year of age have a smaller head circumference, lower birth weight, and more severe neurological disease.³ HIVE can be clinically categorised as follows:

- Progressive – loss of acquired skills or stagnation/plateau in attaining developmental milestones. Children with subacute and plateau subtypes have a decline in standardised scores on serial neurodevelopmental screens.

OR

- Static – children acquire new skills and abilities more slowly than normal and their standardised test scores are below average, but stable.

HIVE is a clinical diagnosis. The role of investigations is largely to exclude other conditions. Brain imaging shows cerebral atrophy, often with calcification of the basal ganglia. Radiological abnormalities may be present before neurological deterioration is evident and are not specific to children with HIVE. Prevalence rates of HIVE have reduced since the early introduction of antiretroviral therapy became standard practice internationally.⁴ Children initiated on antiretroviral therapy and who have established HIVE may show clinical improvement or plateauing, although abnormal neurological signs and gross motor difficulties persist.

The neurological complications of HIV-1 can be divided into those directly related to HIV-1 brain infection (primary disorders such as HIVE) and indirect complications (such as CNS opportunistic infections (OIs) and malignancies).

The poor CNS penetration of most antiretroviral therapies has caused debate with regard to the mechanism responsible for the apparent decline in prevalence of HIVE. The nucleoside reverse transcriptase inhibitors (NRTIs), zidovudine (AZT), stavudine (d4T) and abacavir

(ABC), have relatively good penetration. The non-NRTI (NNRTI) nevirapine (NVP) has the best potential for treatment of CNS disease. With the exception of indinavir and lopinavir, protease inhibitors (PIs) have poor CNS penetration. Effective CNS-penetrating ART regimens were found to be important in affecting survival after diagnosis of HIVE.⁴

Stroke is the most common cause of focal neurological deficits in children with HIV-1. The prevalence is quoted as 2.6%. HIV infection is believed to cause stroke by predisposing to OIs (especially tuberculous and bacterial meningitis), by increasing cardio-embolic stroke due to direct cardiac involvement with HIV (more common in adults), possibly by interfering with blood coagulation through antiphospholipid antibodies or reduced protein S, or by causing an arteriopathy. Mechanisms for accelerated atherosclerotic cerebrovascular disease with dyslipidaemia occur with antiretroviral therapy.⁵ Currently, this appears to be of greater concern in the adult population and in children on d4T. The prolonged survival of many children could lead to cerebrovascular complications in adolescence. Management of stroke in HIV-infected children should include low-dose aspirin administration.

Spinal cord. A structural cord lesion must be excluded in children presenting with paraparesis. Magnetic resonance imaging (MRI) is the investigation of choice. Vacuolar myelopathy is rare in children and myelopathies may be due to OIs (herpes simplex virus (HSV), cytomegalovirus (CMV), varicella zoster virus) or tumours.

Peripheral neuropathies may develop in 5% of HIV-1-infected children. Poor nutritional

state and global wasting may mask focal wasting. Paraesthesiae and pain are the most common presenting complaints, followed by weakness or loss of motor milestones. The most recognised form is distal sensory or axonal neuropathy, which is directly related to HIV-1 infection and often compounded by antiretroviral therapy, particularly the NRTIs, didanosine (ddI) and d4T. This condition may be severe enough to warrant termination of the drug.⁶ Acetyl-L-carnitine may benefit some of these patients.

Presentations [of HIVE] differ according to the age and mode of HIV-1 infection.

Symptomatic treatment with tricyclic antidepressants has been tried, with variable success. Local experience is that anti-inflammatory ointments and gabapentin may relieve symptoms. Both agents require special motivation for use in the public sector.

Acute and subacute demyelinating neuropathy caused by HIV-1 infection is unusual in children with HIV, occurring either at the time of seroconversion or as part of an immune reconstitution syndrome.⁷

Myopathies may occur as part of an HIV myopathy, AZT- and d4T-induced mitochondrial myopathy, or secondary myopathies (due to OIs or lymphoma). Muscle weakness usually dominates, but pain and raised creatine kinase enzyme levels may also occur.⁸

Disease-specific complications

Epilepsy in children with HIV-1 infection may be related directly to HIV or acquired pathology. The aetiology of seizures among adult patients with HIV-1 include incidental association, direct effects of HIV-1, OIs, neoplasms, cerebrovascular disease, drug toxicity and metabolic derangements. The true prevalence of seizures in children with HIV-1 is not known. Based on local data it is estimated to affect 7.6% ($N=354$) of HIV-infected children (P Samia, J M Wilmshurst – unpublished data).

Fig. 1 summarises a management guideline for children with HIV infection and seizures.

Therapy for seizures is difficult because of drug-drug and drug-disease interactions. There are no large trials in children. Antiretroviral interactions with anticonvulsants are predominantly from the PI and the NNRTI groups, with limited effects from the NRTI group (<http://www.hiv-druginteractions.org/>). Phenytoin, phenobarbitone and carbamazepine increase metabolic activity of the cytochrome P-450 complex. Concurrent use with PIs may cause sub-therapeutic antiretroviral levels and treatment failure or resistance to the PI class. PIs may cause toxic levels of anticonvulsants by inhibiting the cytochrome P-450 system.⁹

HIVE is a clinical diagnosis. The role of investigations is largely to exclude other conditions.

Table I. Neurological complications of antiretroviral therapy

| Medication | CNS penetration | Mitochondrial toxicity risk | Headache | Behaviour, sleep, learning difficulties | Myopathy/myalgia | Hyperlactataemia/lactic acidosis risk | Peripheral neuropathy risk | Ataxia | Metabolic syndrome |
|---------------------|-----------------|-----------------------------|----------|---|--------------------------|---------------------------------------|----------------------------|--------|--------------------|
| Zidovudine | Good | Moderate | Early on | Insomnia, confusion, mania | Dose related | Moderate | Moderate | No | No |
| Stavudine | Good | Moderate | No | Nil | Ascending motor weakness | High | High | No | No |
| Lamivudine | Fair | Low | Yes | Insomnia | No | Low | Low | No | No |
| Didanosine | Fair | High | Yes | Anxiety, restlessness, insomnia | No | High | High | No | |
| Abacavir | Good | Low | Yes | Sleep disorders | No | Low | No | No | No |
| Nevirapine | Good | No | Yes | Fatigue | No | No | Moderate | No | No |
| Efavirenz | Fair | No | No | Insomnia, dizziness, delusions, inappropriate behaviour, 'spacy kids', confusion, acute depression, impaired concentration, somnolence, abnormal dreams, nightmares, amnesia, agitation, False +ve urinary cannabis tests | No | No | No | Yes | No |
| Protease inhibitors | Poor | No | No | Nil | No | No | No | No | Yes |

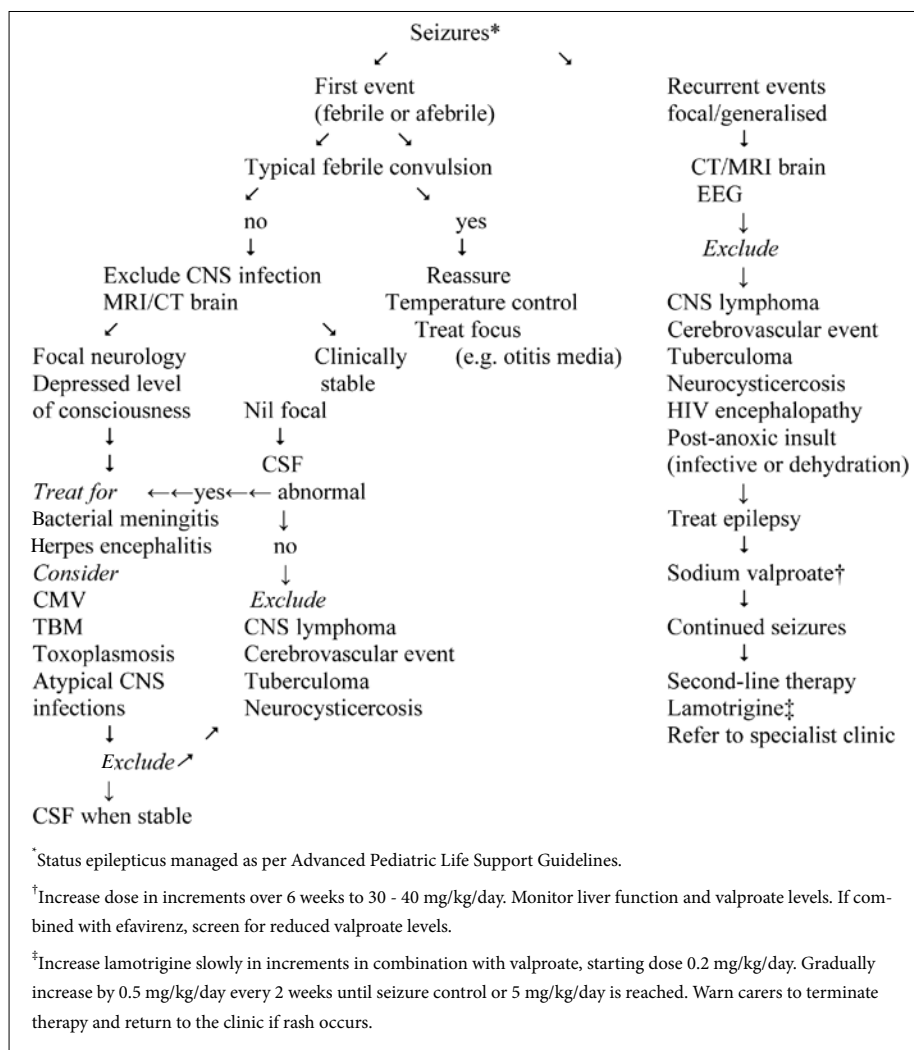


Fig. 1. Summary of approach to the child with HIV infection and seizures (based on the protocol used at Red Cross Children's Hospital, Cape Town).

Sodium valproate is the recommended first-line agent for children with HIV-1 who have seizures requiring regular prophylaxis in South Africa. Other potential anticonvulsant agents include gabapentin, topiramate, pregabalin and tiagabine, which have limited protein binding and, theoretically, no effects on the cytochrome P-450 system. Agents recommended for adults in the USA include lamotrigine and levetiracetam. There are no large studies that assess the efficacy of any of these anticonvulsants in combination with antiretrovirals in children. Lamotrigine is a useful second-line agent, but children have an increased risk of developing Stevens-Johnson syndrome. It should be used with caution and increased by increments very slowly under specialist supervision.

Opportunistic infections

Bacterial meningitis in unvaccinated children is more prevalent in HIV-infected children than in HIV-infected adults. *Streptococcus pneumoniae* and *Haemophilus influenzae* are the commonest bacteria implicated.¹⁰

Tuberculous meningitis is common in HIV-infected children from high tuberculosis

prevalence settings. Typical neuro-imaging findings in tuberculous meningitis, hydrocephalus and basal enhancement may be less marked in patients with HIV. Rifampicin is a potent inducer of the hepatic cytochrome P-450 system. It reduces the serum concentration of PIs and NNRTIs. The metabolism of efavirenz is moderately affected and it may be used with rifampicin. For children on a lopinavir/ritonavir antiretroviral regimen, administration of additional ritonavir may overcome the induction effect of rifampicin. Specific recommendations are available from the CDC: http://www.cdc.gov/tb/TB_HIV_Drugs/default.htm.

Stroke is the most common cause of focal neurological deficits in children with HIV-1.

Cryptococcal meningitis, progressive multifocal leuko-encephalopathy (PML), toxoplasma encephalitis, and possibly CMV encephalitis occur less frequently in children than in adults.

Meningitis caused by *Candida* species and *Aspergillus fumigatus* and fungal abscesses are common in some settings. In First-World settings, the commonest OI may be CMV, which can cause subacute or chronic encephalitis/ventriculitis, acute ascending radiculomyelitis, or neuropathy.¹¹

Perinatal and postnatal CMV infection was found to be higher in a study of HIV-infected infants compared with non-infected ones. A higher rate of disease progression and CNS disease occurred in the HIV-infected group, where CMV infection occurred before 18 months of age. Testing for the presence of CMV DNA in the cerebrospinal fluid (CSF) is useful in the diagnostic workup. Testing by polymerase chain reaction (PCR) may also detect the presence of other viral infections, including herpes simplex virus, varicella zoster virus and JC virus infections. Herpes simplex virus and varicella zoster virus are additional causes of acute or subacute encephalitis.¹²

Toxoplasma encephalitis is the most common cause of intracranial mass lesions in adults with AIDS, but is rare in children. Congenital toxoplasmosis is also unusual.

Subacute measles encephalitis, presenting on average 3 months after the infection, has recently been reported in a series of adults and children who are HIV infected. The outcome in these cases was almost invariably fatal.

Immune reconstitution inflammatory syndrome (IRIS)

IRIS is a common complication in children and is usually seen within the first few weeks after initiating antiretroviral therapy. A wide spectrum of organisms may precipitate IRIS, including Mycobacteria, herpes simplex virus, varicella zoster virus and *Cryptococcus neoformans*. Neurological IRIS manifests in a variety of ways, including acute inflammatory demyelinating polyradiculoneuropathy (AIDP) and, more rarely, opsoclonus-myoclonus. Management may include specific antimicrobial agents and corticosteroids.¹³

Malignancies

Primary CNS lymphoma is the most common CNS mass lesion in paediatric AIDS and the second most common cause of focal neurological signs after stroke. Tumours tend to be high-grade, multifocal B-cell tumours. Affected children present with a change in mental status or behaviour, headaches, seizures or new focal neurological signs. On imaging, lesions enhance with contrast and are associated with mass effect and oedema. The outcome is poor. Confirmation of the diagnosis may be challenging and empiric treatment for tuberculosis and toxoplasmosis are logical interventions when in doubt.¹⁴

Neuropsychiatric issues

Attention deficits are probably related to the effects of chronic illness and social disruption

as well as HIV itself. HIV-related disruption of the dopaminergic pathways may be the cause in some patients. Hyperactivity does not appear to be specifically linked with HIV. Treatment with methylphenidate is not contraindicated in children with HIV.¹⁵

Disclosure, orphan status, and the implications for future life choices have a huge impact on the psyche of the child or young adult. A local cohort of vertically infected adolescents demonstrated complex behavioural phenotypes, with retained intelligence quotients, but progressive deterioration in areas of executive functioning (R Nassen – unpublished data). It is unclear whether this finding is related to the disease itself, the socio-economic setting, or the complications of antiretrovirals (R Nassen – personal communication). In a study of youths (9 - 16 years) with vertically transmitted HIV-1, combinations of anxiety disorders (40%), attention-deficit hyperactivity disorder (ADHD) (21%), conduct disorders (13%) and oppositional-defiant disorders (11%) were observed.¹⁶ Treatment with antiretrovirals may improve neurobehavioural functioning.

HIV-related compromise is associated with cognitive functioning that is within normal limits, but there are significant declines in some aspects of psychometric performance or deficits in one or more neurobehavioural functions.¹⁶ Older children and adolescents are more likely to manifest with this complication, especially if they were commenced late on antiretrovirals.

Mitochondrial toxicity may occur from therapy with NRTIs. A high index of

suspicion is necessary as early symptoms are nonspecific. A special situation occurs in HIV-negative children born to HIV-positive mothers who received NRTIs in pregnancy. Such children may have a transitory hyperlactataemia suggesting reversible mitochondrial dysfunction. More alarming is that these children have a higher long-term risk of mitochondrial disorders, including neurological dysfunction. Regular neurological and developmental screening of HIV-exposed children is recommended.

Neurological complications of antiretroviral therapy are summarised in Table I.

Conclusion

A multidisciplinary approach is recommended for the management of HIV-infected children with CNS involvement. Children with HIV infection require symptomatic treatment of pain, movement disorders, seizures, spasticity, ADHD and psychiatric/behavioural disorders. In most cases, the same agents may be used as in the general population. Caution is needed in bone marrow suppression and liver and pancreatic toxicities. Patients with CNS involvement may be very sensitive to psychotropic medications.⁷

Children with severe neurodevelopmental deficits may benefit from physical, occupational and speech therapy. Special support is needed for children with ADHD and learning difficulties. They may have special needs that cannot be accommodated in an ordinary classroom. Many children infected with HIV-1 are born into poor socio-economic circumstances and suffer multiple health risks, which lead to a greater impact

on their neurobehavioural function.¹⁷ Society needs to acknowledge the needs of this ever-increasing population of children. Successful management of HIV-infected children in the community requires firm political and financial commitment across many sectors.

References available at www.cmej.org.za

IN A NUTSHELL

- Neurological effects (direct and indirect) are relatively common in paediatric HIV infection.
- Actively investigate and manage treatable conditions.
- Always have an index of suspicion regarding neurological side-effects from antiretrovirals (and consider drug interactions).
- Ask appropriate questions at routine visits (enquire about sleep, performance and behaviour at school and abilities to perform activities of daily living involving recent memory. Document milestones regularly).
- Measure head circumference at enrolment and at least 6 monthly.
- Note mood, general behaviour, gait and concentration as well as formal neurological examination results. Get a copy of school report.
- Efavirenz must be used with care in children who have a compromised CNS.
- Refer early for fuller assessment if concerned, and implement therapies.

SINGLE SUTURE

Take a chance to prevent cancer

For some healthy women under 55, the gamble of taking the breast cancer drug tamoxifen – which can have serious side-effects – could be worth the risk.

Although tamoxifen can raise the risk of womb cancer, heart attack and stroke, an analysis of data from four clinical trials of tamoxifen, involving 1.5 million women, concludes that there is a window in which taking the drug to prevent breast cancer should be considered, says Peter Alperin of Archimedes, a health care consultancy in San Francisco.

Women most likely to benefit are those aged 50 - 55 who are judged to have a risk of developing breast cancer within 5 years that is more than 66% higher than normal, he says.

For every 1 000 women treated Alperin claims tamoxifen could prevent 29 cases and 9 deaths, while ultimately saving money for health care providers.

'We would caution against its use except in those at high risk because one would want the benefits to substantially outweigh the harms,' says Peter Sasieni at the Wolfson Institute for Preventive Medicine in London.

New Scientist, 19 March 2011, p. 22.