

# The abnormal chest X-ray – when to refer to a specialist

**An abnormal chest X-ray must be followed up.**

OLGA MZILENI, MB ChB, MMed (Int Med)

Professor and Head of Internal Medicine and Pulmonology, University of Limpopo, MEDUNSA Campus, Pretoria

Professor Mzileni is a chief specialist and head of the Department of Internal Medicine at the University of Limpopo. She is also head of the Pulmonology Unit and ARV Clinic. She has presented research papers at congresses and published papers.

Radiological changes on a chest X-ray are an indication of pulmonary pathology or disease of one or more anatomical structures in the mediastinum. Clinical history and examination must be completed before a chest X-ray is done and read. However, it is also worth remembering that some clinical conditions will present with a normal X-ray.

## Consolidation

Consolidation or air-space shadowing is caused by opacification of air-containing spaces of the lung. The shadowing is ill defined, respects lobar boundaries and contains an air-bronchogram. Consolidation may be patchy, lobar, multilobar, or round and may

undergo necrosis due to infection or infarction. This results in liquefaction and the formation of a cavity with an air-fluid level. The causes of consolidation are listed in Table I.

- **Acute infections:** Take short history as in pneumonia, treat and then follow up.
- **Chronic infections:** Take a chronic history as in tuberculosis, investigate and treat.
- **Reasons for referral:** multilobar involvement, ongoing fever, lung abscess formation, non-resolving pneumonia, cavitating pneumonia, and all other causes of consolidation.

## Collapse

Collapse or atelectasis is due to partial or complete volume loss in a lung or lobe. Types of collapse are:

- relaxation or passive collapse
- cicatrised collapse
- adhesive collapse
- reabsorption collapse.

NB: Refer all cases of collapse for further investigation.

## Radiographic signs of lobar collapse

This depends on a number of factors, such as extent of collapse, the presence or absence of consolidation in the affected lung, and the pre-existing state of the pleura, e.g. pleural thickening, fibrosis and pleural adhesions. An air bronchogram is rare in reabsorption collapse, but present in passive and adhesive collapse. Signs of collapse may be direct or indirect. Indirect signs are due to compensation for loss of lung volume.

Table I. Causes of consolidation

Common	Rare
Infection	Allergic lung disease
Infarction	Connective tissue disease
Cardiogenic pulmonary oedema	Drug reaction
Non-cardiogenic pulmonary oedema	Haemorrhage
Adult respiratory distress syndrome	Lymphoma
Neurogenic pulmonary oedema	Radiation injury
Alveolar cell carcinoma	Amyloid
	Eosinophilic lung disease
	Sarcoidosis
	Alveolar proteinosis

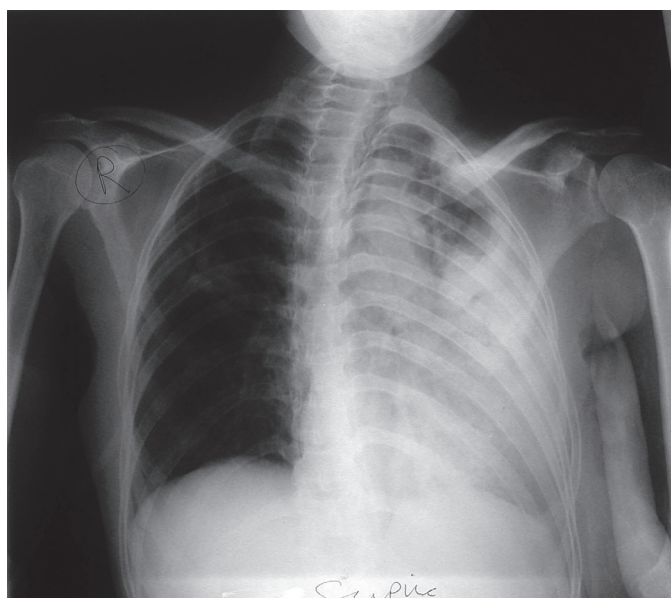


Fig. 1. Consolidation with collapse.

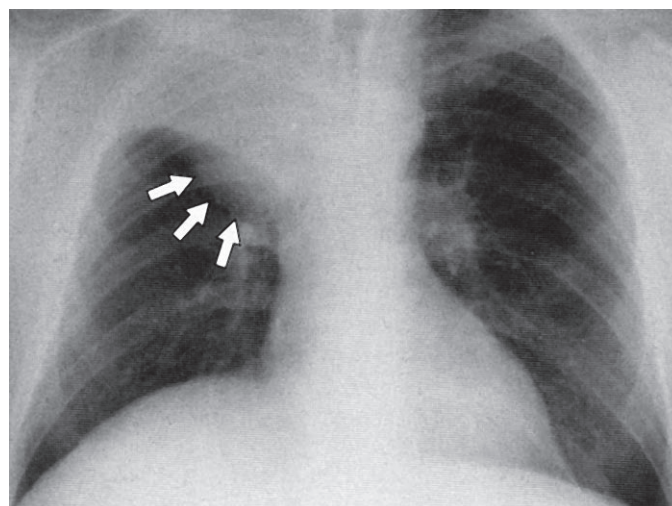


Fig. 2. Collapse of upper lobe.

## Abnormal chest X-ray

### Direct signs of collapse

Displacement of interlobar fissures, loss of aeration and vascular and bronchial crowding.

### Indirect signs of collapse

Elevation of the hemi-diaphragm, mediastinal displacement, hilar displacement, compensatory hyperinflation and crowding of the ribs.

**Right upper lobe collapse:** The lateral end of the horizontal fissure moves upwards and medially towards the superior mediastinum.

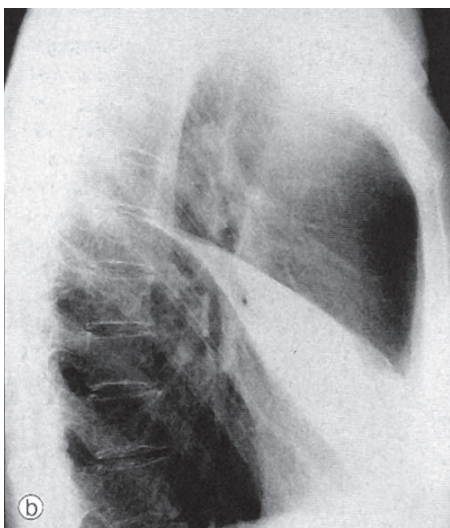
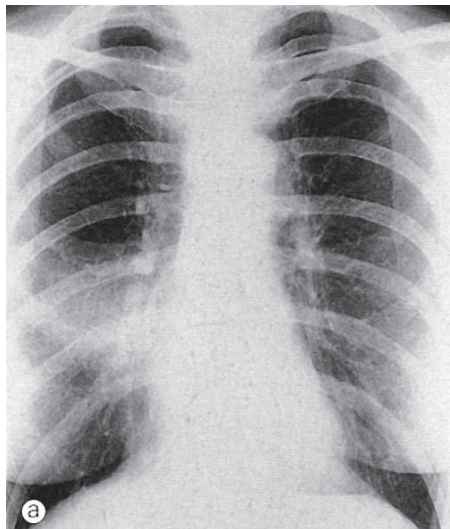


Fig. 3. Collapse – middle lobe.

**Middle lobe collapse:** The horizontal fissure and lower half of the oblique fissure move towards each other. This is best seen on a lateral view. The right heart border may be obscured on the PA view.

**Left lower lobe collapse:** The oblique fissure moves posteriorly but maintains its slope, and is displaced medially. The heart may obscure the wedge-like opacity and a penetrated view may be required to demonstrate it.

**Right lower lobe collapse:** There is depression of the horizontal fissure. In complete collapse the lobe is small, flattened

and merges with the mediastinum to produce a thin wedge-shaped shadow. There is hyperinflation of the upper lobe, the diaphragm is not elevated, and the trachea is shifted to the right.

**Left lingula collapse:** The radiographic positions of the features are similar to right middle lobe collapse. There is anterior displacement of the lower half of the oblique fissure and an increased opacity anteriorly obscuring the left heart border.

**Left upper lobe collapse:** Seen on the lateral projection there is anterior displacement of the oblique fissure such that it is parallel to the anterior chest wall.

In severe cases it may retract posteriorly or medially against the mediastinum and lose contact with the anterior chest wall. On a lateral film it appears as an elongated opacity extending from the apex of the lung to the diaphragm. The lower lobe is hyperinflated.

**Right lower and middle lobe collapse:** The right lower and middle lobes originate from the bronchus intermedius; an extensive lesion at this site causes combined collapse.

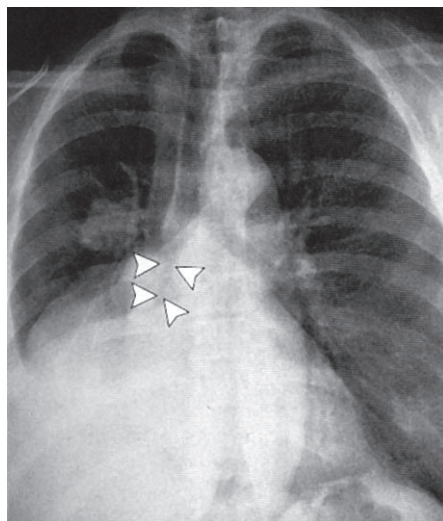


Fig. 4. Right lower and middle lobe collapse.

**Right upper and middle lobe collapse** is an unusual finding.

**Rounded atelectasis:** This may be mistaken for a pulmonary tumour. It is pleurally based with ill-defined edges and is associated with pleural thickening. Vessels may radiate from it.

## Unilateral increased translucency

### Causes

- **Chest wall:** reduction in the amount of overlying soft tissues, e.g. mastectomy.
- **Reduced vascularity:** acquired or congenital interruption or significant

reduction in the blood supply, e.g. in pulmonary embolism. Refer for further investigation.

- **Lung hyperinflation:** air trapping secondary to the presence of a foreign body or asymmetric emphysema, or compensatory emphysema. Refer for further investigation.

## Pulmonary mass lesion

Physical examination is required to determine if the mass is intrapulmonary or cutaneous.

Intrapulmonary lesions are well defined and are projected over the lung on frontal and lateral projections. Extrapulmonary mass lesions are in contact with other soft-tissue structures – check the breadth of the base of the lesion, the angle made with adjacent structures, and the presence of bone destruction.

**Size:** Increasing size suggests malignancy.

**Density:** A completely or centrally calcified nodule is diagnostic of a tuberculoma or histoplasma. Concentric rings of calcification are typical of healed histoplasmosis infection. Popcorn calcification is highly suggestive of a hamartoma. Other calcification present on a chest X-ray is not specific for benign or malignant lesions.

**Margins:** Smooth round lesions are more likely to be benign, but some primary lung malignancies and secondary deposits may be round. Malignant lesions may be lobulated and speculated.

**Vascular markings:** Arteriovenous malformations have a feeding artery or draining vein.

**Growth rate:** The growth of pulmonary nodules is measured by doubling time,

When your patients cannot hold back any longer

**R**  
**Detrunorm<sup>®</sup>**  
propiverine hydrochloride

PharmAfrica (Pty) Ltd.  
Tel: (011) 493-8970

Each tablet contains 15 mg propiverine HCl  
Reg. No.: 36/5.4/0019

## Abnormal chest X-ray

that is an increase in diameter of 25% if the tumour is spherical. Tumours with doubling time of less than 30 days or more than 2 years are unlikely to be malignant.

**Primary tumours** arising centrally from a proximal or segmental bronchus present as a hilar mass. They may grow into the bronchial lumen and around the bronchus, causing obstruction of the lumen resulting in post-obstructive consolidation or collapse.

**Peripheral tumours** usually appearing as solitary nodules or masses are large, poorly defined, speculated or lobulated. The presence of satellite opacities around the mass indicates granulomatous disease or metastases. Peripheral tumours may invade the ribs or spine directly. Five per cent of bronchial carcinomas cavitate due to central necrosis or abscess formation; the cavity is thick walled with an irregular inner margin.

Sputum cytology may be attempted, but all lung mass lesions require referral for further investigation.

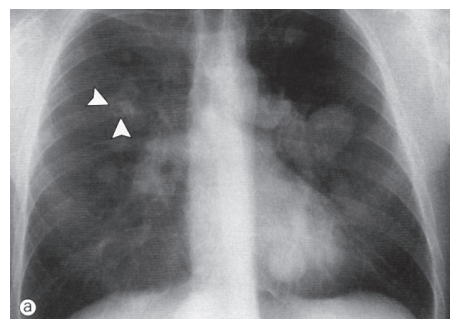


Fig. 5. Multiple pulmonary nodules.

**Multiple pulmonary nodules** are described in terms of size, number, distribution, density, definition, cavitation, speed of growth (if serial films are available), and

accompanying pleural, mediastinal, or skeletal abnormalities. Check for infection, systemic illness, and prior malignancy. All patients with multiple pulmonary nodules must be referred. Causes of pulmonary nodules are listed in Table II.

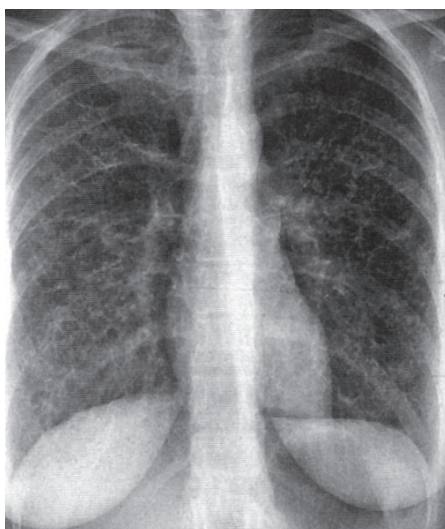


Fig. 6. Reticular shadowing.

### Diffuse shadowing

The summation of multiple, small, linear opacities on the chest X-ray may produce the appearance of multiple small nodules. Likewise the superimposition of multiple small nodules may produce a granular or ground-glass pattern. The pattern must be described as nodular or reticular. All the causes of consolidation should be considered when evaluating a chest X-ray with a reticular, nodular or reticulo-nodular pattern.

**Reticular or linear shadowing** is made up of multiple, short, irregular linear densities, randomly orientated and overlapping to

produce a net-like pattern. When the linear shadows are oriented at right angles to the pleural surface they are called Kerley's B lines.

**Nodular opacities** may be well or poorly defined and of varying density or calcified. The nodules may be discrete or coalescent with areas of confluence producing consolidation.

**Reticulo-nodular shadowing** is the most common form of diffuse lung shadowing.

**Ground-glass shadowing** is a generalised increase in density, which may be diffuse or patchy, unilateral or bilateral, and may be in the mid and/or lower zones. The vascular branching pattern is not totally obscured. The diaphragm and hilar appear less sharp. Check the distribution – upper, mid or lower zone and whether the lung architecture is distorted. Check for signs of cardiac failure or fluid overload, e.g. heart size, vein size in upper and lower lobe, signs of a pleural effusion, and the presence of hilar or mediastinal enlargement. Check the bones and soft tissue of the chest wall, e.g. in previous mastectomy or erosive bony lesions. Check if the patient is immunocompromised or not.

If the diagnosis is not clear as in fluid overload/congestive cardiac failure (pulmonary oedema), or *Pneumocystis carinii* pneumonia, refer for further investigation.

### Airway diseases

**Tracheal narrowing** may be due to:

- extrinsic mass
- an intrinsic abnormality of the tracheal wall
- fibrosing mediastinitis
- sarcoidosis
- chronic relapsing polychondritis
- Wegener's granulomatosis.

Primary tumours of the trachea are rare. Benign tumours are small, well defined and intraluminal. Malignant tumours tend to occur close to the carina.

**Tracheal widening** is rare and can occur as part of connective tissue disorders. The usual diameter of the trachea is 23 mm in males and 20 mm in females.

**Bronchiectasis** may present with a normal chest X-ray or:

- the presence of thickened bronchial walls seen as parallel, linear opacities radiating from the hilum with lack of convergence more peripherally
- dilated airways seen end on – they appear as thick- or thin-walled ring shadows

Table II. Causes of pulmonary nodules

Neoplastic	Inflammatory
Benign	Infectious
Hamartoma	Granulomatous infections
Papillomatosis	Multiple embolic abscesses
Bronchogenic cysts	Round pneumonia
Malignant	Viral infections – chicken pox and measles
Metastases	Parasites – hydatid and paragonimiasis
Lymphoma	Non-infectious
Multifocal tumour	Caplan's syndrome and rheumatoid arthritis
Kaposi's sarcoma	Wegener's granulomatosis
Bronchoalveolar cell carcinoma	Sarcoidosis
	Others
	Progressive massive fibrosis
	Amyloid
	Infarcts
	Bronchial impaction

## Abnormal chest X-ray

- the presence of secretions may produce multiple small air-fluid levels or form plugs showing tubular, soft-tissue density opacities radiating from the hilum most commonly in the lower lobes.

Localised bronchiectasis or disabling bronchiectasis requires specialist opinion and treatment. Otherwise bronchiectasis needs physiotherapy and treatment with antibiotics when there is infection.

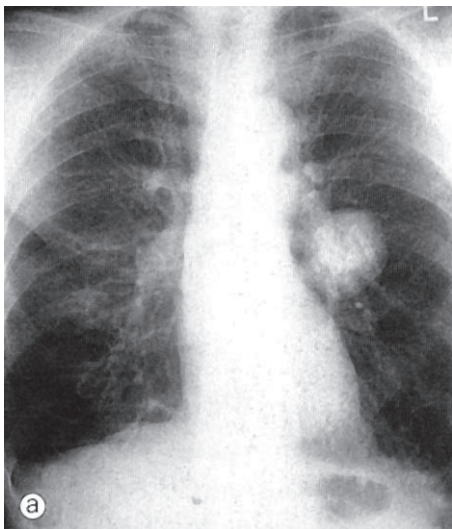


Fig. 7. Hilar enlargement.

## Mediastinal abnormalities

**Hilar abnormalities** may be vascular and non-vascular. Vascular shadows are symmetrical, large, and of normal density. Pulmonary artery branches may be traced to their point of convergence with interlobar arteries, known as the 'hilar convergence' sign. Enlarged lymph nodes and hilar tumours are lobulated with clear lateral and inferior borders. A pulmonary lesion may be superimposed on the hilum on a PA view producing a large or dense hilum. This may be best seen on a lateral X-ray. The vessel to the middle lobe or lingula is superimposed on the lower part of the hilar shadow.

**Unilateral non-vascular hilar enlargement** may be due to a bronchogenic cyst or tumour, tuberculous lymphadenopathy, fungal disease or lymphoma and rarely sarcoidosis.

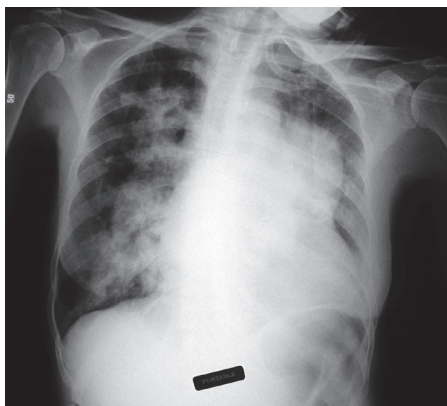


Fig. 8. Unilateral hilar enlargement.

**Unilateral vascular hilar enlargement** may be due to pulmonary embolism, pulmonary artery aneurysm, and post-stenotic dilatation of the pulmonary artery.

**Bilateral non-vascular hilar enlargement** may be due to sarcoidosis, lymphoma, leukaemia, some fungal infections, and certain pneumoconioses.

**Bilateral vascular hilar enlargement** may be due to dilatation of a pulmonary artery in pulmonary embolism or pulmonary hypertension.

All mediastinal abnormalities need referral.

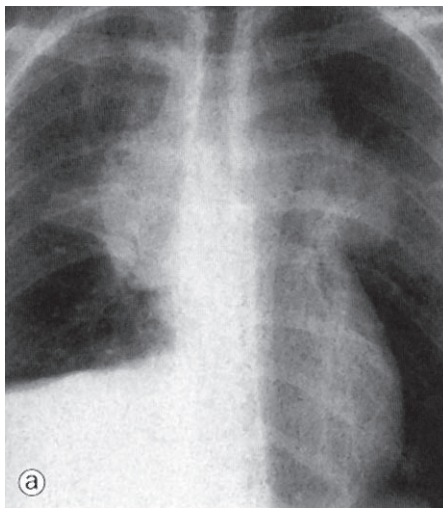


Fig. 9. Bilateral hilar enlargement.

**Abnormalities of the thoracic aorta:** Dilatation or tortuosity of the aortic arch or its branches causes widening of mediastinum, e.g. unfolding of the aorta or aneurysm of the aorta.

**Dilatation of the central veins:** The superior vena cava and azygos vein may dilate due to increased pressure, increased flow, obstruction or congenital abnormalities. Refer to exclude causes of abnormal dilatation.

## Pleural disease

**Pleural effusions** collect in the posterior costophrenic angle and as little as 100 - 200 ml may appear above the diaphragm. Such small collections are best seen on a lateral or decubitus view. With increasing fluid a meniscus appears, followed by increasing opacification of the hemithorax and passive atelectasis of the underlying lung as well as shift of the mediastinum to the opposite side, especially if the underlying lung is diseased and does not collapse.

**Lamellar effusions** are collections of fluid between the lung and the visceral pleura sometimes sparing the costophrenic angle.

**Sub-pulmonary effusions** accumulate between the diaphragm and the under-surface of the lung, mimicking elevation

of the hemidiaphragm. Blunting of the costophrenic angle or tracking of fluid into fissures may occur. On the left the distance between the gastric air bubble and the lung base may appear increased. This may be confirmed by ultrasound and/or a decubitus film.

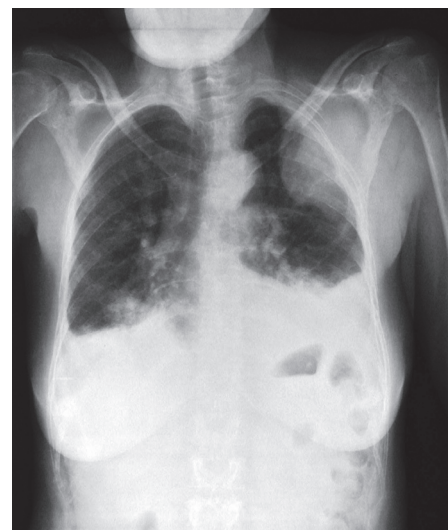

Fig. 10. Pleural effusion.

**Encapsulated or encysted effusions** must be differentiated from an extrapleural opacity, parenchymal lung disease or a mediastinal mass.

**Fluid loculated in the interlobar fissures** is seen in heart failure. Fluid in the horizontal fissure produces a lenticular, oval or round shadow with well-demarcated edges. Fluid in the oblique fissure shows a lenticular pattern on a lateral film. These fluid collections resolve spontaneously and are therefore known as 'pseudotumours'. Empyemas may present with an air-fluid level in the pleural space. The collection may be loculated or may communicate with the tracheobronchial tree.

**Pneumothorax:** The lung retracts towards the hilum and on the PA view the sharp line of the visceral pleura is separated from the chest wall by a radiolucent pleural space with no lung markings. A massive pneumothorax (tension pneumothorax) displaces the mediastinum to the opposite side. This is a medical emergency that should be diagnosed and treated immediately.

**Pleural thickening** may follow pleurisy. If unilateral it may be due to infection or infarction and may obliterate the costophrenic angle, mimicking an effusion. Apical pleural thickening is seen in patients who have had tuberculosis and may sometimes be seen in the elderly without an apparent cause. Extensive unilateral pleural thickening may be due to a previous thoracotomy, an exudative pleural effusion, empyema or a haemothorax.

**Pleural calcification,** if unilateral, may be due to a previous empyema or a

haemothorax; if bilateral it may be due to asbestos exposure.

**Pleural masses** may be benign, e.g. pleural fibroma and lipoma, or malignant, e.g. metastatic tumours or mesothelioma. All patients with pleural masses should be referred.

### Conclusion

This paper provides a broad overview of a range of chest X-ray abnormalities that require referral upon presentation, e.g. lobar collapse, pulmonary mass lesion, diffuse parenchymal shadowing, a mediastinal mass lesion and pleural disease. In addition, all patients who do not respond well to what is thought to be appropriate treatment also require referral, e.g. non-resolving consolidation of the lung.

#### Further reading

1. Albert R, Spiro S, Jet J. *Comprehensive Respiratory Medicine*. London: Mosby, 1999: 1.16.
2. Burton GG, Hodgkin JE, Ward JJ. *Respiratory Care: A Guide to Clinical Practice*. 4th ed. Philadelphia: Lippincott, 1997: 195.

### In a nutshell

- Chest X-rays are an important investigation in lung disease. However, history and physical examination are crucial steps in the evaluation of the patient and should be performed before reading chest X-rays.
- X-ray abnormalities need to be combined with clinical findings to make a diagnosis.
- If you are not sure, seek assistance from a specialist.
- Consolidation or air-space shadowing is caused by opacification of air-containing spaces of the lung.
- Collapse or atelectasis is due to partial or complete volume loss in a lung or lobe.
- Physical examination is required to determine if the mass is intrapulmonary or cutaneous.
- Intrapulmonary lesions are well defined and are projected over the lung on frontal and lateral projections. Extrapulmonary mass lesions are in contact with other soft-tissue structures.
- The summation of multiple, small, linear opacities on the chest X-ray may produce the appearance of multiple small nodules. Likewise the superimposition of multiple small nodules may produce a granular or ground-glass pattern.
- Hilar abnormalities may be vascular and non-vascular.
- Pleural effusions collect in the posterior costophrenic angle and as little as 100 - 200 ml may appear above the diaphragm.


### Single suture

## Grumpy old men

Depression in men generally manifests itself as irritability and aggression, along with increasing isolation, while women become more clingy and needy, according to a snippet in a recent *British Medical Journal*. Depressed men may show more unexplained physical symptoms than women and undiagnosed depression can destroy relationships with what one writer calls 'irritable male syndrome'. Worth bearing in mind in patients who appear to be having a mid-life crisis or in elderly men who seem to be alienating themselves from their families.

Minerva. *BMJ* 2007; 335: 570.

When your patients  
cannot hold back any longer



**R**  
**Detrunorm<sup>®</sup>**  
propiverine hydrochloride

Detrunorm Tablets. Each tablet contains 15 mg propiverine HCl. Reg. No.: 36/5.4/0019

Pharmafrica (Pty) Ltd.  
Tel: (011) 493-8970

