

## Oral medicine

**Paul Botha, BChD, PDD, MChD (OMP)**

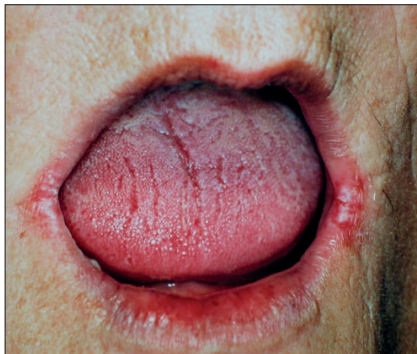*Periodontist, Private Practice, Bellville, Cape Town*

Correspondence to: P Botha (p.mbotha@mweb.co.za)

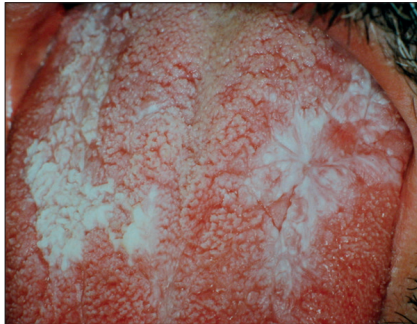
### Clinical setting

The causes of oral signs and symptoms could include medicine side-effects, trauma, autoimmune disease, nutritional deficiency, fungal infection (Fig. 1), premalignant disease (Fig. 2), oral carcinoma (Fig. 3), or sequelae of cancer treatment. What is the approach to the management of such patients?

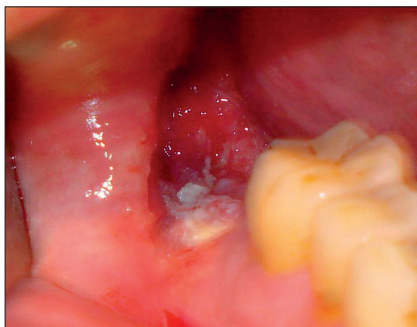Our general practitioners are minimally exposed to pathology of the oral cavity during their basic medical training. As a result, one can't expect them to be consistently effective in dealing with oral complaints. This might even extend to not being able to differentiate between healthy and diseased oral mucosa. Consequently, one often sees a prescription for a broad-spectrum topical or systemic antibiotic or a topical antifungal agent, anticipating that this approach will deal with the presenting signs and/or symptoms.



*Fig. 1. Angular cheilitis. 'Common things occur commonly' and in the elderly population this is mostly as a result of an intra-oral Candida infection associated with the wearing of a denture.*



*Fig. 2. Leukoplakia of the tongue associated with smoking.*



*Fig. 3. An oral squamous cell carcinoma of the mandibular ridge behind the most posterior molar.*

Dentists are equipped with skills and training to diagnose (including performing biopsies) and treat many basic oral mucosal lesions, and have been shown to successfully clinically diagnose 88.7% of oral lesions compared with 28% by medical doctors.<sup>1</sup> Furthermore, the emphasis of oral medicine training is very much on the early detection of pre-malignant lesions (white, red and combined white/red lesions) and

subsequent referral for further appropriate evaluation and management. Dentists and dental hygienists, with their specific training and consequent high index of suspicion, form a solid foundation in contributing to the awareness and early detection of oral squamous cell carcinoma.

An increased awareness of the discipline of oral medicine and the optimal interaction between medical and dental practitioners relating to this specialty would augur well to improve on the already high standards of medical and dental care in South Africa. This could easily be achieved by identifying a dentist and/or periodontist who can be part of the referral network within the medical practice. Further continuing medical education involving clinical lectures/workshops relating to the examination and diagnosis of common oral problems would also be of value. This is especially important in the early detection of oral cancer. As patients with oral lesions often present to their family doctor<sup>2</sup> the role of the general practitioner is important. It has been shown that both medical and dental practitioners adopt an urgent approach to possible oral cancerous lesions, with 69% referring within 1 week of initial consultation.<sup>3</sup>

Improving the evaluation of the oral cavity:

- Try to become familiar with the healthy appearance of oral mucosa.
- A well-lit visual field - an old overhead dental light mounted on a wall will be perfect. This could also be used for other evaluations.
- Adopt a systematic approach to examination of the oral cavity. Also focus attention on the posterior part of the dorso-lateral surface of the tongue, which is nicknamed 'coffins corner', as a cancerous lesion may develop here surreptitiously for years without being noticed.
- Any white lesion should be firmly rubbed with a gauze to ensure that it is leukoplakia, which will not rub off under such pressure. Compare this with the white plaques sometimes associated with a Candida infection, which will easily rub off.

References available at [www.cmej.org.za](http://www.cmej.org.za)

## More about...

### References

1. Carter L, Ogden G. Oral cancer awareness of general medical and general dental practitioners. *Br Dent J* 2007;203:E10. Published online: 13 July 2007.
2. McCann P, Sweeney M, Gibson J, Bagg J. Training in oral disease, diagnosis and treatment for medical students and doctors in the United Kingdom. *Br J Oral Maxillofac Surg* 2005;43(1):61-64.
3. Hollows P, McAndrew PG, Perini MG. Delays in the referral and treatment of oral squamous cell carcinoma. *Br Dent J* 2000;188:262-265. Published online: 11 March 2000.