

HIV and the eye

In an area of high HIV prevalence, HIV-related ocular lesions are relatively common.

L Visser, MB ChB, MMed (Ophth), FCS (Ophth) SA

Head, Department of Ophthalmology, University of KwaZulu-Natal, Durban, South Africa

Correspondence to: L Visser (visser@ukzn.ac.za)

It is estimated that there are 5.6 million people in South Africa living with the human immunodeficiency virus (HIV) infection and acquired immune deficiency syndrome (AIDS).^[1] A relatively small percentage of them are on highly active antiretroviral therapy (HAART) although numbers are steadily increasing. As their CD4 cell counts decrease, these people will become more likely to develop certain opportunistic infections, immune-related diseases and tumours. A large number (70 - 75%) of them will develop ocular disease sometime during the course of their illness and it may be the first sign of HIV infection.

Ophthalmic manifestations are usually due to underlying microvasculopathy, opportunistic infections, neoplasms or autoimmune/hyperallergic reactions. For ease of discussion these will be classified according to clinical presentation into external eye (orbital and adnexal) disease, anterior segment, posterior segment and neuro-ophthalmic manifestations. Only the entities that are more commonly seen will be discussed.

External eye (orbital and adnexal) manifestations

External eye manifestations are quite common and range from the innocuous trichomegaly (long eye lashes) to proptosis caused by orbital cellulitis or lymphoma (life-threatening if not managed appropriately).

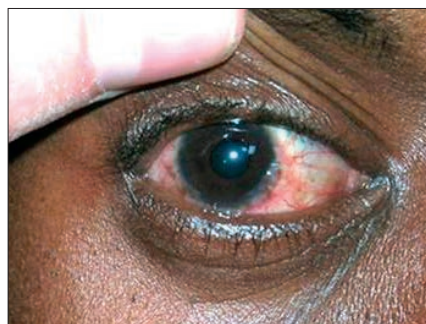

Fig. 1. Conjunctival injection and limbal lymphoid hyperplasia seen in a patient complaining of severe itchiness of both eyes.

Allergic conjunctivitis

When a patient with no previous history of ocular allergies presents with new-onset allergic conjunctivitis after the age of 18 years, underlying HIV disease should be excluded, especially if this patient falls within the high-risk groups for HIV. The appearance is similar to vernal conjunctivitis (Fig. 1) and patients usually respond to treatment with weak steroid drops (such as fluoromethalone).

Keratoconjunctivitis sicca (dry eyes)

Dry eyes can be due to the auto-immune destruction of lacrimal gland tissue, or secondary to lid infections or Stevens-Johnson syndrome. Artificial tear supplementation is often necessary.

Blepharitis

Recurrent lid infections are common and often associated with dry eyes and recurrent Meibomian cysts or styes. Lid hygiene is important and topical antibiotic ointment is often indicated.

Trichomegaly/hypertrichosis

Exaggerated eyelash growth is sometimes seen quite late in the course of the disease. The exact cause is not known but an autoimmune response is suspected.

Molluscum contagiosum

Molluscum contagiosum virus infection presents as small, elevated, umbilicated lesions of the eyelid. These are often multiple and bilateral in AIDS patients. It is a DNA virus of the pox virus family. Treatment could include:

- surgical excision
- curettage
- cryotherapy
- liquid nitrogen
- topical phenol or trichloroacetic acid.

Immune reconstitution with HAART will also result in resolution of the lesions, but this may take up to 6 months.^[2]

Kaposi's sarcoma of the lid or conjunctiva

Almost 30% of AIDS patients develop Kaposi's sarcoma (KS). Oculocutaneous

KS may precede, follow or develop concurrently with the visceral form and may involve the eyelid skin, conjunctiva, plica semilunaris, caruncle, lacrimal sac and rarely the lacrimal gland and orbit. They are more malignant when associated with HIV and can disseminate. They present as red/purple subepidermal/subepithelial nodules, which can be flat to elevated (Fig. 2).

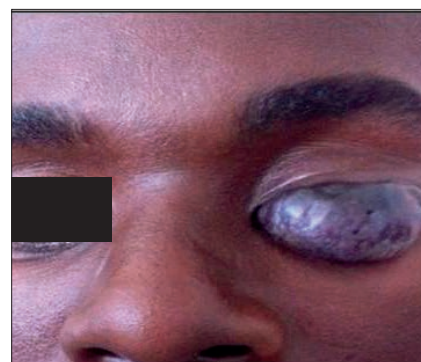

Fig. 2. Kaposi's sarcoma of the left upper lid (photo courtesy of Dr E Siolo).

Indications for treatment of ocular disease include loss of eyelid function, cosmesis and discomfort. The type of treatment depends on the size and location of the tumour and includes:

- local treatment:
 - radiotherapy
 - cryotherapy or laser therapy
 - surgical excision
 - intralesional chemotherapy (vinblastin) and subconjunctival interferon- α -2a
- systemic treatment (usually for non-ocular disease):
 - combination chemotherapy (adriamycin, vinblastine, bleomycin, dactinomycin, vincristine, dacarbazine)
 - immunotherapy (interferon-alpha).^[2]

Proptosis (orbital cellulitis or lymphoma)

This is fortunately rare and usually a result of infection, inflammation or neoplasms arising from the paranasal sinuses and spreading to the orbit, but on occasion the orbital tissues may be primarily involved in lymphoma.

Anterior segment manifestations

Anterior segment manifestations are also common and include potentially blinding and life-threatening conditions outlined below.

Stevens-Johnson syndrome

Stevens-Johnson syndrome is a complex immunological syndrome characterised by acute blistering of the skin and at least 2 mucous membranes (conjunctival involvement resulting in acute membranous conjunctivitis). It is caused by an idiosyncratic reaction to infections (HIV, herpes simplex, *Streptococcus* species) or drugs (antiretrovirals (ARVs) or sulfonamides) and can lead to severely dry eyes, conjunctival vascularisation and keratinisation. If not managed appropriately it can result in bilateral blindness.

Uveitis associated with arthritis in children

Arthritis-associated uveitis is an entity seen in HIV-positive children.^[9] They have a clinical picture similar to juvenile idiopathic arthritis (JIA), but the arthritis is polyarticular rather than pauciarticular, there is no female preponderance and all patients are antinuclear antibody (ANA) negative (Figs 3 and 4).

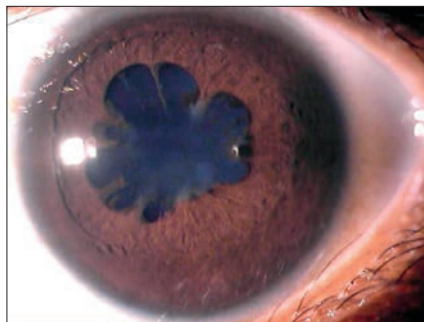


Fig. 3. Clover-leaf pupil seen in a child with uveitis and posterior synechiae.

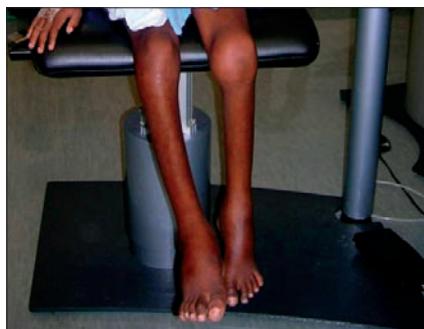

Fig. 4. Swollen knees and ankles (due to arthritis) seen in the child whose right eye is shown in Fig. 3.

Anterior uveitis in adults

Adults can present with an anterior uveitis caused by HIV itself or secondary to other viral infections (herpes or cytomegalovirus (CMV)) or bacterial infections (syphilis or tuberculosis). The signs and symptoms are:

- pain and redness
- decrease in vision
- mild inflammation
- anterior chamber activity.

Treatment is with steroid eye drops together with treatment of the underlying infection with the appropriate antiviral or antibiotic drug.

Herpes zoster ophthalmicus (HZO)

Patients under the age of 40 years who present with HZO (ocular shingles) must be investigated for HIV. They have a worse clinical course than HIV-negative patients with the same condition. The infection can occur early or late in the course of the HIV disease and ocular involvement may be severe.

Patients present with a painful, vesicular dermatitis localised to the dermatome supplied by the trigeminal nerve (usually VI or the ophthalmic division). The vesicles become pustules in 3 - 4 days, then dry and crust in 10 - 12 days. It involves deep layers of the skin and may resolve with scarring and pigmentation. Neuralgia in the dermatome can continue for months or years.

Ocular involvement is common (>70%). A vesicle on the tip of the nose (Hutchinson's sign) is a sign of globe involvement. This can manifest as conjunctivitis, keratitis (either dendritic or neurotrophic), episcleritis, scleritis or uveitis. Secondary

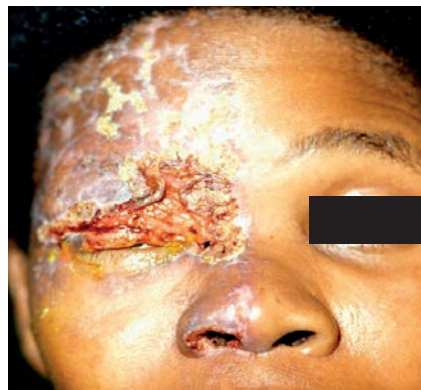

Fig. 5. Cicatricial changes secondary to HZO (note the scar on the tip of the nose - Hutchinson's sign).

bacterial infection often occurs which compounds the scarring and leads to cicatricial entropion or ectropion. Chronic inflammation may lead to corneal vascularisation, corneal opacification, lipid keratopathy, thinning and even perforation of the cornea (Fig. 5).

Treatment is with systemic antivirals within 72 hours of the rash developing:

- acyclovir 800 mg 5 x/day or
- valaciclovir 1 g 3 x/day
- analgesics for acute pain
- non-steroidal anti-inflammatory/topical lidocaine cream
- amitriptyline at night for neuralgia.^[2]

Herpes simplex keratoconjunctivitis

Herpes simplex virus (HSV) is one of the leading causes of chronic infectious ocular disease in immunocompetent patients. Keratoconjunctivitis, keratitis (dendritic ulcers) or keratouveitis can occur. In HIV disease the presentation and course are similar, but there may be more frequent recurrences of the ulcers and dendrites are often located more peripherally on the cornea. Patients may need systemic and topical acyclovir treatment due to a relative resistance to treatment.^[2]

Keratitis

In HIV-positive patients, corneal infections can occur in otherwise healthy corneas

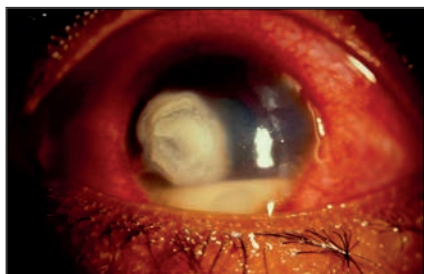


Fig. 6. Bacterial corneal ulcer with hypopyon.

(compared with immune-competent patients, where there is almost invariably an underlying corneal problem). Corneal infections are caused by bacteria or fungi (the latter generally after injury with vegetable matter). In the immune-suppressed patient the ulcers tend to be larger and more aggressive and often respond slowly to treatment (Fig. 6).

Treatment is with appropriate antibiotic or antifungal eye drops following a corneal scrape for microscopy, culture and sensitivity.

Ocular surface squamous neoplasia (OSSN)

As many as 70 - 80% of patients under the age of 50 years with OSSN are HIV positive.^[2] Clinically it presents as an elevated, well-demarcated grey to red mass, usually in the interpalpebral area. It often straddles the nasal or temporal limbus and may have prominent feeder vessels and surface keratin. It is more aggressive in HIV-positive patients (Fig. 7).

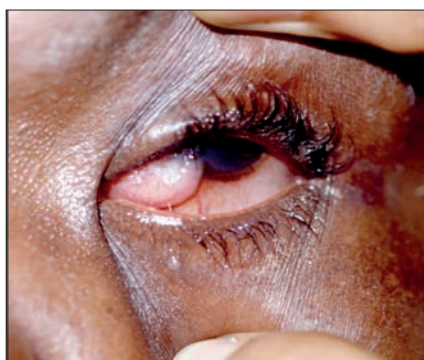

Fig. 7. Large OSSN nasally.

Treatment includes:

- surgery:
 - complete local excision with or without lamellar dissection into sclera or corneal stroma
 - enucleation of the globe or exenteration of the orbit in neglected cases with tumour invading the eye or orbit

- adjuvant cryotherapy or chemotherapy at the time of surgery
- radiotherapy
- topical chemotherapy (mitomycin-C, 5-fluorouracil or interferon α -2a).^[2]

Nerve fibre layer infarcts or 'cotton-wool spots' are part of HIV microangiopathy.

Posterior segment manifestations

Posterior segment manifestations are often bilateral and can lead to bilateral blindness if not diagnosed timeously. They include retinal, choroidal or chorioretinal infections as well as HIV microangiopathy, an indicator of advanced HIV disease.

Cytomegalovirus retinitis (CMVR)

CMVR is the most common cause for loss of vision in patients with AIDS. It is typically seen in advanced stages of AIDS when the CD4 count is less than 50 cells/mm³. Approximately 25% of patients not on HAART who have a CD4 count below 100 cells/mm³ will develop CMVR within 1 year. The clinical appearance can vary but usually consists of:

- full-thickness retinal opacification with or without haemorrhage (Fig. 8)
- minimal overlying vitritis except where large areas of retina are involved or where there is partial immune recovery from HAART
- retinal vasculitis/periphlebitis.

Loss of vision occurs as a result of involvement of the optic nerve or macula,

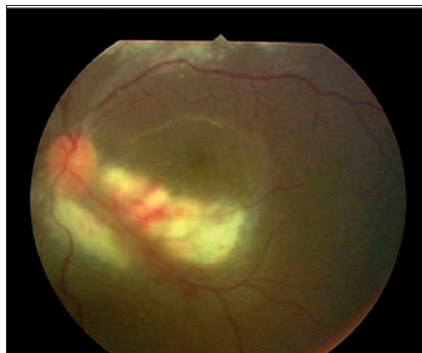


Fig. 8. Full-thickness retinal necrosis with some haemorrhage along the arcades in CMVR.

retinal detachment or immune recovery uveitis with cystoid macular oedema (CME), vitreous opacity or epiretinal membrane (seen only in patients on HAART).

Readily available treatment includes oral, intravenous or intravitreal ganciclovir. Because of its cost-effectiveness, intravitreal ganciclovir is the preferred method of treatment in the public sector.^[4,5]

Progressive outer retinal necrosis (PORN)

PORN is caused by infection with herpes simplex virus (HSV) or varicella zoster virus (VZV). Patients often have a history of cutaneous zoster infection, recent chicken pox infection or HSV ulcer on the lip or eye. There is rapid progression of retinal necrosis in a circumferential fashion with relative sparing of retinal vasculature early in the course (Figs 9 and 10). The outcome is often poor, with 67% of the patients becoming blind within 1 month – mainly due to rhegmatogenous retinal detachment. Treatment is with intravitreal ganciclovir injections and oral acyclovir, but once retinal detachment occurs, surgery is needed.^[6]

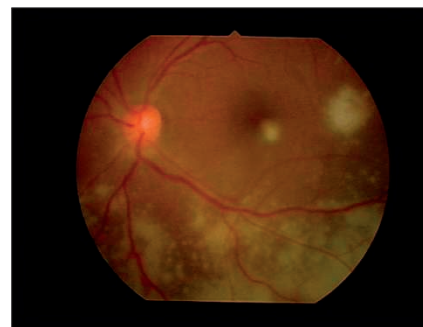

Fig. 9. Early PORN with lesions starting to coalesce but the vessels spared.

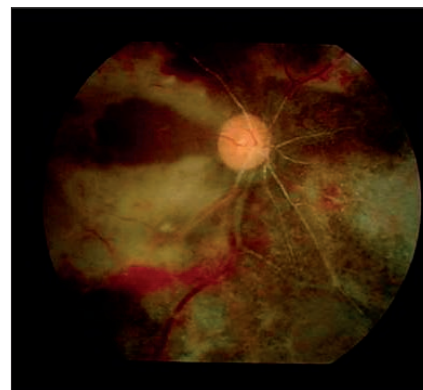


Fig. 10. Late PORN with atrophy of the retina and vascular involvement.

Toxoplasmosis chorioretinitis

Infection with *Toxoplasma gondii* results in intense, white, focal areas of retinal necrosis. These can be solitary, multifocal or in a miliary pattern. The lesions are usually larger than in immunocompetent individuals and there may be no pre-existing retinal scar. There is always substantial inflammation in the vitreous and invariably the patient will have concomitant central nervous system (CNS) involvement.

Treatment is with megadose co-trimoxazole or the combination of pyrimethamine (50 - 100 mg loading, then 25 - 50 mg daily orally) plus folinic acid (5 mg 3 times a week orally) and either:

- sulfadiazine 1 g *qid*
- clindamycin 300 - 450 mg *qid*
- azithromycin 250 mg daily or
- atovaquone 750 mg *tid*.

Prednisone (high dose, short course) must be given if the vision is threatened.^{17]}

Tuberculous choroiditis/choroidal granulomas

Tuberculosis is a common infection seen in HIV patients. Tuberculous uveitis is seen occasionally but, surprisingly, tuberculous choroiditis/TB choroidal granulomas are not seen as often as expected. The reason for this is not known. In most cases where choroidal lesions are seen, the patient is quite ill. Lesions are usually centrally located, either associated with the major vascular arcades or the macula (Fig. 11).

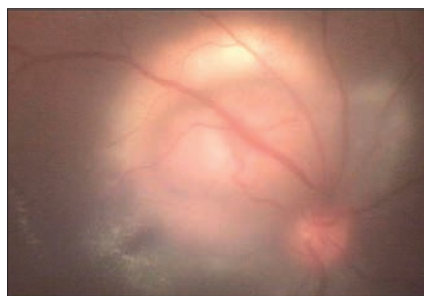


Fig. 11. Choroidal granuloma under the superotemporal arcade with macular oedema.

Syphilitic chorioretinitis

Syphilitic chorioretinitis presents as a vitritis associated with bilateral, large, solitary, placoid, pale yellow subretinal lesions with central fading and stippled retinal pigment epithelial (RPE) hyperpigmentation. When this diagnosis is made, the patient needs to be given the full neurosyphilis course of penicillin.

HIV microangiopathy

Nerve fibre layer infarcts or 'cotton-wool spots' are part of HIV microangiopathy. The CD4 count is usually below 50 cells/mm³ when these occur. They can be seen at the posterior pole or around the optic disc and may be associated with a small intraretinal haemorrhage similar to a small focus of CMVR, which may make them difficult to distinguish from early CMVR (Fig. 12). They spontaneously resolve over several months. A repeat examination must be done every 2 weeks to distinguish them from CMVR.

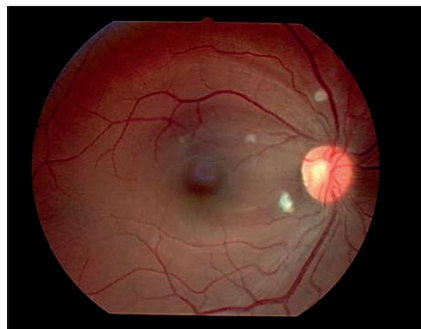


Fig. 12. Cotton-wool spots around the optic disc.

Neuro-ophthalmic manifestations

Optic neuritis

In immunocompromised patients, optic neuritis can be due to the HIV disease *per se* or associated with neurosyphilis, tuberculous meningitis, cryptococcal meningitis, toxoplasmosis or viral (CMV or HSV) encephalitis. Unilateral or bilateral occurrence is possible. Severe decrease in vision is typical. As vision can be lost permanently, systemic steroids are indicated in severe cases (high dose, short course). A lumbar puncture is needed to aid with diagnosis.

Cranial nerve palsies

Cranial nerve palsies usually occur due to central nervous system (CNS) lymphoma or CNS infections, e.g. neurosyphilis, but can also be secondary to microvasculopathy or HIV infection *per se*. Often multiple cranial nerves are involved simultaneously. Investigation in the form of neuro-imaging with or without lumbar puncture is essential to make the diagnosis.

Papilloedema

Patients can present with papilloedema as a result of raised intracranial pressure secondary to:

- cryptococcal meningitis
- TB meningitis
- CNS toxoplasmosis
- neurosyphilis
- CNS lymphoma or other intracranial tumours.

Vision may still be retained unless papilloedema is chronic. Neuro-imaging is essential and neurosurgical intervention may be needed.

References

1. UN AIDS info database: <http://www.unaids.org/en/regionscountries/countries/southafrica/> (accessed 4 February 2013).
2. Jeng BH, Holland GN, Lowder CY, et al. Anterior segment and external ocular disorders associated with human immunodeficiency virus disease. *Surv Ophthalmol* 2007;52(4):329-354. [<http://dx.doi.org/10.1016/j.survophthal.2007.04.010>]
3. Zaborowski AG, Parbhoo D, Chinniah K, et al. Uveitis in children with HIV-associated arthritis. *J AAPOS* 2008;12(6):537-538. [<http://dx.doi.org/10.1016/j.jaapos.2008.04.011>]
4. Morlet N, Young S, Naidoo D, et al. High dose intravitreal ganciclovir injection provides a prolonged therapeutic intraocular concentration. *Br J Ophthalmol* 1996;80:214-216.
5. Laher F, Ashford G, Cescon A, et al. Held to ransom - CMV treatment in South Africa. *SAJHIVMed* 2010;11(1):31-34.
6. Gore DM, Gore SK, Visser L. Progressive outer retinal necrosis - outcomes in the intravitreal era. *Arch Ophthalmol* 2012;130(6):700-706. [<http://dx.doi.org/10.1001/archophthalmol.2011.2622>]
7. Yanoff M, Duker JS. *Ophthalmology*, 2nd ed. New York: Mosby, 2004:1170.

IN A NUTSHELL

- The incidence of HIV/AIDS in South Africa has started to decline, but as patients are living longer with the disease, the prevalence is still on the increase.
- More than 70% of patients will develop ocular complications at some stage during their illness.
- Sometimes the ocular disease will prompt the diagnosis of HIV.
- This article discusses clinical presentation divided into external eye (orbital and adnexal) disease, anterior segment, posterior segment and neuro-ophthalmic manifestations.