

# Minor head trauma – when does it become a major headache?

*'Its not just the kind of injury that matters, but also the kind of head.'* - Sir Charles Symmonds, 1937<sup>[1]</sup>

**N Mjoli, MB ChB, MMed, FCNeurosur (SA)**

*Chief Registrar, Division of Neurosurgery, Groote Schuur Hospital, Cape Town*

*Dr Ntethelelo Mjoli graduated from the University of KwaZulu-Natal and after a few years working in rural areas pursued neurosurgical training at the University of Cape Town. He has passed his fellowship exam.*

**G Fieggen, BSc, MB ChB, MSc, MD (Neurosurgery), FCS (SA)**

*Helen and Morris Mauerberger Professor and Head of the Division of Neurosurgery, University of Cape Town*

*Professor Graham Fieggen graduated from the University of Cape Town and completed a postgraduate degree in neuroscience at the University of London. After working as a general practitioner in rural Canada for 18 months, he returned to Cape Town to train in neurosurgery. He was a paediatric neurosurgeon at Red Cross War Memorial Children's Hospital for 10 years before being appointed as the Helen and Morris Mauerberger Professor and Head of the Division of Neurosurgery, University of Cape Town.*

Correspondence to: N Mjoli (mjolinte@gmail.com)

Head trauma is a very common problem – most parents will agree that it is just about impossible for any child (especially boys) to escape a blow to the head, either from a fall, an accident or a collision playing sport. Happily, most of these are trivial, but there is a wide range of diagnostic terms on offer, some of which are confusing and even contradictory, so we start this article by defining what we mean.

The single most important concern in evaluating anyone who has sustained head trauma is the possibility of injury to the brain, so the older, less specific term *head injury* has largely made way for *traumatic brain injury* (TBI) for those patients with any degree of neurological dysfunction, however mild.

Of the various approaches to classifying TBI (Table 1), the most useful to a busy clinician is the Glasgow Coma Scale (GCS) (Table 2).

First reported in 1974, the GCS has stood the test of time as a reliable and robust clinical tool in evaluating any patient with an altered level of consciousness.<sup>[2]</sup> As the GCS has some limitations in the preverbal child, various paediatric coma scales have been devised.<sup>[3,4]</sup> Whichever one is used matters less than ensuring that it is applied consistently and correctly.

*Severe* TBI (GCS 3 - 8/15) is seen all too often in South Africa, usually as a result of assault or motor vehicle accidents, and accounts for over 50% of all traumatic deaths. The major challenge is to strive for the best possible outcome through immediate resuscitation and transfer to a neurosurgical unit with neuro-imaging so that complications such as haematomas can be diagnosed and treated as soon as possible, ideally within the 'golden hour', together with appropriate neurocritical care management and rehabilitation.

*Mild* TBI is defined as a GCS between 13 and 15. This term includes the fully conscious patient with any neurological symptoms whatsoever following a blow to the head. This is extremely common, accounting for around 95% of all TBI in population-based studies<sup>[5]</sup> and here the challenge is that serious complications are rare, but devastating. One study found that 4% of children who had sustained a seemingly mild injury subsequently deteriorated, and of the 42 affected children, 3 died,<sup>[6]</sup> typically due to raised intracranial pressure (ICP) (covered elsewhere in this issue). This may be an over-estimate of the true incidence, but the key task is to identify the patient at risk among the vast majority who will have no complications.

*Minor or minimal* head injury are ambiguous terms that are best reserved for the patient who sustains a simple bump to the head but has absolutely no neurological symptoms.

*Concussion* is a widely used term for which there is no universally accepted definition. It may be best to think of this as a clinical syndrome that follows mild traumatic brain injury, characterised by transient loss of consciousness *or* altered mental status which recovers spontaneously. Duhaime has recently coined the term 'concussion spectrum' which encompasses a wide range of clinical presentations.<sup>[7]</sup>

## General principles of management

The clinical assessment of the fully conscious patient following a mild TBI focuses on detecting 'red flags' that justify further investigation, usually a brain CT scan.

**Table 1. Classification of traumatic brain injury**

Mechanism	Blunt, penetrating
Biomechanics	Translational, rotational
Pathology	Focal v. diffuse injury Contusion, laceration, haematoma
Pathophysiology	Primary v. secondary injury
Clinical	Glasgow coma score Duration of post-traumatic amnesia

**Table 2. Clinical classification of traumatic brain injury**

Minor	GCS 15, no neurological symptoms
Mild	GCS 15 - 13
Moderate	GCS 12 - 9
Severe	GCS 8 - 3

As always, it is important to start with a careful history – many patients will have amnesia for the actual event, but there is often a witness who can describe exactly what happened. Key features to ask about include:

- mechanism of injury – identifying high-risk scenarios such as motor vehicle accidents, falls >1 m or penetrating injury
- region of impact – especially occipital or temporal
- alteration in level of consciousness – note duration of loss of consciousness and duration of post-traumatic amnesia
- associated symptoms – vomiting, weakness, seizures
- other injuries
- past medical history – identifying risk factors such as anticoagulant use or previous neurosurgery.

Examination should include vital signs, GCS and duration of post-traumatic amnesia,<sup>[8]</sup> general and neurological examination with specific evaluation of:

- signs of raised intracranial pressure (don't forget the fontanelle in a young infant)
- scalp for haematomas, lacerations and evidence of a calvarial fracture
- signs of base of skull fracture (CSF otorrhoea/rhinorrhoea, haemotympanum/ Battle's sign or raccoon eyes)
- cervical spine.

A helpful approach is to classify the patient as low risk, medium risk or high risk on the basis of these clinical findings, which helps to guide further management, particularly with regard to imaging (Table 3).<sup>[9]</sup> The majority of patients are low risk, do not require any further investigation and can be discharged home in the care of a relative or friend, with a head injury form.

There have been numerous attempts to develop and prospectively evaluate specific clinical rules for children undergoing a

CT scan. A recent systematic review found that the pediatric emergency care applied research network (PECARN) rule was the most consistent, but would result in an unacceptably high rate of CT scans and concluded that NICE guidelines based on the children's head injury algorithm for the prediction of clinical events (CHALICE) rule were clinically the most useful.<sup>[10]</sup>

### The role of skull X-rays is very controversial.

None of these has proven to be uniformly applicable across different communities, so common sense must prevail. Obvious indications for an urgent CT scan include:

- depressed or deteriorating level of consciousness
- other evidence of raised intracranial pressure
- focal neurological signs
- penetrating injury (no matter how trivial the entry wound).

Further indications may include:

- persistent or worsening headache
- repeated vomiting
- seizures
- significant scalp swelling.

Obtaining a CT scan is not always a simple matter:

- expense
- may require transfer to another facility
- sedation may be required for a young child
- radiation exposure (it is important that radiologists take steps to limit the dose)
- remember that a *normal* CT scan does not exclude a brain injury, and an *early* CT scan (<6 hours) may not detect slowly progressing pathology such as a venous extradural haematoma in a young infant.

The role of skull X-rays is very controversial. In most developed countries these have been almost entirely abandoned in the setting of trauma, but in developing countries where access to CT is more limited, there is still a role for obtaining a skull X-ray as long as one remembers that absence of a fracture does *not* exclude a significant injury.<sup>[11]</sup> It is important to obtain 3 standard views (postero-anterior, lateral and occipito-frontal or Towne's view) and while any fracture may justify referral for CT, the following are mandatory indications:

- posterior fossa fracture
- slot fracture (penetrating injury)
- multiple fractures or suture diastasis in an infant (suggest non-accidental injury).

Three of the commonly encountered scenarios at the primary care level are:

- an infant who has fallen often off a bed or changing table
- an elderly person who has fallen
- an older child or a young adult who has sustained an injury playing sport.

### Young infants

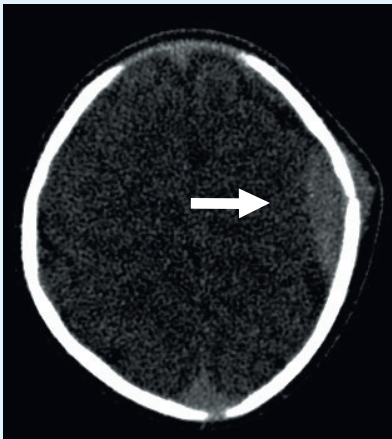
The young infant who has fallen off a bed or a changing table is a very common scenario in any emergency unit (see box). Typically, the child will appear momentarily dazed, pale, vomits and may have an impact seizure. He will then want to sleep, to the chagrin of the caregiver who fears this is the onset of coma. Unless the fall was from a height >1 m, or there is some other complicating factor such as the child striking his head against a sharp corner or suspicion of child abuse (a 'fall' is a common smokescreen), further investigation is seldom warranted. Don't forget to document the head circumference and haemoglobin at the first consultation as changes in either of these parameters may indicate an expanding intracranial haematoma in an infant.

**Table 3. Clinical grading of mild traumatic brain injury<sup>[9]</sup>**

Category	Clinical features	Recommendation
Low-risk injury	GCS 15, no loss of consciousness, amnesia, vomiting or diffuse headache	Discharge home with head injury form
Medium-risk injury	GCS 15, one of the above symptoms	CT if readily available or skull X-ray
High-risk injury	GCS 13 - 15, neurological signs or fracture on skull X-ray, other risk factors (coagulopathy, previous neurosurgery, use of alcohol or drugs, age >60)	CT mandatory

### The elderly

Most recommendations recognise age >65 years as a factor that increases the risk of complications following mild TBI.<sup>[12]</sup> The particular concern here is development of a subdural haematoma from tearing of a draining vein. This may not present acutely and may present later with signs of mass effect due to a chronic subdural haematoma.



### Clinical scenario

A 2-month-old infant was brought to the emergency unit with a history of having been sleeping on her mother's chest and rolled off, falling onto a hard floor. On examination 2 hours after the event, GCS was 11/11 with minimal scalp swelling and a soft fontanelle. As she had no other injuries and there was nothing to suggest child abuse, no imaging was considered necessary and she was discharged with a head injury form. The baby was brought back 12 hours later having vomited twice. There were still no signs of raised intracranial pressure but a CT scan was performed. This showed a linear parietal fracture with a small underlying extradural haematoma and an associated scalp haematoma (arrow).

The haematoma did not require evacuation and the infant was admitted for 48 hours of neurological observation, during which time she was asymptomatic, the fontanelle remained soft and a cranial ultrasound showed no evidence of mass effect. She was discharged to return to the neurosurgical OPD in a week and then again in 3 months to exclude a growing skull fracture.

### Sports-related mild TBI

This typically involves older children and young adults; more attention has been paid to this entity in recent years as a result of:

- greater recognition due to an evolving understanding of pathophysiology
- the need for clear guidelines concerning return-to-play
- increasing concern about potential for serious adverse outcomes, both in the short term and long term (chronic traumatic encephalopathy)
- similarities between this clinical entity and blast-related injury in soldiers.<sup>[13]</sup>

The term 'concussion' is used so frequently in relation to sports-related mild TBI that it is almost synonymous with the condition. The three international conferences on Concussion in Sport, held in Vienna (2001), Prague (2004) and Zurich (2009), have been helpful in determining a consensus approach to defining, evaluating, investigating and managing this condition.<sup>[14]</sup>

The Zurich meeting defined concussion as 'a complex pathophysiological process affecting the brain, induced by traumatic biomechanical forces' which typically has the following features:<sup>[14]</sup>

- caused by a direct blow to the head or elsewhere on the body with an 'impulsive' force transmitted to the head
- results in rapid onset of short-lived neurological impairment that resolves spontaneously
- clinical symptoms *may* or *may not* involve loss of consciousness.

### Clinical features

A wide range of symptoms have been attributed to sport-related concussion; these may be categorised as somatic, emotional/behavioural or cognitive. Patients can be symptomatic instantly or symptoms can be delayed by several minutes to hours post impact.

### Headache

This is the most commonly reported symptom, either cluster headaches, tension headaches, migraines or cervicogenic (whiplash association) and may persist for several days post injury.

### Amnesia

Amnesia may be retrograde (events prior to injury) or anterograde (events following

injury). The duration of amnesia is determined as the time between the injury and return of continuous functional memory.

### Dizziness

Dizziness is the second most common presentation of concussion and is usually associated with vertigo, diplopia and nausea.

### Tinnitus and hearing impairment

This may present acutely or in a delayed fashion and, although the audiogram is often normal, auditory evoked response will be abnormal.

### Other

Diplopia and visual blurring occurs in 10% of patients. Anosmia occurs as a result of shearing of the olfactory nerves through the cribriform plate. Low amplitude tremor may affect the upper extremities and up to 10% of patients may have a seizure following TBI (often a so-called 'impact seizure' which does not require anticonvulsants). Neck and back pain is usually associated with paraesthesia of the upper and lower limbs and there may be associated abnormal motor, sensory and tendon reflexes.

### Depression and emotional lability

Patients experience a decline in their ability to perform daily activities due to irritability, fatigue and detachment and sleep disorder.

## Cognitive

The athlete may exhibit poor memory, reduced reaction time and poor attention span.

The Sports Concussion Assessment Tool (SCAT-2) has been developed to assist on-field personnel assess the injured athlete; this useful and freely available tool encompasses the symptoms listed above and simple tests of memory and balance.<sup>[14]</sup> Neuropsychological assessment may be helpful in assessing the cognitive sequelae of concussion and guiding further management.

## Management

Although advanced neuro-imaging provides intriguing insight into the pathophysiology of concussion,<sup>[15]</sup> routine imaging plays no role in the diagnosis of concussion but is mandatory if any of the indications discussed above are present.

The focus of attention is usually on when the injured athlete can return to play. A sensible recommendation is that the player who has sustained a concussion should *not* be allowed back on the field for the same match. Note that one who has had a previous concussion has a 4-fold increase in risk for another.<sup>[16]</sup>

**Table 4. Six stages of a graduated return-to-play protocol<sup>[14]</sup>**

Stage	Activity
1	No activity
2	Light aerobic exercise, goal <70% of maximum predicted heart rate
3	Exercise drills specific to sport, non-contact
4	Training drills specific to sport, non-contact
5	Full-contact training practice
6	Return to play

**Table 5. When does minor head trauma become a major problem?**

- When it is not a minor injury – red flags
- When complications ensue – delayed deterioration
- When things are not as they seem – child abuse
- When the timing is poor – remote location, sport

Patients need a period of complete rest before they may be allowed any form of exercise. Cognitive rest to visual stimulation (i.e. no texting on cellphone, no use of computers, minimal or no television) and auditory stimulation (i.e. a quiet room is preferable with no radio or music) is required. Patients should be discouraged from reading books or doing homework (compliance with this may be easily achieved!). This period of rest should be spent at home or in their rooms and they should also keep away from situations that can be emotionally stressful. This rest period has been found to be effective even when applied to a delayed presentation.<sup>[17]</sup> Once a patient is asymptomatic at rest, a graded exercise tolerance regimen should be followed (Table 4).

The younger age group, especially teenagers, take longer to recover than professional athletes, who are reported to recover within 2 days on average and are often back to baseline within 1 week, while teenagers can take between 7 and 14 days. Symptoms are expected to have resolved by 3 weeks for all ages.

## Complications

Post-concussion symptoms can take up to 3 months before complete resolution. One of the main reasons for concern with regard to timing of return to play is the *second impact syndrome*, a rare but devastating complication reported in patients that experience a second impact before they have fully recovered from the first concussion.<sup>[18]</sup> Following concussion, there is a period when the brain is vulnerable to a second insult,

where dysregulation of cerebral blood supply may lead to vascular engorgement, brain herniation, coma and permanent brain damage. Most of the cases reported in the literature have been teenagers and this syndrome is not only limited to athletes.

The long-term consequences of multiple head injuries have been known since the recognition of ‘punch-drunk syndrome’ or ‘dementia pugilistica’ in professional boxers in the 1920s.<sup>[19]</sup> Patients manifest impairment in cognition, mood, behaviour and motor skills. More recently this condition, now termed *chronic traumatic encephalopathy*, has been found to be due to progressive neuronal dysfunction and death with neuropathological features similar to neurodegenerative diseases.<sup>[19]</sup>

## Prevention

Protective equipment may help to reduce the incidence of concussion, but has also been known to increase risk-taking behaviour. In teenage players, increasing skills rather than competitiveness may help lower the incidence of concussions.

Educational programmes are necessary to increase awareness among the general public, parents of athletes and coaches, so they are able to identify at-risk athletes. This was demonstrated by the ‘Heads Up’ awareness programme in the USA that was aimed at educating coaches.<sup>[20]</sup> Coaches were empowered to advise their players to rest and to counsel parents on the risks of keeping players who have not fully recovered on the field.

Another powerful preventive strategy is legislation. Following the introduction of the 'Lystedt Law' in Washington State in 2006 (named after a 13-year-old football player who sustained a severe brain injury after returning to play after a concussion), 42 states in the USA have enacted legislation requiring the immediate removal from play of any young athlete suspected of having sustained a concussion.<sup>[21]</sup> South Africa has no such legislation at this time and it is the responsibility of all healthcare providers to be aware of the risks and advise their patients appropriately.

### Conclusions

Minor traumatic brain injury is a common condition in the primary care setting. It is often self-limiting but while complications are rare, they can be devastating. As noted by Sir Charles Symmonds many years ago, individual patient characteristics play a major role in determining the outcome,<sup>[1]</sup> and experience has shown that the context of an injury also plays a role in evaluation and management (Table 5). Various prevention strategies have been found to be effective and every attempt should be made to protect those at risk of TBI. Consideration should be given to introducing appropriate legislation in South Africa.

### References

- Symonds CP. Mental disorder following head injury. *Proc Roy Soc Med* 1937;30:1081-1092.
- Teasdale G, Jennet B. Assessment of coma and impaired consciousness. A practical scale. *Lancet* 1974;2(7872):81-84. [http://dx.doi.org/10.1016/S0140-6736(74)91639-0]
- Raimondi AJ, Hirschauer J. Head injury in the infant and toddler: Coma scoring and outcome scale. *Child's Brain* 1984;11:12-35.
- Reilly PL, Simpson DA, Sprod R, Thomas L. Assessing the conscious level in infants and young children: A paediatric version of the Glasgow Coma Scale. *Child's Nerv Syst* 1988;4:30-33.
- Feigin VL, Theadom A, Barker-Collo S, et al. Incidence of traumatic brain injury in New Zealand: A population-based study. *Lancet Neurol* 2013;12:53-64. [http://dx.doi.org/10.1016/S1474-4422(12)70262-4]
- Snoek JW, Minderhout JM, Wilmink JT. Delayed deterioration following mild head injury in children. *Brain* 1984;107:15-36. [http://dx.doi.org/10.1093/brain/107.1.15]
- Duhaime A-C, Beckwith JG, Maerlender AC, et al. Spectrum of acute clinical characteristics of diagnosed concussions in college athletes wearing instrumented helmets. *J Neurosurg* 2012;117:1092-1099. [http://dx.doi.org/10.3171/2012.8.JNS12298]
- Wilson JTL, Teasdale GM, Hadley DM, Wiedmann KD, Lang D. Post-traumatic amnesia: Still a valuable yardstick. *J Neurol Neurosurg Psych* 1993; 56:198-201.
- Servadei F, Teasdale G, Merry G. Defining mild head injury in adults: A proposal based on prognostic factors, diagnosis and management. *J Neurotrauma* 2001;18(7):657-664. [http://dx.doi.org/10.1089/089771501750357609]
- Pickering A, Harnan S, Fitzgerald P, Pandor A, Goodacre S. Clinical decision rules for children with minor head injury: a systematic review. *Arch Dis Child* 2011;96:414-421. [http://dx.doi.org/10.1136/adc.2010.202820]
- Andronikou S, Kilborn T, Patel, Fieggen AG. Skull fracture as a herald of intracranial abnormality in children with mild head injury: Is there a role for skull radiographs? *Australas Radiol* 2003;47:381-385. [http://dx.doi.org/10.1046/j.1440-1673.2003.01206.x]
- Ropper AH, Gorson KC. Concussion. *NEJM* 2007;356:166-172. [http://dx.doi.org/10.1056/NEJMc064645]
- Ellenbogen RG. Sports and concussion. *J Neurosurg* 2012;117:1089-1091. [http://dx.doi.org/10.3171/2012.5.JNS12828]
- McCrorry P, Meeuwisse W, Johnston K, et al. Consensus statement on concussion in sport: The 3rd International Conference on Concussion in Sport, Zurich, November 2008. *Br J Sports Med* 2009;43(Suppl 1):i76-i84. [http://dx.doi.org/10.1136/bjism.2009.058248]
- Maruta J, Lee S, Jacobs EF, Ghajar J. A unified science of concussion. *Ann NY Acad Sci* 2010;1208:58-66. [http://dx.doi.org/10.1111/j.1749-6632.2010.05695.x]
- Bruce JM, Echemandia RJ. Concussion history predicts self-reported symptoms before and following a concussive event. *Neurology* 2004;63:1516. [http://dx.doi.org/10.1212/01.WNL.0000142088.32204.82]
- Moser RS, Schatz P. A case for mental and physical rest in youth sports concussion: It's never too late. *Front Neur* 2012;3:171. [http://dx.doi.org/10.3389/fneur.2012.00171]
- Weinstein E, Turner M, Kuzma BB, Feuer H. Second impact syndrome in football: New imaging and insights into a rare and devastating condition. *J Neurosurg* 2013, epub before print. [http://thejns.org/doi/abs/10.3171/2012.11.PEDS12343]
- Yi J, Padalino DJ, Chin L, Montenegro P, Cantu RC. Chronic traumatic encephalopathy. *Curr Sports Med Reports* 2013;12:28-32.
- Heads Up: Facts for physicians about mild traumatic brain injury. CDC March 2012. <http://www.cdc.gov> (accessed March 2013).
- Tomei KL, Doe C, Prestigiacomo CL, Gandhi CD. Comparative analysis of state-level concussion legislation and review of current practices in concussion. *Neurosurg Focus* 2012;33:E11. [http://dx.doi.org/10.3171/2012.9.FOCUS12280]

### IN A NUTSHELL

- Mild traumatic brain injury accounts for around 95% of clinically significant head injuries.
- Complications are rare, but devastating.
- Clinical assessment focuses on red flags that warrant further investigation, usually brain CT scan.
- Skull radiographs still have a place in under-resourced areas.
- Common mechanisms include falls in young infants and the elderly and sport in older children and young adults.
- Concussion has a wide range of clinical features.
- Prevention strategies are effective.