

# An approach to the painful upper limb

*Pain in the upper limb is a common presenting complaint in the primary health care setting and the origins of such pain are wide and varied.*

**E Mogere, MB ChB, MMed (Gen Surgery)**

*Division of Neurosurgery, University of Cape Town and Groote Schuur Hospital, Cape Town*

**T Morgado, MB ChB, MRCS (Eng)**

*Division of Neurosurgery, University of Cape Town and Groote Schuur Hospital, Cape Town*

**D Welsh, FRCS (Eng), FCS (SA) Neurosurgery**

*Division of Neurosurgery, University of Cape Town and Groote Schuur Hospital, Cape Town*

*Correspondence to: E Mogere (kimmogz@yahoo.com)*

The pain generator in the upper limb should broadly be considered as:

- spinal (radiculopathy or myeloradiculopathy)
- peripheral nerve
- musculo-tendinous
- skeletal (appendicular).

## The clinical approach

The clinical findings are key to pinpointing the pain source.

### History

Cervical and upper limb pain may present in isolation or be associated with altered sensation. The sensory alteration may be distributed in a radicular or non-radicular pattern.

Sensory alterations may present in the following ways:

- dermatomal (radiculopathy)
- non-dermatomal (peripheral nerve)
- cape-like (syringomyelia) pattern.

Sensory disturbance should alert the clinician to seek a neurological cause for the symptoms. Sensory disturbance may include numbness, paraesthesia (pins and needles) or dysaesthesia (unpleasant burning pain and hypersensitivity). Paraesthesia always occurs in the anatomical distribution of the involved neural structure. This helps to differentiate nerve root from peripheral nerve pathology.

Pain of neural origin (*neuropathic* pain) may be associated with muscle weakness, altered tendon reflexes and fasciculations. The association with weakness is not pathognomonic of neurological pathology, as this may also occur in association with musculo-tendinous disorders.

The distribution of the pain is a useful guide to its origin. Pain may be confined

to the shoulder, arm or hand, suggesting a *local* musculo-tendinous/skeletal cause.<sup>[1]</sup>

Alternatively, the pain may radiate from the neck down into the limb, or from the hand up towards the upper arm, suggesting neurological origin.

The pattern of radiation may follow a dermatomal (radiculopathy) or non-dermatomal pattern (peripheral nerve or non-neurological source). Pain radiation does not preclude a non-neurological source. Somatic neck pain may radiate to the shoulder and musculo-tendinous shoulder pain may radiate down the arm towards the elbow, but seldom beyond.

The pattern of onset of the pain also provides clues to the pathology. The sudden onset of symptoms may imply acute mechanical disruptions or pathological fracture, as opposed to chronic progressive pain associated with degenerative/inflammatory conditions.

Pain that is initiated or worsened by movement may originate from any structure involved in motion, including joints, capsules, nerves, ligaments and muscles.

A history of systemic or constitutional symptoms and a detailed past medical history are useful. History of fever and/or weight loss (infections and malignancy), trauma, previous surgery (degenerative or surgical complications), prior malignancy or endocrine disorders (hypothyroidism or acromegaly) may guide further investigations.<sup>[2]</sup>

### Physical examination

Physical examination is guided by the history. A thorough examination of the

upper limb may require examination of the eyes (to exclude Horner's syndrome), an assessment of neck movement, a vascular assessment, breast and axilla palpation and a neurological assessment of the lower limbs. This is in addition to a thorough neurological and orthopaedic assessment of the limb itself.

Neurological examination includes assessment of muscle power and bulk, tendon reflexes and sensation. Orthopaedic examination centres on joint motion and the surrounding musculature.

## Differential diagnosis

### Cervical radiculopathy

Radiculopathy is characterised by pain referred from the neck distally and sensory disturbance and weakness with associated loss of tendon reflexes.

The pain is usually distributed in a dermatomal pattern (Fig. 1). Dermatomes may overlap to some degree and may also vary slightly between individuals. For example, *shoulder pain* may be associated with C5, C6 or C7 radiculopathies. C5 pain rarely radiates below the elbow. C6 - C8 radiculopathies may cause pain in the whole limb, including the forearm and hand. Subtle variations in distribution of the pain provide clues to the nerve root origin.

The sensory disturbance may include paraesthesia and numbness. In radiculopathy, this is always discretely dermatomal in distribution and is a very accurate guide to the nerve root of origin (Fig. 2). The C5 root may have a very small sensory 'footprint' over the lateral aspect of the deltoid. The C6 root invariably supplies the thumb. The C7 root supplies the index and middle finger. The C8 root usually

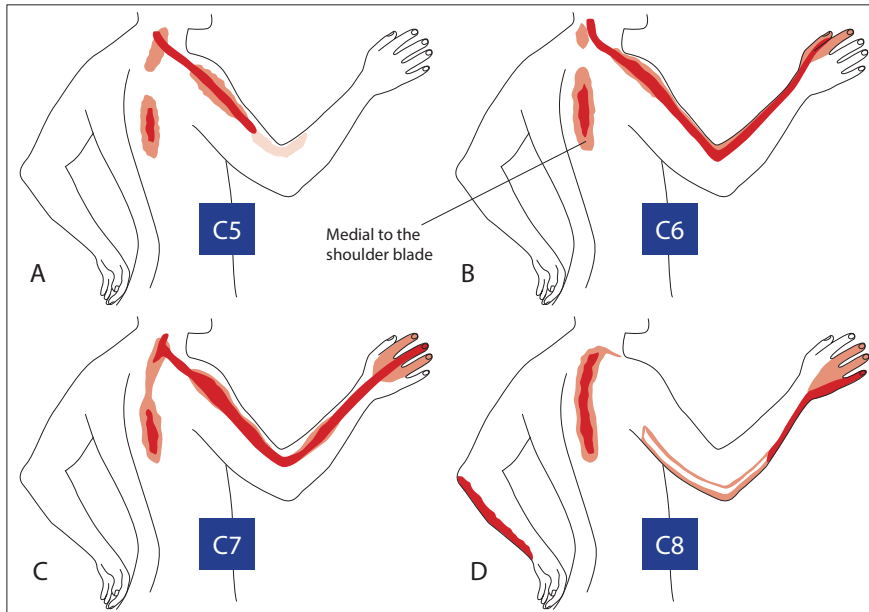


Fig. 1. Pain patterns in cervical radiculopathy C5 - C8.

supplies the little finger. The dermatomes often overlap to a degree.<sup>[3]</sup>

Motor disturbance is variable. Muscle wasting and fasciculation are usually late findings. The presence of muscle weakness alone is not pathognomonic of radiculopathy, as joint pathology may affect the local musculature.<sup>[4]</sup> However, an associated loss of tendon reflex is

highly suggestive of a radiculopathy (Table 1).

### Special examination techniques

Certain manoeuvres that are provocative in nature assist in localising the lesion, often by reproducing the clinical symptomatology associated with the pathology (Table 2).

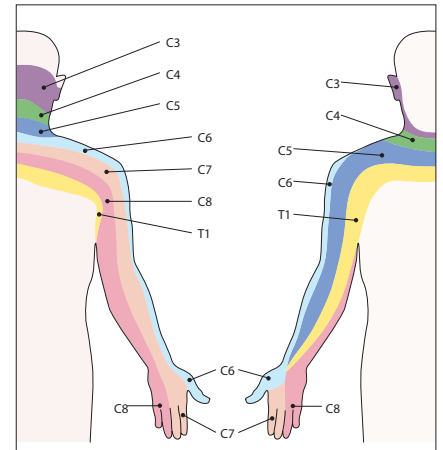


Fig. 2. Upper limb dermatomes.

### Compression syndromes (entrapment neuropathies)

An entrapment neuropathy results from compression of a peripheral nerve, most commonly the median nerve. The effect of nerve compression is mediated by ischaemia and oedema.

*Carpal tunnel syndrome* affects the median nerve at the wrist, where it passes beneath the flexor retinaculum.

Patients complain of dysaesthesia (burning) pain and paraesthesia in the radial 3 - 4

Table 1. Physical findings associated with each spinal level

Root	Pain distribution	Weakness	Sensory loss	Reflex loss
C5	Lateral upper arm	Deltoid	Lateral upper arm	Biceps reflex
C6	Lateral forearm Thumb, index finger	Biceps, brachioradialis Wrist extensors	Thumb and index finger	Supinator (+biceps) reflex
C7	Posterior arm, middle finger	Triceps, wrist flexors	Posterior forearm, index and middle finger	Triceps reflex
C8	Medial forearm, small finger	Intrinsic hand muscles, abductors, finger extension	Little finger	Triceps reflex

Table 2. Special examination techniques

Test	Description	Clinical significance
Spurling's/ neck compression test	Passive lateral flexion & extension of neck. Positive test is reproduction of radicular symptoms distant from neck	Radiculopathy
Shoulder abduction (relief) sign	Active abduction of symptomatic arm, placing patient's hand on head. Positive test is relief or reduction of ipsilateral cervical radicular symptoms	Radiculopathy
Neck distraction test	Examiner grasps the patient's head under the occiput and chin, while applying axial traction force. Positive test is relief or reduction of cervical radicular symptoms	Radiculopathy
Lhermitte's sign	Passive anterior cervical flexion. Positive test is presence of 'electric-like sensations' down spine or extremities	Myelopathy
Hoffmann's sign	Passive snapping flexion of middle finger distal phalanx. Positive test is flexion-adduction of ipsilateral thumb and index finger	Myelopathy

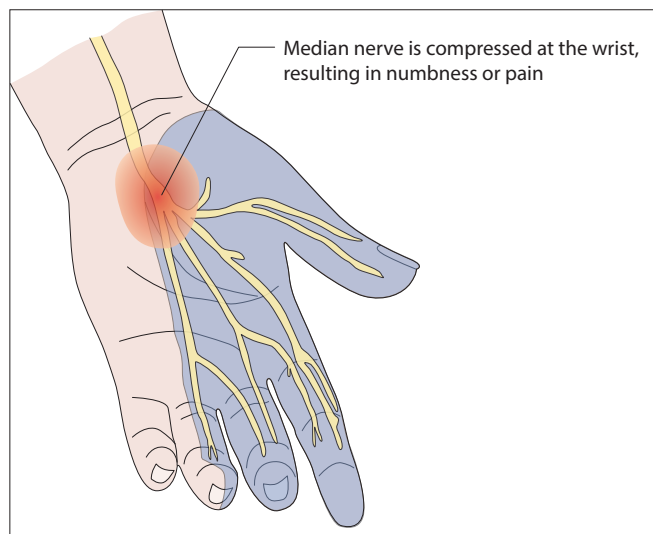


Fig. 3. Carpal tunnel syndrome.

fingers, particularly after strenuous wrist movements or at night (Fig. 3). The pain may radiate proximally.<sup>[5]</sup> The symptoms are often bilateral, but usually start in the dominant hand. Elevation or shaking of the hand may provide some relief.

Occupational risk factors (computer work), pregnancy, previous wrist trauma, endocrine disease or oral steroid use may alert the clinician to the potential diagnosis. The diagnosis is more commonly made in women in a ratio of 4:1.

Thenar muscle atrophy may be present along with weakness of thumb abduction.

Tenderness may be elicited along the length of the median nerve on palpation over the carpal tunnel. Provocative manoeuvres such as the Tinel sign (tapping over the carpal tunnel) or the Phalen test (flex the wrist as far as possible and holding that position for 60 seconds) are positive in the majority, but not all, of cases. The pressure provocation test (Durkan compression test) is performed by the examiner placing a thumb over the carpal tunnel and exerting downward pressure for 30 seconds. This test has a significantly better sensitivity and specificity.<sup>[6]</sup> Sensory loss typically includes the tips of the thumb, index and middle fingers, along with the radial aspect of the ring finger. Nerve conduction studies (EMG) may be negative in up to 30% of cases, so this remains a clinical diagnosis.

The *pronator teres syndrome* results in median nerve compression in the proximal forearm. This is a rare condition. It results in a deep ache in the forearm and pain or paraesthesia over the proximal palm.

The *cubital tunnel syndrome* affects the ulnar nerve at the elbow. Patients complain of numbness, tingling, and pain in the fourth and fifth fingers with hand weakness. Atrophy of the first dorsal interosseous and hypothenar muscles is common. The fourth and fifth fingers may claw due to weakness of the lumbricals and there is diminished sensation of the ulnar distribution, particularly the palmar and dorsal surfaces of the fifth finger.<sup>[7]</sup>

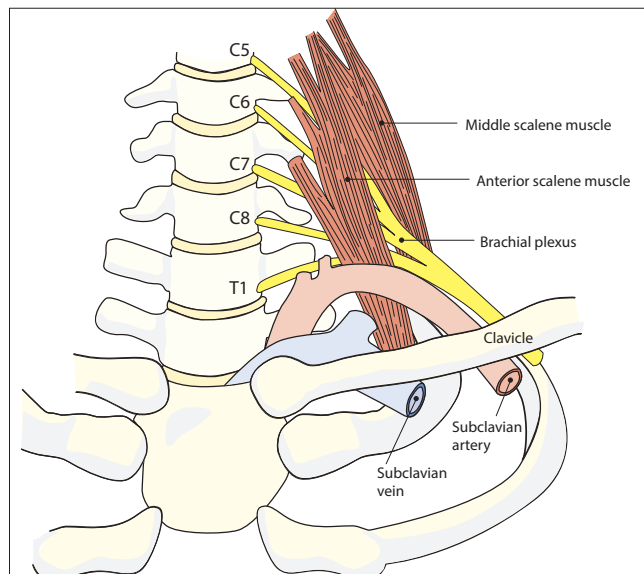


Fig. 4. Thoracic outlet syndrome.

Palpation of the elbow reveals tenderness over the ulna nerve and a positive Tinel sign over the elbow will cause paraesthesia in the fifth finger. A more sensitive provocative test is the pressure-flexion test, in which the elbow is flexed and pressure applied over the cubital tunnel for 30 seconds, with paraesthesia being reproduced in the ulna nerve distribution.

*Thoracic outlet syndrome* (TOS) is due to compression of elements of the brachial plexus (neurogenic) or subclavian vessels (vascular) in their passage from the neck to the axilla (Fig. 4).<sup>[8]</sup> The neurogenic type is far more common than the vascular syndrome. The C8 and T1 roots course superiorly over the first rib, then beneath the clavicle and into the upper limb. Neurogenic TOS may be associated with structural abnormalities such as a cervical rib, but more commonly, there is no anatomical compression.

TOS may be characterised by arm pain, hand weakness and sensory changes. The sensory changes are often confined to the C8 and T1 dermatomes. Raynaud's phenomenon, or cold hands, is mediated by sympathetic changes rather than vascular compromise.

Provocative testing in neurogenic TOS is unreliable, but the 90-degree shoulder abduction and external rotation test and a Tinel sign over the supraclavicular brachial plexus seem to have the best predictive value. Classic provocative manoeuvres include the Roos test (elevated arm stress test to induce reproduction of the neurological symptoms), the Adson test (full neck extension and head rotation toward the side being examined, during deep inhalation, to detect a reduction in radial pulse amplitude), and the Wright test (progressive shoulder abduction to reproduce the symptoms). False positives are common.

### Syringomyelia

A syrinx is a cystic cavitation of the spinal cord. It is commonly associated with craniovertebral anomalies such as Chiari malformation<sup>[11,12]</sup> (Fig. 5). Patients complain of dysesthetic pain and

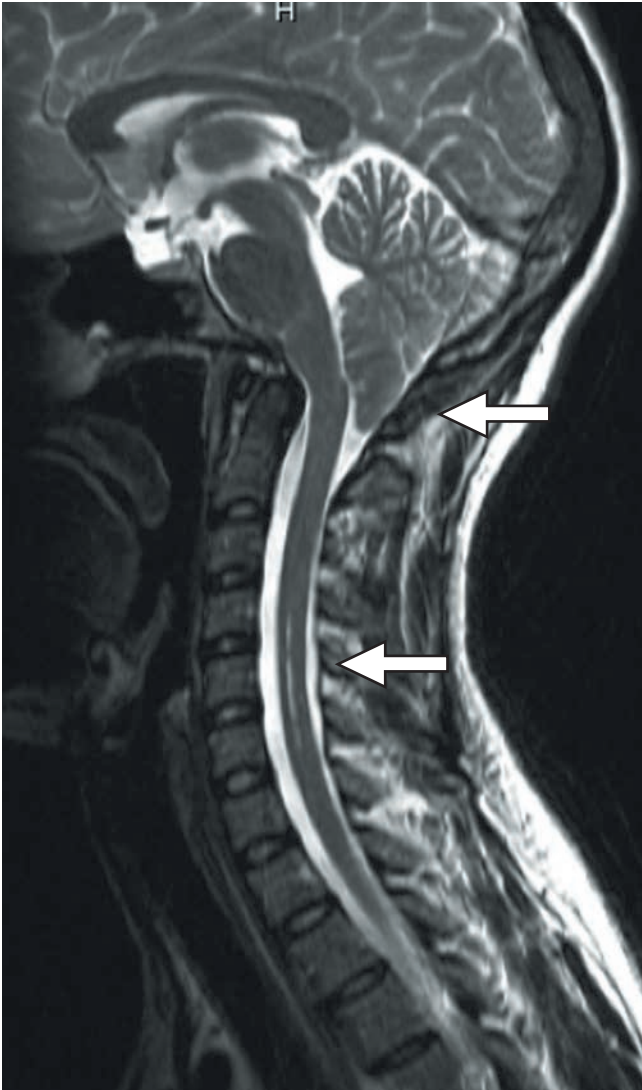


Fig. 5. Chiari malformation with herniated cerebellar tonsils (upper arrow) and cervical syringomyelia (lower arrow).

altered sensation in one or both upper limbs. The sensory changes are non-dermatomal and may be 'cape-like' in distribution. The sensory loss is more marked in the pain and temperature modalities. Motor abnormalities such as weakness and wasting of the intrinsic hand muscles may be evident. The diagnosis is confirmed with MRI scanning of the cervical spine.

### Brachial plexitis (Parsonage-Turner syndrome)

This is also known as acute brachial neuritis or neuralgic amyotrophy. The syndrome has a number of potential triggers such as a febrile illness, vaccination, strenuous exercise or surgery.

It is characterised by acute onset of unilateral severe shoulder pain for 7 - 10 days, followed by profound muscle weakness and wasting (non-myotomal, but concentrated around the shoulder). There may be associated sensory alterations. The weakness may take up to 24 months to resolve.<sup>[13,14]</sup>

MRI scanning of the shoulder may show T2 hyperintensity of the musculature. However, the diagnosis is often one of exclusion.

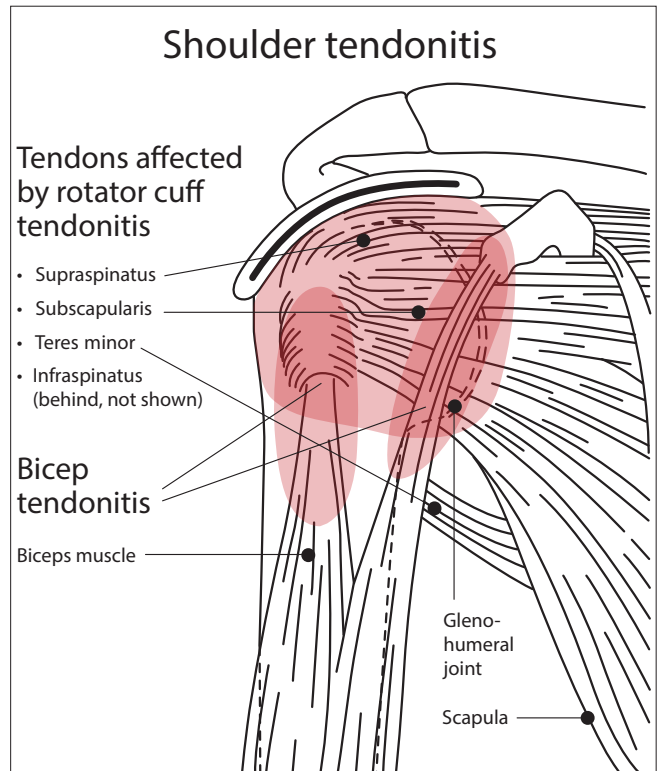


Fig. 6. Shoulder region tendonitis.

### Musculo-tendinous syndromes

This group of syndromes is characterised by inflammation of tendons, joint capsules or ligamentous attachments. The commonest area affected is the shoulder<sup>[9,10]</sup> with rotator cuff tendonitis (Fig. 6). However, the elbow (tennis elbow) and the wrist (De Quervain's tenosynovitis) may also be involved.

The clinical hallmarks are local pain and tenderness on palpation of the involved structure. Pain may be elicited on both passive movement and resisted active movement. With regard to the shoulder, simple abduction and rotation is usually diagnostic. Weakness and even muscle wasting may be evident. In tennis elbow, resisted finger extension will result in sharp pain at the lateral epicondyle of the elbow.

Sensory changes are absent.

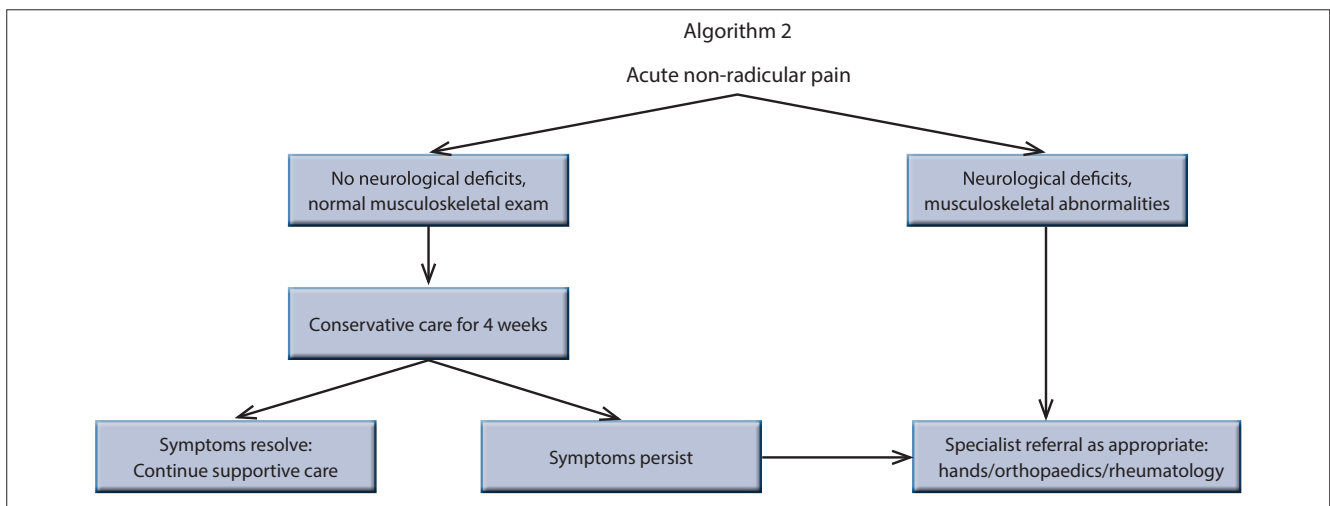
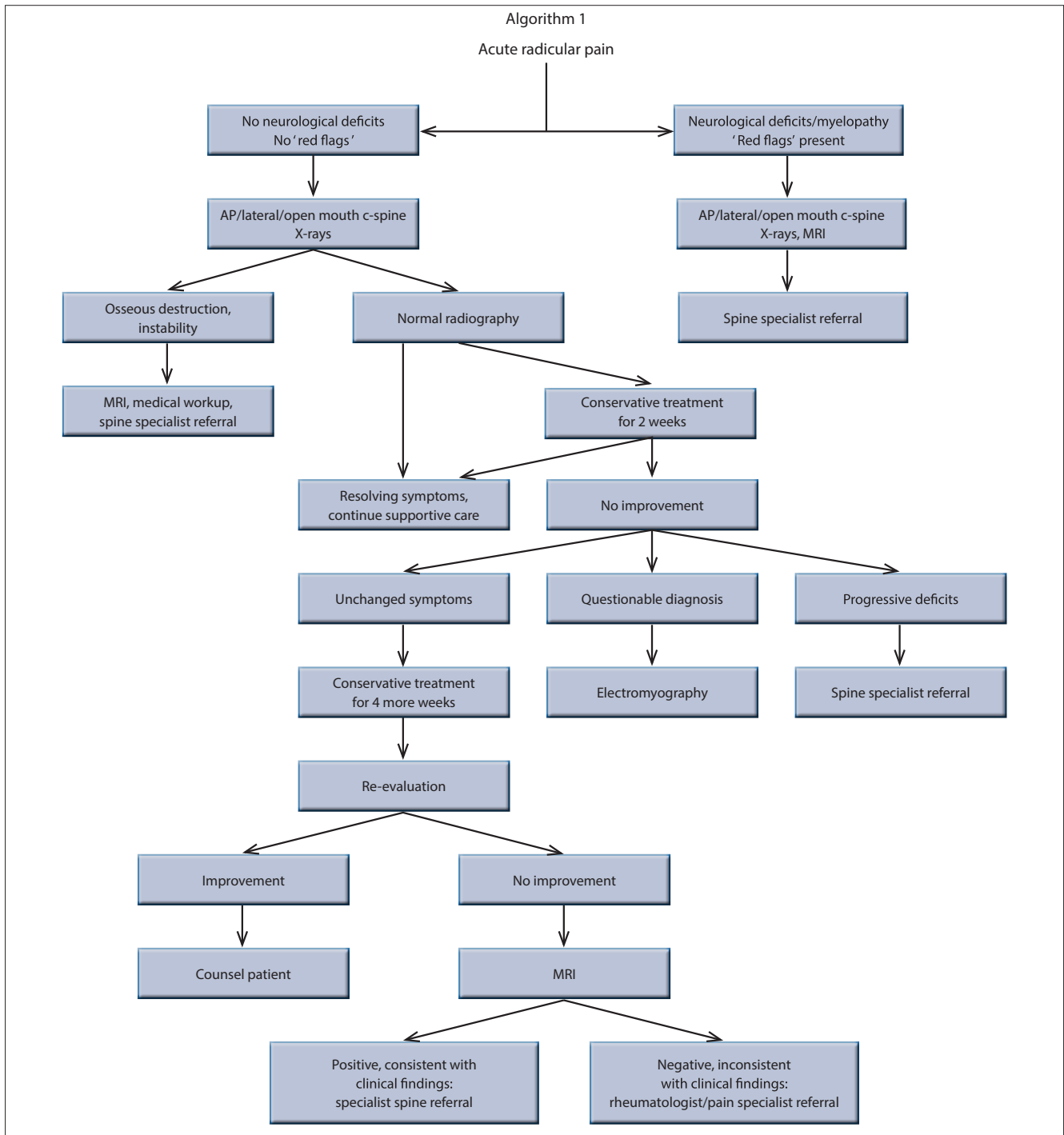
### Myofascial pain syndrome

This refers to disease characterised by chronic pain caused by multiple trigger points and fascial constrictions.<sup>[15,16]</sup> Trigger points are characterised by focal point tenderness, reproduction of pain and hardening of the muscle upon palpation, with pseudo-weakness and limited range of motion of the involved muscle on sustained pressure for 5 seconds.

### Conclusion

Pain in the upper limb is a common presenting complaint, with the origin of the pain being wide and varied. The clinical findings are key to pinpointing the pain source. Broad grouping of the pain as either radicular or non-radicular allow a clinical algorithm to be followed, below are two suggested workup patterns.

# Pain in the upper limb



### References

1. Hobbs KF, Cohen MD. Rheumatoid arthritis disease measurement: A new old idea. *Rheumatology (Oxford)* 2012;51(Suppl 6):vi21-vi27. [<http://dx.doi.org/10.1093/rheumatology/kes282>]
2. Stern WE. Localization and diagnosis of spinal cord tumors. *Clin Neurosurg* 1978;25:480-494.
3. Carette S, Fehlings MG. Clinical practice. Cervical radiculopathy. *N Engl J Med* 2005;353(4):392-399. [<http://dx.doi.org/10.1056/NEJMcp043887>]
4. Kalsi-Ryan S, Karadimas SK, Fehlings MG. Cervical spondylotic myelopathy: The clinical phenomenon and the current pathobiology of an increasingly prevalent and devastating disorder. *Neuroscientist* 2012; Nov 30. [<http://dx.doi.org/10.1177/1073858412467377>]
5. Tosti R, Ilyas AM. Acute carpal tunnel syndrome. *Orthop Clin North Am* 2012;43(4):459-465. [<http://dx.doi.org/10.1016/j.ocl.2012.07.015>]
6. Wainner RS, Boninger ML, Balu G, Burdett R, Helkowski W. Durkan gauge and carpal compression test: Accuracy and diagnostic test properties. *J Orthop Sports Phys Ther* 2000;30(11):676-682.
7. Caliandro P, La Torre G, Padua R, Giannini F, Padua L. Treatment for ulnar neuropathy at the elbow. *Cochrane Database Syst Rev* 2012;7:CD006839.
8. Deane L, Giele H, Johnson K. Thoracic outlet syndrome. *BMJ* 2012;345:e7373. [<http://dx.doi.org/10.1136/bmj.e7373>]
9. Maganaris CN, Narici MV, Almekinders LC, Maffulli N. Biomechanics and pathophysiology of overuse tendon injuries: Ideas on insertional tendinopathy. *Sports Med* 2004;34(14):1005-1017. [<http://dx.doi.org/10.2165/00007256-200434140-00005>]
10. Neviasser A, Andarawis-Puri N, Flatow E. Basic mechanisms of tendon fatigue damage. *J Shoulder Elbow Surg* 2012;21(2):158-163. [<http://dx.doi.org/10.1016/j.jse.2011.11.014>]
11. Koyanagi I, Houkin K. Pathogenesis of syringomyelia associated with Chiari type 1 malformation: Review of evidences and proposal of a new hypothesis. *Neurosurg Rev* 2010;33(3):271-284; discussion 284-285. [<http://dx.doi.org/10.1007/s10143-010-0266-5>]
12. Levine DN. The pathogenesis of syringomyelia associated with lesions at the foramen magnum: A critical review of existing theories and proposal of a new hypothesis. *J Neurol Sci* 2004;220(1-2):3-21. [<http://dx.doi.org/10.1016/j.jns.2004.01.014>]
13. Stutz CM. Neuralgic amyotrophy: Parsonage-Turner Syndrome. *J Hand Surg Am* 2010;35(12):2104-2106. [<http://dx.doi.org/10.1016/j.jhsa.2010.09.010>]
14. Tjoumakaris FP, Anakwenze OA, Kancherla V, Pulos N. Neuralgic amyotrophy (Parsonage-Turner syndrome). *J Am Acad Orthop Surg* 2012;20(7):443-449. [<http://dx.doi.org/10.5435/JAAOS-20-07-443>]
15. Bruyn GA, Moller I, Klauser A, Martinoli C. Soft tissue pathology: Regional pain syndromes, nerves and ligaments. *Rheumatology (Oxford)* 2012;51(Suppl 7):vii22-vii25. [<http://dx.doi.org/10.1093/rheumatology/kes330>]
16. Khatun S, Huq MZ, Islam MA, Uddin MW, Asaduzzaman M, Hossain MM. Clinical outcomes of management of myofascial pain dysfunction syndrome. *Mymensingh Med J* 2012;21(2):281-285.

### IN A NUTSHELL

- Upper limb pain is common.
- It may be radicular (nerve root disease) or non-radicular (other).
- Radicular pain follows a dermatome and may have an associated reflex loss.
- Clinical findings are key to identifying the cause of the pain.