

threatening environment to improve their skills and competence, resulting in shorter surgery times and fewer complications. However, non-technical skills will also be enhanced with simulation, because with debriefing activities educators can help students understand what happened during a specific scenario. This will result in changing students' behaviour and explore personal and professional values in the context of their professional role.^[8]

Ophthalmology training will benefit from simulation-enhanced education and training at both undergraduate and postgraduate level. Simulation creates opportunities for team training and reproducible, standardised, objective settings for formative as well as summative assessment. Simulation-based medical education provides opportunities for best practices in terms of care and training, error management and patient safety.^[9]

Conclusion

Simulation offers a safe environment where students are allowed to repeatedly practise a range of clinical skills without putting patients at risk. Comprehensive simulation environments allow a move away from isolated tasks to more complex clinical situations, recreating many of the challenges of real life.

References

1. Scalse RJ. Energising medical education through simulation: Powering minds, not just machines. Singapore, 6th Asia Pacific Medical Education Conference Proceedings (APMEC), 2009.
2. Rosen MA, Salas E, Silvestri S, Wu TS, Lazzara EH. A measurement tool for simulation based training in emergency medicine: The simulation module for assessment of resident targeted event responses (SMARTER) approach. *Simul Healthc* 2008;3:170-179. [http://dx.doi.org/10.1097/SIH.0b013e318173038d]
3. Kohn LT, Corrigan JM, Donaldson MS. *To Err Is Human: Building a Safer Health System*. Washington DC: National Academy Press, 2000. [http://books.nap.edu/html/to_err_is_human/exec_summ.html\(2of34\)12/4/2003](http://books.nap.edu/html/to_err_is_human/exec_summ.html(2of34)12/4/2003) (accessed 11 October 2011).
4. Eppich W, Howard V, Vozenilek J, Curran I. Simulation-based team training in healthcare. *Simul Healthc* 2011;6(Suppl):S14-S19. [http://dx.doi.org/10.1097/SIH.0b013e318229f550]
5. Gillan SN, Saleh MG. Medical simulation in ophthalmology. *Cataract & Refractive Surgery Today Europe* 2012; July/August:34-36. <http://bmctoday.net/crstodayeurope/2012/07/article.asp?f=medical-simulation-in-ophthalmology> (accessed 2 December 2012).

6. Mahr MA. The Eyesi Ophthalmic Surgical Simulator. *Cataract & Refractive Surgery Today* 2008; May:70-72. http://www.crstoday.com/PDF%20Articles/0508/CRST0508_20.pdf (accessed 2 December 2012).
7. Frank JR, Danoff D. The CanMEDS initiative: Implementing an outcomes-based framework of physician competencies. *Med Teach* 2007;29:42-647. [http://dx.doi.org/10.1080/01421590701746983]
8. Glavin RJ. Skills, training, and education. *Simul Healthc* 2011;6:4-7. [http://dx.doi.org/10.1097/SIH.0b013e31820aa1ee]
9. Ziv A, Wolpe PR, Small SD, Glick S. Simulation-based medical education: An ethical imperative. *Academic Medicine* 2003;78:783-788. [http://dx.doi.org/10.1097/00001888200308000-00006]

Glaucoma: The least the general practitioner should know

A A Stulting,¹ MB ChB, MMed (Ophth), FCS(SA) (Ophth), FRCOphth (UK), FEACO (Hon), FCMSA (Hon), FACS, FICS; **M Labuschagne**,² MB ChB, MMed (Ophth), PhD (HPE)

¹*Professor and Head, Department of Ophthalmology, University of the Free State, Bloemfontein, South Africa*

²*Head, Clinical Simulation Unit, School of Medicine, Faculty of Health Sciences, University of the Free State, Bloemfontein, South Africa*

Correspondence to: A Stulting (aaseyedoc@gmail.com)

Outline

- What is the definition of glaucoma?
- What is the classification of glaucoma?
- How is glaucoma diagnosed?
- What is the management of glaucoma?
- What is the role of the GP in the management of glaucoma?

Background

Glaucoma has been called the 'silent thief of the night' because patients may lose their peripheral vision slowly over a period of time with no symptoms in many cases. In

South Africa, the prevalence of glaucoma in people older than 40 years of age is between 4.5% and 5.3%. In whites 1 in 40 people over the age of 40 years will develop glaucoma (2%). The prevalence in African-Americans and African-Caribbeans over 40 years of age is 4 times higher.^[1] Seventy million people world-wide suffer from glaucoma.

Definition of glaucoma

Glaucoma is defined as a progressive, bilateral neuropathy of the optic nerve. It is characterised by:

- raised intra-ocular pressure (IOP) – (normal IOP = 12 - 20 mmHg)
- optic nerve head damage (cupping of the optic disc)
- visual field loss.

Glaucoma can be classified as either congenital or acquired (Table 1).

Pathophysiology

Aqueous humor is produced by the ciliary body of the eye and it flows through the trabecular meshwork to ensure that the eye is firm so that it can function optically. (Place your finger gently on your eye and then you will feel that the eye is not soft, nor hard, but firm.)

When the trabecular meshwork is obstructed by pigment (e.g. after trauma), red blood cells (e.g. after blunt trauma causing hyphema), inflammatory cells (e.g. after uveitis) or lens material (phacolytic glaucoma), the aqueous humor cannot pass through the trabecular meshwork and the intra-ocular pressure increases.

Pre-trabecular aqueous obstruction may occur if a membrane develops that covers the trabecular meshwork.

In some cases the aqueous humor passes through the iris and sometimes through the uveo-scleral route.

Table 1. Classification of glaucoma^[2]

Congenital glaucoma	Acquired glaucoma
	Open-angle glaucoma
	<ul style="list-style-type: none"> • Primary open-angle glaucoma • Secondary open-angle glaucoma <ul style="list-style-type: none"> • Pre-trabecular glaucoma • Trabecular glaucoma • Post-trabecular glaucoma
	Angle-closure glaucoma

Post-trabecular glaucoma occurs when the trabecular meshwork itself is normal but aqueous outflow is impaired as a result of elevated episcleral venous pressure. This may occur in the following conditions:

- carotid-cavernous fistulae and dural shunts
- Sturge-Weber syndrome
- obstruction of the superior vena cava.

Grading angle width

The grading of angle width is an essential part of the assessment of any patient with glaucomatous or potentially glaucomatous eyes. The main aims are to evaluate the functional status of the angle, its degree of closure and the risk of future closure.^[3]

The following angle structures are identified:

- Schwalbe's line is the most anterior structure, appearing as an opaque line. Anatomically it represents the peripheral termination of Descemet's membrane and the anterior limit of the trabecular meshwork.
- The trabecular meshwork extends from Schwalbe's line to the scleral spur. Gonioscopically, it has a ground-glass appearance.
- The scleral spur. Gonioscopically, it is situated just posterior to the trabecular meshwork and appears as a narrow, dense, often shiny, whitish band. It is the site of attachment of the longitudinal muscle of the ciliary body.

The Shaffer grading system is most commonly used today. This system records the angle in degrees of arc subtended by the inner surface of the trabecular meshwork and anterior surface of the iris. The examiner grades the angle according to the visibility of the various angle structures.

The anterior chamber angle can be classified in the following grades:^[3]

- Grade 4 (35 - 45 degrees): the widest angle (characteristic of myopia and aphakia) in which the ciliary body can still be visualised with ease. It is incapable of closure. (Remember, grade 4 = 4 structures can be seen: Schwalbe's line, trabecular meshwork, scleral spur, ciliary body.)
- Grade 3 (25 - 35 degrees): the angle is such that at least the scleral spur can be identified. It is also incapable of closure. (Remember, grade 3 = 3 structures

can be seen: Schwalbe's line, trabecular meshwork, scleral spur.)

- Grade 2 (20 degrees) is a moderately narrow angle. Angle closure is possible. (Remember, grade 2 = 2 structures can be seen: Schwalbe's line and the trabecular meshwork.)
- Grade 1 (10 degrees) is a very narrow angle in which only Schwalbe's line can be identified. The risk of angle closure is high. (Remember, grade 1 = 1 structure can be seen, only Schwalbe's line.)
- Grade 0 (0 degrees) is a closed angle due to irido-corneal contact. (Remember, grade 0 = 0 structures can be seen in the angle).

Primary angle-closure glaucoma is a condition in which elevation of IOP occurs as a result of obstruction of aqueous outflow by partial or complete closure of the angle by the peripheral iris. Secondary angle-closure glaucoma occurs when posterior forces push the peripheral iris against the trabecular meshwork or when anterior forces pull the iris over the trabecular meshwork (e.g. the contraction of inflammatory membranes).

The diagnosis of glaucoma

History

It is important to enquire about the following risk factors:

- age: older than 40 years (remember: 1 out of every 40 patients above the age of 40 years will develop glaucoma)
- race: black people have a higher risk of glaucoma.
- a positive family history is also a risk factor for developing glaucoma.

Raised IOP (more than 21 mmHg)

The IOP is measured with a tonometer. The most commonly used tonometer is the Goldmann Applanation tonometer (Fig. 1a), which is attached to a slit-lamp. An area of 3.06 mm diameter is flattened by a prism after local anaesthetic has been instilled in the eye.

The Schiottz tonometer (Fig. 1b) uses the principle of indentation tonometry, in which the extent of corneal indentation by a plunger of known weight is measured.^[4] This is the recommended instrument in general practice.

Pneumotonometers, such as the Air-Puff tonometer are popular with optometrists as contact is not made with the subject's eye

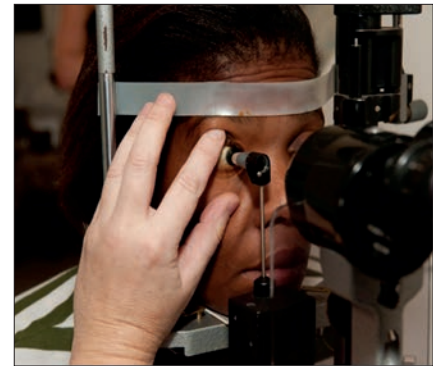


Fig. 1a. The Goldmann Applanation tonometer.



Fig. 1b. The Schiottz tonometer.

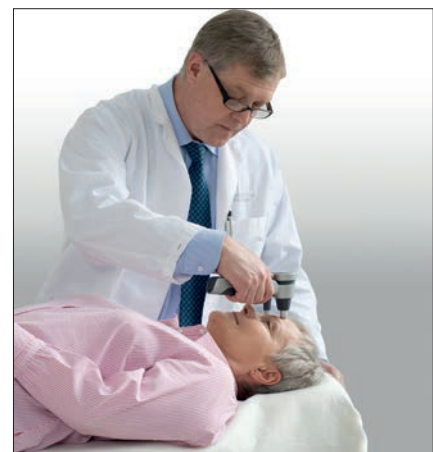

Fig. 1c. The ICare tonometer.

and topical anaesthesia is not required. The central part of the cornea is flattened by a jet of air. The time required to sufficiently flatten the cornea relates directly to the level of IOP.

Its main disadvantage is that it is accurate only within the low-to-middle range.

The ICare tonometer is a new, small hand-held instrument. A very light probe makes momentary contact with the cornea and, because only a very small force is applied to the cornea, a topical anaesthetic is not required. It can even be used in babies and small children (Fig. 1c).

Optic nerve evaluation

It is important to know the appearance of the normal optic disc because then the abnormal glaucomatous disc will be more readily diagnosed.

The normal optic disc is characterised as follows (Fig. 2):

- colour: orange-yellow
- vessels: come out centrally out of the optic disc
- cup:disc ratio: usually up to 0.4 (the C/D ratio indicates the diameter of the cup expressed as a fraction of the diameter of the disc)
- edges: well-defined and clearly visible
- shape : round or oval
- size: myopes (larger), hypermetropes (smaller).

The glaucomatous optic disc is characterised as follow (Fig. 3):

- colour: white

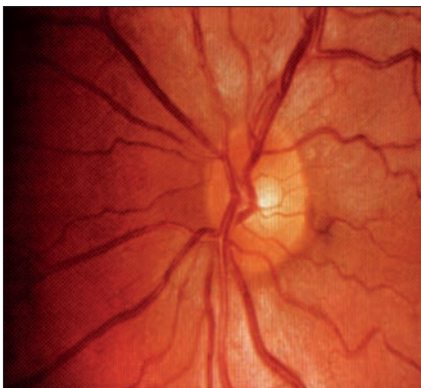

Fig. 2. The normal optic disc.

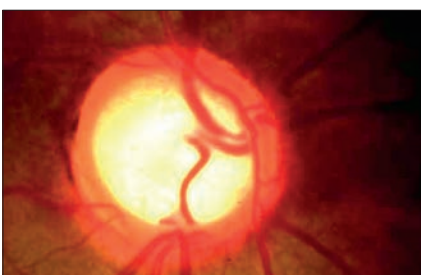


Fig. 3. The glaucomatous optic disc.

- vessels: displaced towards the nasal side
- cup:disc ratio: more than 0.4
- edges: well-defined and clearly visible
- disc haemorrhages
- bayonetting sign (characterised by double angulation of a blood vessel over the edge of the disc): with neuroretinal rim loss between the outer edge of the cup and the optic disc margin, a vessel entering the disc from the retina may angle sharply backwards into the disc and then turn towards the original direction
- neuroretinal rim: thinning and paleness
- lamellar dot sign (seen in the base of the optic disc when the neuroretinal rim recedes)
- excavated disc ('bean pot').

Visual field testing

A visual field machine, for example, a Humphrey's perimeter, is used. Various field defects can be documented, for example a nasal step of Rönne, a temporal nerve fibre defect, a Bjerrum arcuate scotoma or a Seidel scotoma.

Gonioscopy

The angle of the anterior chamber can be assessed by performing gonioscopy. The examiner, usually the ophthalmologist, uses a gonio-mirror lens to grade the angle from 1 to 4 (see above).

Management of congenital glaucoma (Fig. 4)^[5]

- Symptoms: photophobia, lacrimation, blepharospasm.
- Signs: buphthalmos (calf's eye), corneal diameter >12 mm, corneal clouding, white optic disc.
- Treatment: surgery (goniotomy or trabeculotomy).

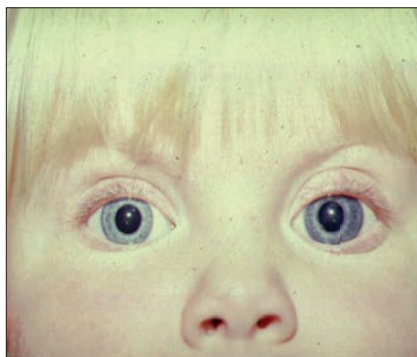

Fig. 4. Congenital glaucoma. Note that the patient's left eye is larger than the right.

Management of open-angle glaucoma

Treatment to lower the IOP includes medical therapy, laser surgery or surgery.




Fig. 5a. The gonio mirror is placed on the eye and the light beam is directed towards the angle of the eye.

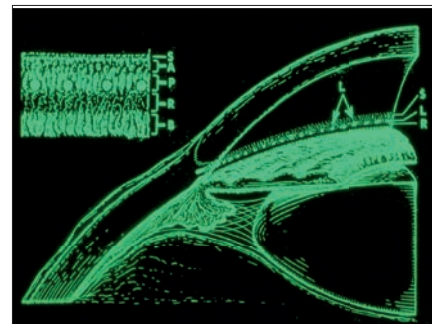


Fig. 5b. Placement of the Argon laser spots on the trabecular meshwork.

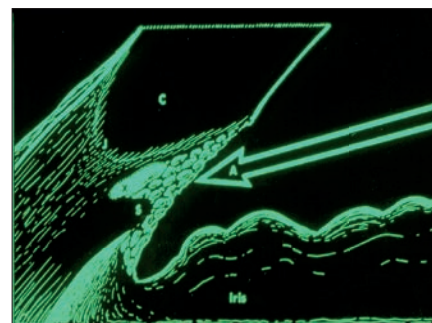


Fig. 5c. The arrow points towards the angle before placement of the Argon laser burns.



Fig. 5d. The arrow points towards the angle after placement of the Argon laser burns. Fibrosis of the trabecular meshwork occurs where the burns have been placed and contraction occurs at these areas.

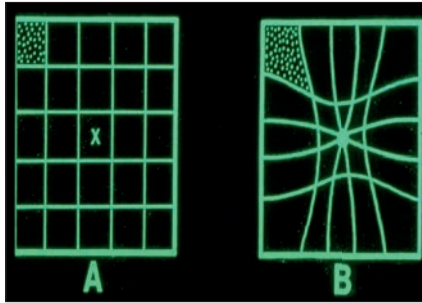


Fig. 5e. The sketch on the left (A) represents the trabecular meshwork with the openings in the meshwork (drawn as squares), while the intended areas of treatment are shown as X. The sketch on the right (B) shows that the openings in the trabecular meshwork enlarge at areas away from the fibrotic areas caused by the laser treatment. Aqueous humor can now flow more easily through the enlarged openings in the trabecular meshwork.

Medical therapy^[6]

- Topical aqueous suppressants: beta-blockers, adrenergic agents, alpha-2 agonists, carbonic anhydrase inhibitors
- Systemic aqueous suppressants: carbonic anhydrase inhibitors, e.g. Diamox
- Outflow facilitators: topical miotics, prostaglandin agonists.

Administration of eye drops

Patient information

- The drops should be placed in the inferior fornix of the eye.
- It may be helpful to use a mirror when pulling the eyelids apart.
- Use the 'no touch' technique to maintain good hygiene.
- One drop, correctly placed, is sufficient.
- Keep the drops in the fridge: the patient will feel when the cold drop goes into the eye.
- Keep the drops for an average period of 30 days to ensure maximum efficacy.
- If instilling different drops, wait at least 5 minutes between placing the drops in the eye to prevent dilution of the drops.
- Close the punctum so that the drops can stay in the eye for a longer period.

Laser

Laser trabeculoplasty is a technique in which laser energy is applied to the trabecular meshwork in discrete spots.^[7,8] Various modalities of laser trabeculoplasty exist, including:

- argon laser trabeculoplasty (ALT)
- selective laser trabeculoplasty (SLT)

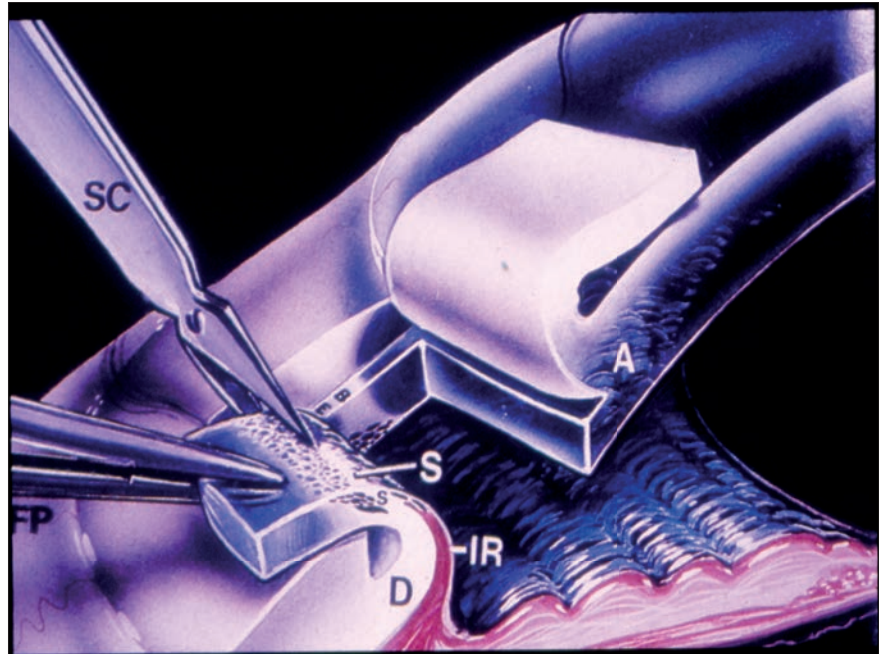


Fig. 6. The trabeculectomy operation.

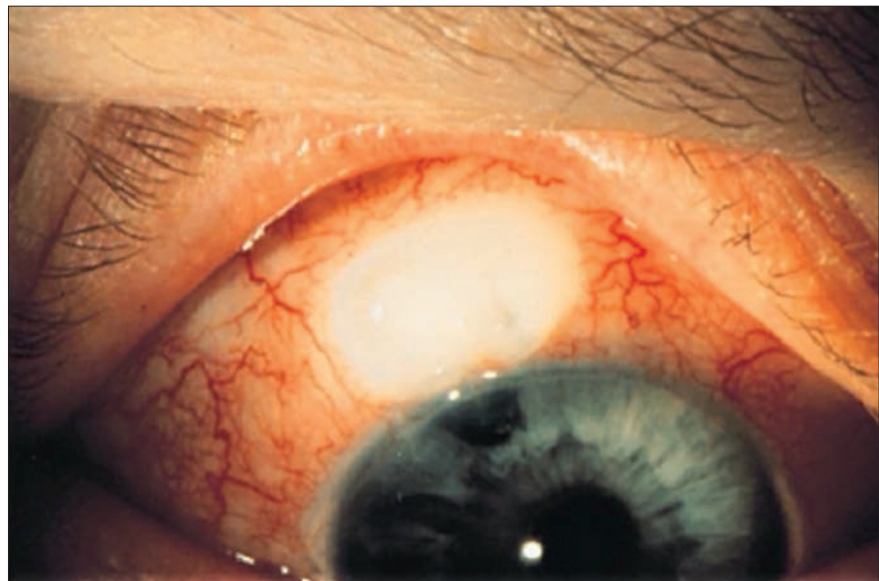


Fig. 7. The bleb after trabeculectomy surgery.

- diode laser trabeculoplasty (DLT).

Argon laser trabeculoplasty (ALT) (Figs 5a-e)

The mechanism of ALT is such that the treated area of trabecular meshwork may shrink, causing stretching of adjacent areas, which leads to increased outflow facilities.

Despite favourable results, laser therapy has not replaced medications as primary therapy in patients with primary open-angle glaucoma (POAG). This was partly due to loss of efficiency over time and the introduction of more effective glaucoma medications, namely prostaglandin analogues.

The role of laser trabeculoplasty is limited and it is used either as adjunctive therapy or as an intermediate step between failed medical therapy and surgical intervention.

Selective laser trabeculoplasty (SLT)^[9]

SLT is a relatively new procedure which uses a 532 nm Q-switched Nd:YAG laser. This selectively targets melanin pigment in the trabecular meshwork cells, without damaging the non-pigmented structures. It may be safer than ALT as there is no thermal tissue damage. The main advantage is that treatment can be repeated, the laser is portable and the initial results show that it is probably as effective as

ALT. This technique may have a place in treating patients in the rural areas of South Africa where compliance or follow up may be a problem.

Diode laser trabeculoplasty (DLT)^[10]

Diode laser ablation lowers the IOP by destroying part of the secretory ciliary epithelium, thereby reducing aqueous secretion. More than one treatment is usually required for adequate pressure control.

Surgery

Surgical treatment involves either trabeculectomy with or without mytomicin-C (MMC) (Figs 6 and 7) or valves (Molteno, Ahmed, Baerfeldt).

Closed-angle glaucoma and its management

Symptoms

- rapidly progressive impairment of vision
- periocular pain and congestion
- nausea and vomiting may occur in severe cases
- transient blurring and haloes around lights.

Signs

- circumcorneal redness (in contrast with conjunctivitis, where the redness is mainly in the fornices)
- corneal oedema
- increased IOP
- the pupil is vertically oval and fixed in the semi-dilated position and is unreactive to both light and accommodation.

Treatment

- Initial medical therapy:
 - carbonic anhydrase inhibitors (Diamox 500 mg followed by oral acetazolamide 250 mg 4 times daily.
 - hyperosmotic agents (oral glycerine given by the ophthalmologist).
- Peripheral Nd: YAG laser iridotomy to re-establish the communication between the anterior and posterior chambers of the eye by making an opening in the peripheral iris.
- A prophylactic laser iridotomy must be performed on the fellow eye to prevent an acute attack in the future.
- Sometimes a surgical peripheral iridectomy must be performed if the iridotomy is too small and not functioning.
- Trabeculectomy is reserved for those patients who fail to respond or where the angle is chronically closed.

The role of the general practitioner in glaucoma

- Take a good history from the patient:
 - Do you have glaucoma?
 - Any family member with glaucoma?
- Tell your patients that every person older than 40 years should test their IOP annually.
- Make sure that your patients have regular measurements for IOP.
- Make sure that your glaucoma patients go for regular visual field testing.

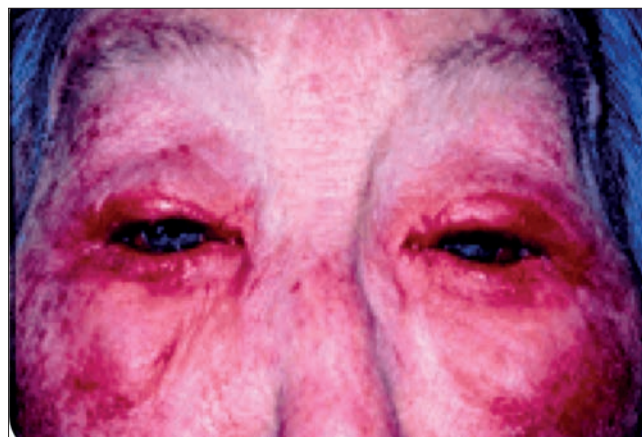


Fig. 8. Severe allergic reaction due to glaucoma medication.

- Do regular direct ophthalmoscopy on your patients to detect glaucomatous optic nerve changes.
- Monitor the therapy and make sure that you know the side-effects of the drops your glaucoma patients are taking, namely:
 - beta blockers: postural hypotension, bronchospasm
 - Diamox: potassium depletion
 - topical allergy (Fig. 8).
- Repeat prescribing glaucoma drops – to be reviewed 6-monthly.
- Inform and reassure every glaucoma patient.
- Refer patients to the ophthalmologist for re- assessment, e.g. side-effects of medication, post-glaucoma surgery or red eye.
- Remember that glaucoma is a medical disease that should be under the control of an ophthalmologist.

References

1. Fraser S, Wormald R. Epidemiology of glaucoma. In: Yanoff M, Duker JS, eds. Ophthalmology, 2nd ed. St Louis: Mosby, 2009,1413.
2. Kanski JJ, McAllister JA, Salmon JF. Glaucoma. A Colour Manual of Diagnosis and Treatment, 2nd ed. London: Butterworth-Heinemann, 1996:3-5.
3. Kanski JJ, McAllister JA, Salmon JF. Glaucoma. A Colour Manual of Diagnosis and Treatment, 2nd ed. London:Butterworth-Heinemann, 1996:17-19.
4. Kanski JJ, Bowling B. Clinical Ophthalmology: A Systematic Approach, 7th ed. Edinburgh: Elsevier Saunders, 2011:313-315.
5. Bruce Shields M. Textbook of Glaucoma, 4th ed. Baltimore: Williams and Wilkins, 1998:195-205.
6. Cioffi GA, Duncan J, Girkin CA, et al. Basic and Clinical Science Course, Section 10. Glaucoma. San Francisco: AAO, 2009-2010:188.
7. Cioffi GA, Duncan J, Girkin CA, et al. Basic and Clinical Science Course, Section 10. Glaucoma. San Francisco: AAO, 2010-2011:167-183.
8. Kanski JJ, Bowling B. Clinical Ophthalmology A Systematic Approach, 7th ed. Edinburgh: Elsevier Saunders, 2011:387-388.
9. Kanski JJ, Bowling B. Clinical Ophthalmology A Systematic Approach, 7th ed. Edinburgh: Elsevier Saunders, 2011:388.
10. Kanski JJ, Bowling B. Clinical Ophthalmology A Systematic Approach, 7th ed. Edinburgh: Elsevier Saunders, 2011: 390.