

# Corneal ulcers: For the general practitioner

*A corneal ulcer is a defect in the epithelial layer of the cornea. The general practitioner may play an important role in early management and appropriate referral. Incidence varies and depends on aetiology.*

**S Ballim**, MB ChB, Dip Ophth (SA), FC Ophth (SA)

Department of Ophthalmology, University of KwaZulu-Natal, Durban, South Africa

Correspondence to: S Ballim (shaheerballim@gmail.com)

## Basic clinical assessment of the cornea

### History

Presenting complaints include pain, irritation, decreased vision or foreign-body sensation. Ask about any history of trauma, including nature of injury, the timing and the relationship to drop in vision. Specific enquiry as to instillation of medication (e.g. steroid drops) or home remedies (e.g. breast milk or urine) is important, as these may be important predisposing factors and give clues as to the aetiology. Contact lens use is a very common cause of corneal ulcers.

### Tools for examination

In general practice it is presumed that a slit-lamp and other specialised equipment is unavailable. It would be reasonable to have the following ophthalmic tools at one's disposal:

- visual acuity chart
- fluorescein strips
- topical anaesthetic eye drops
- direct ophthalmoscope.

### Examination

Assessing vision with a Snellen visual acuity chart gives a clue as to the extent of the problem (e.g. a corneal abrasion with good vision is unlikely to require specialist intervention). Each eye should be tested individually, unaided and then with pinhole, with the fellow eye occluded.

As a corneal epithelial defect is, in most cases, a painful condition, topical anaesthetic drops will assist in making the patient comfortable enough to open his/her eyes. Use a torch or direct ophthalmoscope to examine the cornea and note any haziness of the cornea, foreign bodies, or abnormalities of the pupil shape. The anterior chamber should be well formed. A flat anterior chamber or protrusion of the iris usually signifies a perforated ulcer thus warranting emergency referral.<sup>[1]</sup> The red reflex should be observed. This helps to highlight subtle corneal opacities, allows assessment of the pupil, and gives a

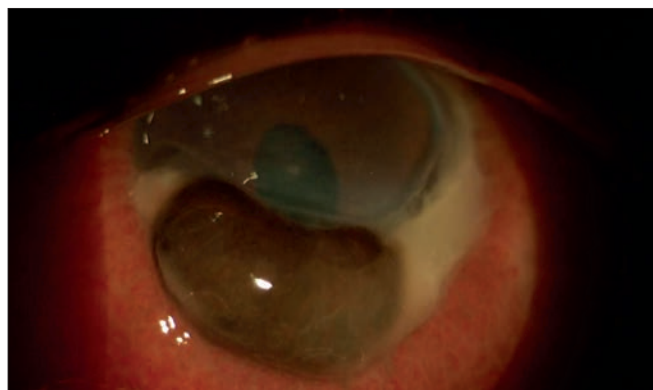


Fig. 1. Perforated corneal ulcer. Note the iris prolapse and the distorted pupil.

clue as to the health of the posterior segment of the eye. Compare findings with the fellow eye.

Fluorescein dye should be instilled. Any epithelial defects will stain green. The stain shows up best under blue light (present on some ophthalmoscopes). This can, however, be adequately demonstrated with a standard torch. The tear film will become apparent and the lacus lacrimalis can be assessed. Dry eye is a very significant factor in many corneal epithelial disorders.

**Topical antibiotics have been shown to have action against both bacterial and fungal pathogens and are suitable for preventing both possible superimposed infections.**

Corneal sensation may be tested with a wisp of cotton wool and compared with the other eye. Sensation may be decreased in trigeminal nerve palsies, chronic contact lens wear, chronic ocular surface disorders and systemic neuropathic disorders, e.g. diabetes. Note that the use of topical anaesthetic drops will nullify sensation testing.

Examine the eyelids. Clues to aetiology may be present on the skin, e.g. herpes zoster scars, lid lacerations, burns. Lid malposition should be excluded. Facial nerve function must be assessed as dysfunction could affect eyelid closure (e.g. lagophthalmos). Eversion of the upper lid is important to exclude a foreign body abrading the cornea. Corneal exposure from eyelid defects, ectropion or lagophthalmos may result in exposure keratitis.

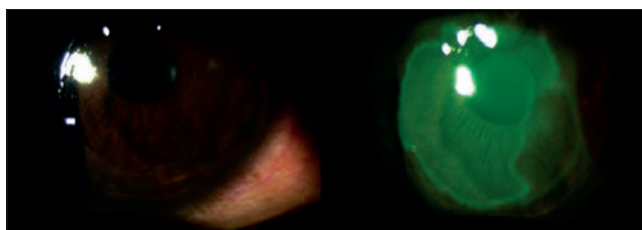


Fig. 2. Corneal abrasion. Note the epithelial defect, with clear underlying stroma. The defect stains after instillation with fluorescein dye.

## Classification of corneal epithelial defects

Corneal epithelial defects may be classified aetiologically into traumatic (including corneal abrasions), mechanical, infective, autoimmune and neurotrophic.

### Corneal abrasions

Direct trauma to the cornea may abrade the epithelium, leaving a clear epithelial defect. Non-penetrating corneal foreign bodies may leave behind an epithelial defect when removed.

Patients present with pain, mildly decreased visual acuity and a history of trauma. Examination reveals a staining defect with a clear underlying and surrounding cornea. There may be other associated ocular, orbital or eyelid injuries.

Management involves exclusion of foreign bodies, prevention of infection, promoting epithelial healing and pain relief. Chloramphenicol ointment 6-hourly is a very cost-effective treatment. Topical antibiotics have been shown to have action against both bacterial and fungal pathogens and are suitable for preventing both possible superimposed infections.<sup>[2,3]</sup>

Patching the affected eye assists with epithelial healing and pain relief. Indications for referral include a decrease in visual acuity, worsening pain, concomitant ocular injuries, delayed healing or haziness of the surrounding or underlying cornea. Resolution with full visual recovery can be expected within 24 - 72 hours and follow-up should be scheduled accordingly. Complications include infective keratitis, persistent epithelial defect and recurrent corneal erosions, all of which require specialist referral.

## Contact lens use is a very common cause of corneal ulcers.

### Infective corneal ulcers

Infective corneal ulcers occur predominantly after trauma or in eyes predisposed to infection, e.g. contact lens wearers, chronic ocular surface disease, topical steroid use, previous ocular surgery, eyelid abnormalities and diabetes.<sup>[2,4]</sup> They are a significant cause of ocular morbidity and visual loss. Incidence varies from 6.3 to 710 per 100 000 per year and is 6-fold higher in contact lens wearers.<sup>[2]</sup> Aetiology may be bacterial, fungal, viral, spirochete or parasitic.

Bacterial causes include *Staphylococcus aureus*, *Staphylococcus epidermidis*, *Streptococcus pneumoniae*, *Streptococcus pyogenes*,

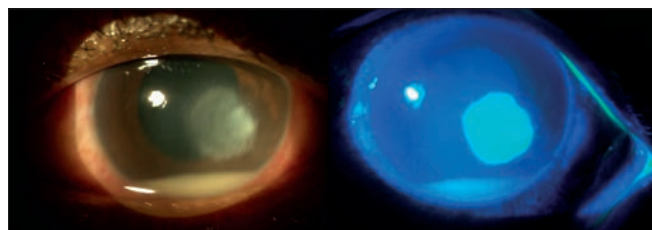


Fig. 3. Infective corneal ulcer. The staining epithelial defect with underlying stromal infiltrate can be seen. A hypopyon is present.

*Moraxella* species, *Pseudomonas aeruginosa*, *Proteus* species, *Klebsiella pneumoniae*, *Yersinia* species and *Escherichia coli*.<sup>[5]</sup> Fungal causes include *Candida albicans*, *Aspergillus flavus*, *Fusarium solani*, *Penicillium* species, and *Aspergillus fumigatus*.<sup>[5]</sup>

*Acanthamoeba* is the commonest protozoal infection of the cornea and together with *Pseudomonas* species is commonly associated with keratitis from contact lens wear.<sup>[6]</sup> Ocular injury with muddy implements is associated with *Acanthamoeba* keratitis.<sup>[4]</sup>

Clinical features include pain, decreased vision, foreign-body sensation and red eye.<sup>[2]</sup> Duration of symptoms depends on aetiology. Clinical examination commonly reveals decreased visual acuity. Corneal infiltrate seen as haziness or whitening of the usually transparent cornea is universal to infective ulcers in varying degrees. This signifies the inflammatory response to the pathogen. The anterior chamber may have a collection of pus cells seen as a white fluid level, i.e. hypopyon. The conjunctiva is almost always injected and discharge is frequent. Corneal ulcers may perforate, requiring emergency surgical intervention.




Fig. 4. Dendritic ulcer stained with fluorescein (courtesy Dr S M Singh).

Management involves hourly topical empiric antibiotic drops and urgent referral. Early commencement of effective treatment improves visual prognosis.<sup>[2]</sup> Determining aetiology is important and can guide definitive treatment.<sup>[7]</sup> Topical steroids are to be avoided at primary care level. Topical fourth-generation fluoroquinolones should be reserved for confirmed cases of microbial keratitis to limit antibiotic resistance and maintain susceptibility of ocular pathogens to this drug.<sup>[2]</sup>

Herpetic epithelial viral keratitis presents classically as a dendritic ulcer but may vary in severity from punctate corneal staining to a large geographic ulcer. Associated conjunctivitis is common (Fig. 4). Acyclovir ointment 5 times daily is an effective treatment.<sup>[2]</sup>

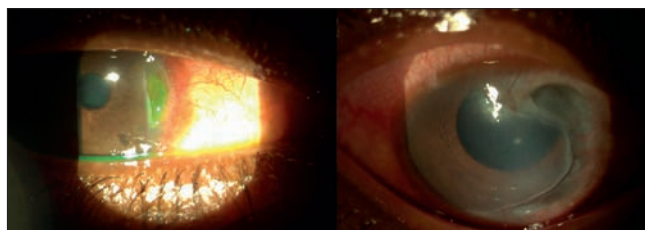


Fig. 5. Peripheral ulcerative keratitis.

## Peripheral ulcerative keratitis

The causes for a corneal epithelial defect near the corneal limbus are vast. Non-infective autoimmune causes are a consideration in these cases. Rheumatoid arthritis, sarcoidosis, Wegener's granulomatosis and polyarteritis nodosa are some of the possible causes. Local autoimmune syndromes are also a possibility, e.g. Mooren's ulcer. Intensive immunosuppression may be required in these cases. Blepharitis is a common cause of this condition (marginal keratitis). Consequently adequate treatment and control of the blepharitis is important.

## Corneal burns

Burns may be thermal, radiation or chemical. Part of the damage may include corneal epithelial defects. Adequate analgesia is required for examination, followed by pH measurement and copious irrigation of the eye with a litre of normal saline. Fluorescein will aid in quantifying the damage. Referral is indicated for corneal or conjunctival epithelial defects, limbal ischaemia, decreased vision, perforation and delayed presentation.

## Mechanical causes of corneal ulcers

Exposure from lagophthalmos, lid defects or ectropion causes drying out and sloughing of the corneal epithelium. Adequate tear supplementation and definitive eyelid

surgery are mandatory in severe cases. Entropion, trichiasis and dystichiasis can cause abrasion of corneal epithelium.

## Other causes

Corneal ulcers, known as shield ulcers, may also be seen in chronic allergic ocular conditions such as vernal keratoconjunctivitis. The primary pathophysiology is the mechanical abrasion of the cornea by giant papillae on the tarsal conjunctival surface. A plaque may form on the ulcer, making it difficult to recognise the staining pattern. Control of the allergic process is fundamental to the management of this condition. Because this is a chronic condition, the general practitioner is a vital part of the ongoing holistic management, monitoring control of the allergic conjunctivitis and awareness of possible vision-threatening complications.

## Eversion of the upper lid is important to exclude a foreign body abrading the cornea.

Neurotrophic corneal ulcers develop as persistent epithelial defects in the setting of sensory deficit of the cornea, e.g. trigeminal nerve palsy. Clinical features include a painless ulcer with regular rounded well-defined edges and minimal infiltrate if uninfected. Corneal sensation

is depressed. Dry eye is common in this setting.

## Conclusions

The general practitioner plays a vital role in the early detection and commencement of treatment in many types of corneal epithelial defects. The use of the techniques described is helpful in excluding or detecting indications for referral and thus limiting the possible visual consequences for the patient.

## References

1. Agrawal V. First aid for complications of infectious keratitis. *Indian J Ophthalmol* 2008;56(3):221-222.
2. Thomas PA, Geraldine P. Infectious keratitis. *Curr Opin Infect Dis* 2007;20(2):129-141. [<http://dx.doi.org/10.1097/QCO.0b013e328017f878>]
3. Day S, Lalitha P, Haug S, et al. Activity of antibiotics against *Fusarium* and *Aspergillus*. *Br J Ophthalmol* 2009;93(1):116-119. [<http://dx.doi.org/10.1097/QCO.0b013e328017f878>]
4. Bharathi MJ, Ramakrishnan R, Meenakshi R, et al. Analysis of the risk factors predisposing to fungal, bacterial and *Acanthamoeba* keratitis in South India. *Indian J Med Res* 2009;130(6):749-757.
5. Narsani AK, Jatoti SM, Khanzada MA, et al. Etiological diagnosis of microbial keratitis. *J Coll Physicians Surg Pak* 2010;20(9):604-607. [<http://dx.doi.org/10.1097/JCPS.0b013e328017f878>]
6. Patel A, Hammersmith K. Contact lens-related microbial keratitis: recent outbreaks. *Curr Opin Ophthalmol* 2008;19(4):302-306. [<http://dx.doi.org/10.1097/ICU.0b013e328045e74>]
7. Garg P. Diagnosis of microbial keratitis. *Br J Ophthalmol* 2010;94(8):961-962. [<http://dx.doi.org/10.1136/bjo.2010.182550>]

## IN A NUTSHELL

- Adequate assessment of the cornea includes testing visual acuity and staining with fluorescein dye.
- High suspicion of infective corneal ulcers with early referral and commencement of topical antibiotics is prudent.
- Ocular foreign bodies and coexistent injuries should be excluded in cases of trauma.
- Topical corticosteroids should be avoided unless under care of an ophthalmologist.
- In eyelid abnormalities, corneal problems should be actively excluded to prevent visual loss.
- Indications for referral to an ophthalmologist in the setting of a corneal epithelial defect include:
  - infective corneal ulcers
  - abrasions not healed in 48 hours
  - allergic conjunctivitis with associated corneal ulcers
  - chemical burns to the eye
  - drop in visual acuity
  - globe perforation (ocular surgical emergency)
  - diagnostic uncertainty.