

More about ... Nuclear medicine

The use of nuclear medicine in childhood

A Brink, MB ChB, DCH (SA), MMed Nuclear Medicine

Red Cross War Memorial Children's Hospital, and Division of Nuclear Medicine, Department of Paediatrics, University of Cape Town, South Africa

Corresponding author: A Brink (anita.brink@gmail.com)

This article briefly discusses some of the more common nuclear medicine investigations available for use in the paediatric population.

Thyroid scintigraphy

In neonates with hypothyroidism detected on neonatal screening and confirmed by subsequent testing, a radionuclide thyroid scan should be performed as soon as possible. It must be undertaken in all nuclear medicine departments as a matter of urgency. Any delay in treatment should be avoided. Thyroid replacement therapy can interfere with the uptake of Tc-99m pertechnetate and therefore should be started as soon as the scan is completed.

The radionuclide thyroid scan provides information on the probable cause of the hypothyroidism. The absence of Tc-99m pertechnetate uptake in the expected position or in an ectopic site usually confirms agenesis. In thyroid glands with an abnormal embryological descent the volume of thyroid tissue is usually smaller than normal, with poor function (Fig. 1). Increased pertechnetate uptake is rarely seen in the gland, in keeping with dysmorphogenesis, which has a higher hereditary incidence.^[1]

Renography

Hydronephrosis is the most commonly detected renal congenital abnormality. The majority of children with hydronephrosis detected antenatally will not need surgical intervention.^[2,3] The role of renography in children with moderate and severe hydronephrosis is to assist to identify children who need surgical intervention.

The renogram investigates renal function. Tc-99m MAG3 is the preferred radiopharmaceutical. The four main aspects of renal function evaluated on a renogram are renal blood flow, renal function, transit of urine from the renal cortex to the renal pelvis, and flow of urine from the kidneys to the bladder. The only parameter reproducible in the same patient on different days is the differential renal function (DRF),

comparing the function of one kidney with that of the other.

The current working definition of renal obstruction is any impairment of renal outflow that, left untreated, would lead to a loss of renal function or would prevent the normal maturation of renal function.^[4] Using renographic criteria, obstruction can only be diagnosed if the patient has a decrease in DRF of more than 10% on the affected side

on serial studies. A decrease of more than 5% in DRF should be considered as a warning sign and the interval of follow-up studies, e.g. renal ultrasound and renograms, should be shortened. Cases of bilateral hydronephrosis are more complicated and are not discussed in full in this article.

In cases of a decrease in renal function most of the function will recover with prompt surgical intervention.^[3]

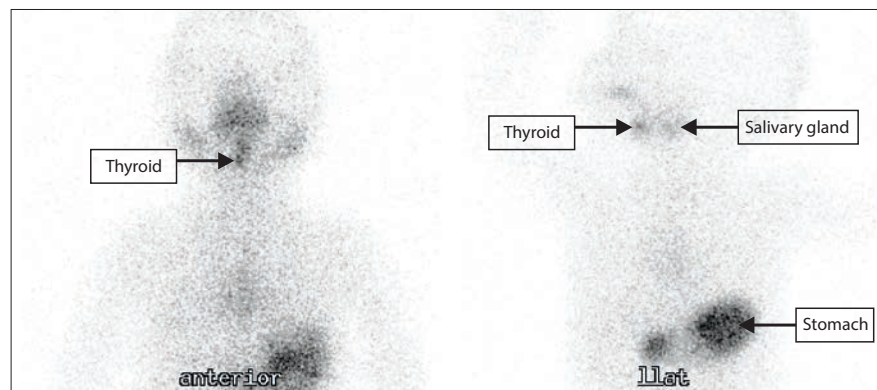


Fig. 1. An example of a poorly functioning lingual thyroid.




Fig. 2. Posterior images of an indirect cystogram showing reflux of a large volume into the left kidney.

It is tempting to interpret the drainage as shown on renogram curves, but this is not reproducible. If drainage is normal, the patient is unlikely to develop obstructive uropathy. There are numerous causes for poor drainage on a renogram; using this as a criterion for interpreting obstruction may lead to unnecessary surgical intervention with associated complications.

Indirect cystography

This is a relatively non-invasive way of detecting vesico-ureteric reflux (VUR) in children who are potty trained. On a renogram, most of the activity clears from the kidneys and is found in the bladder at the end of the study. Therefore, without inserting a catheter, there is contrast medium in the bladder. The child then simply voids in front of the camera and the presence or absence of significant reflux can be confirmed (Fig. 2).

An advantage is that the renogram provides information on renal function and the presence of renal scars, in addition to being a non-invasive way of detecting reflux.

Investigating urinary tract infection (UTI)

In recent years, there has been a move towards decreasing the number of investigations in children with UTI.^[5] When faced with a child with UTI, those with a normal urinary tract are investigated far more conservatively than those with abnormalities of the kidneys, ureters or bladder. However, further imaging may be indicated in children with recurrent or atypical UTI.

Milk scans

In children with possible gastro-oesophageal reflux disease, milk scans are an elegant physiological way of investigating the problem. This is a four-part study.

Part one: While sitting on the mother's lap in front of the camera, the child drinks a small amount of his usual feed with a small amount of tasteless radiopharmaceutical added to it. The transit of activity through the oesophagus is then evaluated.

Parts two and three: Once the child has completed the entire feed, he is placed supine on the camera and an image is recorded to establish whether there was aspiration during swallowing. This is followed immediately by

a reflux search conducted for 30 minutes - 1 hour, depending on the institutional protocol. Using this method of investigation, reflux disease can be evaluated according to the frequency, volume, height and duration of refluxes.

Part four: Images are recorded at the end of the reflux study and again 2 hours after the feed as a screening test to assess gastric emptying and to check for aspiration that could have occurred owing to reflux.

Meckel's scans

Meckel's diverticuli that contain gastric mucosa lead to repeated gastrointestinal bleeds. These bleeds usually present early in life.^[6] Tc-99m pertechnetate is taken up by normal gastric mucosa. The patient is injected with pertechnetate and dynamic images are recorded, usually for about an hour. If there is functional gastric mucosa in a Meckel's diverticulum, uptake is seen in the diverticulum at approximately the same time as the stomach mucosa is visualised. This scan will not detect diverticuli that do not contain functioning gastric mucosa.

Bone scans

In children older than 6 weeks, bone scans are extremely useful in determining the site(s) of osteomyelitis and septic arthritis.

Liver scans

Children with prolonged neonatal hepatitis should be investigated urgently, as the outcome of a Kasai procedure for biliary atresia is poorer in older babies.^[7] In patients with jaundice, the radiopharmaceutical of choice is Tc-99m mebrofenin. If activity is seen passing from the biliary tree into the gut, biliary atresia can be ruled out. However, the absence of excretion does not confirm the diagnosis of biliary atresia but prompts further, more invasive, investigations.

Fever of unknown origin

The combination of information on areas of increased metabolic activity with anatomical localisation makes F-18 FDG-PET/CT an excellent tool for investigating fever of unknown origin.

Conclusion

This is a very short, selective summary of how nuclear medicine can contribute to the field of child health. Studies specific to more specialised

areas, such as oncology of paediatrics, have not been addressed in this article.

Acknowledgement. I would like to thank Professor Mike Mann for critical feedback with regard to this brief overview.

References

1. Park SM, Chatterjee VK. Genetics of congenital hypothyroidism. *J Med Genet* 2005;42(5):379-389. [http://dx.doi.org/10.1136/jmg.2004.024158]
2. Onen A, Jayanthi VR, Koff SA. Long-term follow-up of prenatally detected severe bilateral newborn hydronephrosis initially managed nonoperatively. *J Urol* 2002;168(3):1118-1120. [http://dx.doi.org/10.1016/S0022-5347(05)64604-6]
3. Ulman I, Jayanthi VR, Koff SA. The long-term follow-up of newborns with severe unilateral hydronephrosis initially treated nonoperatively. *J Urol* 2000;164(3):1101-1105. [http://dx.doi.org/10.1016/S0022-5347(05)67262-X]
4. Koff SA. Problematic ureteropelvic junction obstruction. *J Urol* 1987;138(2):390.
5. Tullus K. What do the latest guidelines tell us about UTIs in children under two years of age? *Pediatr Nephrol* 2012;27:509-511. [http://dx.doi.org/10.1007/s00467-011-2077-5]
6. Menezes M, Tareen F, Saeed A, Khan N, Puri P. Symptomatic Meckel's diverticulum in children: A 16 year review. *Pediatr Surg Int* 2008;24:575-577. [http://dx.doi.org/10.1007/s00383-007-2094-4]
7. Pakarinen MP, Rintala RJ. Surgery of biliary atresia. *Scand J Surg* 2011;100(1):49-53.