

# Astute and safe use of topical ocular corticosteroids in general practice: Practical guidelines

*Corticosteroids are an effective treatment for ocular inflammation, but they must be used with caution.*

**E Janse van Rensburg**,<sup>1</sup> MB ChB, Dip Ophth (SA);

**D Meyer**,<sup>2</sup> MB ChB, FCFP (SA), BScHons Pharm, MMed (Ophth), FCOphth (SA), PhD

<sup>1</sup>Registrar, Division of Ophthalmology, Faculty of Medicine and Health Sciences, University of Stellenbosch, South Africa

<sup>2</sup>Professor and Head, Division of Ophthalmology, Faculty of Medicine and Health Sciences, University of Stellenbosch, South Africa

Corresponding author: E Janse van Rensburg (ernstjvr@yahoo.com)

Corticosteroids are the most effective way to treat ocular inflammation. They relieve symptoms rapidly and often prevent permanent damage. These medications, however, must be used with caution, as use of steroid-containing topical drops can lead to serious side-effects. In situations where

resources are limited it is often difficult to decide if steroids can be given safely. The purpose of this article is to briefly review the most important features of topical steroids and provide a practical and safe guideline for their use in general practice (Fig. 1 and Table 1).

## Mechanism of action

Topical steroids act locally and achieve their anti-inflammatory and immunosuppressive effects through a combination of pathways. The most important anti-inflammatory effect may be the inhibition of arachidonic acid release, preventing the liberation of prostaglandins and other potent inflammatory mediators. The immunosuppressive effects include decreasing the number and functionality of leucocytes. Steroids also prevent late inflammatory responses, such as capillary and fibroblast proliferation, collagen deposition and scarring.

**Well-known complications of topical steroids include the formation of a geographic ulcer if given in the presence of a dendritic herpetic ulcer, cataract formation and increased intra-ocular pressure.**

## Common indications

Severe allergic keratoconjunctivitis (the main indication in general practice), adenoviral keratoconjunctivitis, uveitis, episcleritis, scleritis, corneal graft rejection, immunogenic keratitis and uveitis.<sup>[1,2]</sup>

## Side-effects

Well-known complications of topical steroids include the formation of a geographic ulcer if given in the presence of a dendritic herpetic ulcer, cataract formation and increased intra-

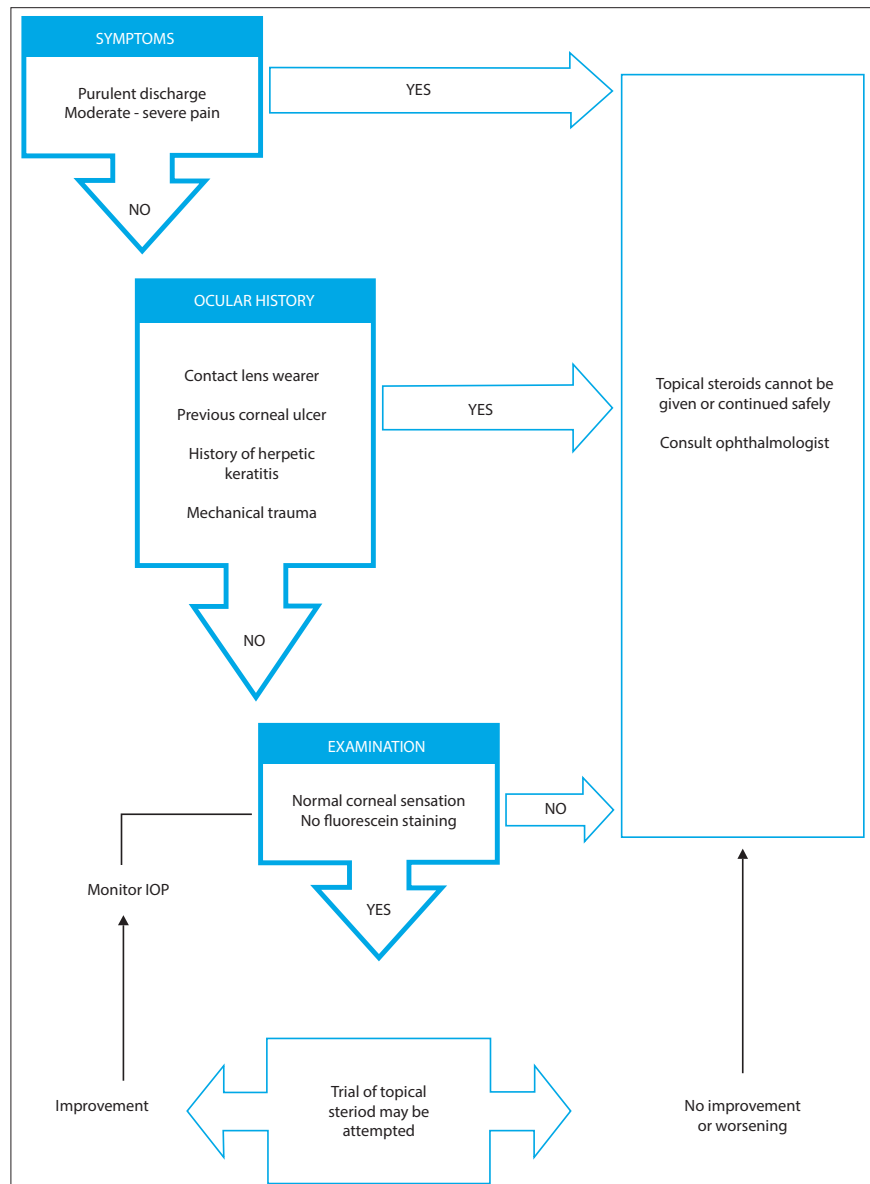


Fig. 1. Guide to prescribing topical steroids in ophthalmic disorders.

## Topical ocular corticosteroids

Table 1. Topical steroid formulations available in South Africa<sup>[3,6,7]</sup>

Drugs in order of increasing potency	Trade name	Steroid half-life (hrs)	Potency compared with hydrocortisone	Side-effect	Indications
<b>Single preparations</b>					
Prednisolone acetate 0.12%	Pred-Mild	18 - 36	4	Worsening of external infection	Allergic keratoconjunctivitis, inflamed pterygium, inflammatory causes of dry eyes, episcleritis
Fluoromethalone 0.1%	FML Liquifilm Flucon	NA	21		
Betamethasone 0.1%	Betnesol	36 - 54	25	Cataracts, IOP elevation, corneo-scleral thinning and perforation	Uveitis, corneal graft rejection, immunogenic keratitis, scleritis
Dexamethasone phosphate 0.1%	Maxidex Spersadex	36 - 54	30		
Prednisolone acetate 1%	Pred Forte	18 - 36	40		
<b>Combined preparations</b>					
Betamethasone, neomycin	Betnesol N	36 - 54			
Dexamethasone, chloramphenicol	Covomycin D	36 - 54			
Fluoromethalone, neomycin	FML-Neo			Masks hypersensitivity	Postoperative prophylaxis, e.g. post cataract surgery
Dexamethasone, neomycin, polymyxin B	Maxitrol	36 - 54			
Dexamethasone, framycetin, gramicidin	Sofradex	36 - 54		Bacterial resistance	
Dexamethasone, chloramphenicol	Spersadex Comp	36 - 54			
Hydrocortisone, oxytetracycline, polymyxin B	Terra-Cortril	8 - 12			
Dexamethasone, tobramycin	Tobradex	36 - 54			

ocular pressure (IOP). The increase in IOP can occur after only 1 week of treatment – 30% of the population will develop a moderate rise, while 4 - 5% will have a marked increase in IOP. This response can occur during any stage of treatment, and is more pronounced in children if the patient already has glaucoma, diabetes or high myopia. Regular IOP monitoring is needed to prevent damage to the optic nerve.<sup>[1,3,4]</sup>

### Topical steroids should only be prescribed if the benefit outweighs the risks.

Topical steroids increase the risk of corneal infections due to suppression of the host's response. This may lead to new infections, exacerbate existing infections, reactivate dormant infections and mask less obvious chronic infections, leading to delayed presentation of potentially blinding conditions.<sup>[1]</sup> Common conditions potentiated by steroid therapy without appropriate cover include viral (herpetic),

bacterial (notably *Pseudomonas aeruginosa*, which is often contact-lens associated) and fungal keratitis. Other adverse effects include delayed wound healing, mydriasis, aponeurotic ptosis and peri-ocular dermatitis. In the presence of an underlying connective tissue disease which predisposes to corneal or scleral thinning, ocular perforation may occur.<sup>[1,4-6]</sup>

#### Potency

Most side-effects of topical steroids are related to the specific corticosteroid's potency, duration of action and ability to penetrate the globe. Formulations with acetates are more lipophilic and penetrate through the cornea better than those formulated with phosphates, which are relatively hydrophilic.<sup>[6]</sup> If hydrocortisone has a relative effect of a factor 1, then betamethasone, dexamethasone and tri- amcinolone respectively have a 25, 30 and 35 times more potent anti-inflammatory effect.<sup>[6]</sup>

#### Prescribing

Topical steroids should only be prescribed if the benefit outweighs the risks. In severe allergic keratoconjunctivitis, fluoromethalone alcohol suspension (0.1 - 0.25%) can be used with relative impunity.

It has a potent anti-inflammatory effect on the ocular surface, but rapid metabolism of the compound within the eye decreases the intra-ocular potency and intra-ocular side-effects.<sup>[1]</sup> It has been found to be almost as effective in ocular surface inflammatory conditions as dexamethasone or prednisolone acetate 0.125%, while having the distinct advantage of a lower incidence of steroid-induced glaucoma. The risk of corneal ulcers, however, remains unchanged.<sup>[7]</sup> Medrysone 1% may also be used in ocular surface inflammation. It penetrates the globe poorly and is even less likely to cause steroid glaucoma.<sup>[5]</sup>

Dexamethasone 0.1% is considered a potent steroid. It penetrates the cornea more readily and has a long half-life in ocular tissues. It is therefore more suitable for reaching deeper ocular tissues (as is needed in uveitis), but has a higher risk of significant IOP elevation and cataract formation compared with fluoromethalone 0.1%.<sup>[1,6]</sup> Dexamethasone is often contained in combination antibiotic/steroid preparations. These combinations are indicated for use in the postoperative period (i.e. after cataract surgery), and are not registered for empirical use in blepharitis or conjunctivitis of unknown cause.<sup>[7]</sup>

Acute adenoviral follicular conjunctivitis ('pink eye') is very common in primary practice. Most clinicians would withhold topical steroids except in severe cases provided there is no evidence of corneal involvement. Recent evidence now supports the use of topical

dexamethasone 0.1% 4 times a day for 1 week in acute follicular conjunctivitis presumed to be viral in origin.<sup>[9]</sup>

**In situations where resources are limited it is often difficult to decide if steroids can be given safely.**

Prednisolone acetate 1% suspension (i.e. Pred Forte) exhibits the greatest anti-inflammatory activity of all the corticosteroids on the anterior segment of the eye.<sup>[1,3]</sup> It therefore has a high risk of steroid-related complications (Table 1).

Loteprednol etabonate and rimexolone are new-generation synthetic steroids, specifically designed to minimise some of the adverse effects of topical steroids. IOP elevation has been reported but is rare, even in known steroid responders. Current data also suggest decreased potential for cataract formation.<sup>[1,2]</sup> These drugs are currently marketed for temporary use in allergic keratoconjunctivitis.

### Conclusion

Family practitioners may safely prescribe topical steroids, provided they have acquired the skill to assess and monitor the side-effects of topical steroids (Fig. 1).

### References

1. Shalam, KV. Ocular pharmacotherapeutics. In: American Academy of Ophthalmology, Basic and Clinical Science Course. 2010-2011. Fundamentals and principles of ophthalmology, p.358.
2. Comstock TL, DeCorey HH. Advances in corticosteroid therapy for ocular inflammation: Loteprednol Etabonate. *Int J Inflamm* 2012. Article ID 789623, 11 pages, 2012. [<http://dx.doi.org/10.1155/2012/789623>]
3. Kwok AK, Lam DS, NG JS, Chew SJ, Tso MO. Ocular-hypertensive response to topical steroids in children. *Ophthalmology* 1997;104:2112-2116.
4. Ahmed M, Stephen Foster C. Steroid therapy for ocular inflammatory disease. *Focal Points: Clinical Modules for Ophthalmologists* 2006;24(7):1-7.
5. Meyer D. The judicious use of topical corticosteroids in eye conditions. *SA Family Practice* 2004;46(9):4.
6. Jones R, Rhee DJ. Corticosteroid-induced ocular hypertension and glaucoma: a brief review and update of the literature. *Curr Opin Ophthalmol* 2006;17:163-167.
7. Division of Pharmacology, University of Cape Town. *South African Medicines Formulary*, 9th ed. Cape Town: HMPG, 2010, 258.
8. American Academy of Ophthalmology. Clinical approach to uveitis. In: *Basic and Clinical Science Course* 201-2012, p.101.
9. Wilkins MR, Khan S, Bunce C, Khawaja A, Siriwardena D, Larkin DFP. A randomized placebo-controlled trial of topical steroids in presumed viral conjunctivitis. *Br J Ophthalmology* 2011;95:1299-1303. [<http://dx.doi.org/10.1136/bjo.2010.188623>]
10. Rhee DJ, Colby KA. Steroidal anti-inflammatory drugs. In: Rhee DJ. *Ophthalmic Drug Guide*. London: Springer Verlag, 2009:74.

## SUMMARY

- Before prescribing topical steroids:
- Take an adequate clinical history.
- Exclude the following three high-risk situations:
  - Glaucoma – by measuring the intra-ocular pressure with a Schiottz or other tonometer; minimally assess the IOP digitally
  - Cataract – by performing a red reflex test
  - Herpes simplex or fungal keratitis – by staining the corneal surface with fluorescein and examining it with a cobalt blue light using the +10 magnification (now standard on direct ophthalmoscopes)
- Monitor the IOP if treatment exceeds 2 weeks.
- Ideally have access to a slit-lamp.
- Follow the guidelines to prescribing topical steroids in ophthalmic disorders.