

Practical regional anaesthesia

There are significant advantages to regional anaesthesia.

C HAMMERSCHLAG, BSc (Medical Biochemistry), MB BCh, FCA (SA)
Head, Regional Anaesthesia, Chris Hani Baragwanath Hospital, Johannesburg

Dr Hammerschlag began a formal registrar training programme in regional anaesthesia at Chris Hani Baragwanath Hospital in 2005. She is a member of RAPSA (Regional Anaesthesia and Pain Society of South Africa), and has a special interest in the teaching of regional anaesthesia (regional anaesthesia evangelist!).

Regional anaesthesia alone, or in combination with general anaesthesia, offers significant analgesic advantages. It greatly reduces postoperative pain, decreases the need for opioids, allows earlier mobilisation, enables quicker return to normal function, and decreases the incidence of chronic postoperative pain.¹

Locating nerves

Regional anaesthesia is applied anatomy. Nerves are located using anatomical landmarks, and then more precisely located using a nerve stimulator technique, which is preferred to paraesthesia elicitation: there is an unambiguous end-point (contraction of the muscle group supplied by the nerve) and a high success rate (>90%).²

Nerve stimulators are best used with insulated needles, which localise the current to the needle tip, increasing block accuracy. Initial stimulator settings include a pulse frequency of 1 - 2 Hz, a 0.1 ms pulse duration and a current strength of 1 - 2 mA. A twitch is elicited when the needle tip is within 1 - 2 cm of the nerve. As the nerve is approached the current is decreased. The current indicating that the stimulating needle is close enough to the nerve for a successful block, but not so close as to damage the nerve, is controversial. Currents of 0.3 - 0.5 mA are probably appropriate. Stimulation by currents below 0.2 mA may indicate intraneural placement of the needle. Injecting 1 ml of local anaesthetic should abolish the twitch. Failure to do so may also indicate intraneural or intravascular positioning of the needle. Other indicators of intraneural placement are severe pain on injection and abnormal resistance to injection.³ In all these scenarios the needle should be re-positioned.

Nerves differ in sensitivity to local anaesthetics. Generally, smaller nerves are more easily blocked and take longer to recover from local anaesthetics than large myelinated fibres.

Nerve sensitivity and its implications

Nerves differ in sensitivity to local anaesthetics. Generally, smaller nerves are more easily blocked and take longer to recover from local anaesthetics than large myelinated fibres. The order of sensitivity from most to least sensitive is: B (pre-ganglionic sympathetic) > C and A-delta (pain and temperature) > A-gamma (muscle spindles) > A-alpha (motor) > A-beta (pressure).⁴ Differential sensitivity

Regional anaesthesia is applied anatomy.

has two important consequences. Firstly, autonomic fibres are always blocked, regardless of the concentration of the solution. The level of sympathectomy is usually 2 segments above the sensory level, which is 1 - 2 segments above the motor level. Autonomic block, especially at high levels, can cause profound hypotension. The converse is that even when concentrated solutions are used, pressure and vibration sense may not be blocked. This *must* be explained to the patient before block placement, otherwise he/she will interpret these sensations as pain.

The position of the nerve within the nerve bundle is also important. Nerves that are deeper in the bundle take longer to block. In peripheral nerves the motor fibres are often on the bundle periphery and are blocked before sensory nerves, despite their larger size. In peripheral nerve blocks loss of motor function may not always imply sensation loss. Sensation must be specifically evaluated and sufficient time allowed for local anaesthetic penetration of the whole nerve bundle.

Because sensory fibres are more sensitive to local anaesthetics than motor fibres it is possible to block pain fibres selectively, without affecting motor fibres, by using dilute concentrations of local anaesthetic. This is used in 'walking epidurals', but is also true in the case of peripheral nerve blocks: dilute concentrations can be given via indwelling peripheral nerve catheters, allowing patients to mobilise and painlessly undergo physiotherapy and rehabilitation.⁵

Doses

Individualise doses according to the patient's physiology and block site. Toxicity correlates with free peak plasma concentrations, which are dependent on dose, absorption, protein binding, and drug metabolism. Absorption speed varies with site of local anaesthetic injection - from fastest to slowest: intravenous > intercostal > intrapleural > paracervical > paravertebral > epidural > plexus blocks > > spinal > skin infiltration. When blocking areas with rapid absorption the lowest effective dose of local anaesthetic should be used. Toxicity may manifest immediately (with accidental intravenous injection), or 30 - 40 min later, as the local anaesthetic is absorbed. Patients should be monitored for toxicity for at least 40 min after block placement. Certain individuals are more sensitive to drug toxicity, including elderly patients, debilitated patients, patients with cardiac abnormalities, and those in liver failure. Doses must be reduced in these cases.

Local anaesthetic toxicities *are* additive. Mixing lignocaine with long-acting agents reduces block onset by about 5 min, but shortens block duration significantly.

Table I. Recommended concentration of local anaesthetic agents

Drug	Maximum dose ⁶⁻⁸	Maximum with adrenaline ⁶⁻⁸	Relative potency	Lowest neuraxial concentration	
				Motor block ⁹⁻¹¹	Sensory block ⁹⁻¹¹
Bupivacaine	2 - 3 mg/kg	2 - 3 mg/kg	4	0.26%	0.1%
Levobupivacaine	2 - 3 mg/kg	2 - 3 mg/kg	3.7	0.3%	0.12%
Ropivacaine	3 mg/kg	3 mg/kg	2	0.3%	0.2%
Lignocaine	3 - 4.5 mg/kg	7 mg/kg	1		

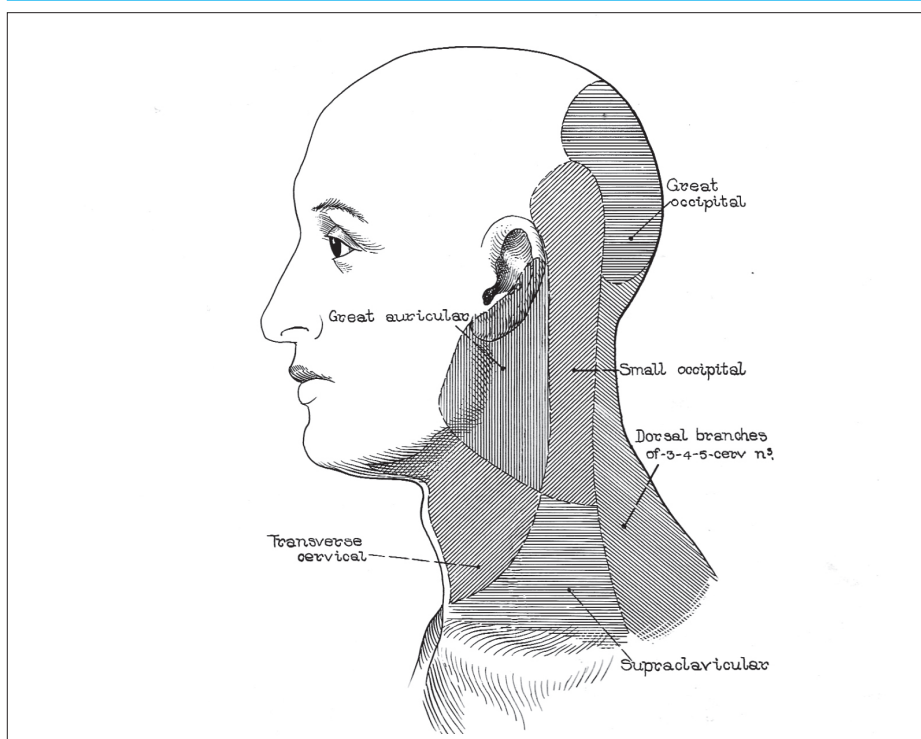


Fig. 1(a). Cutaneous distribution of the nerves at the deep and superficial cervical plexus.

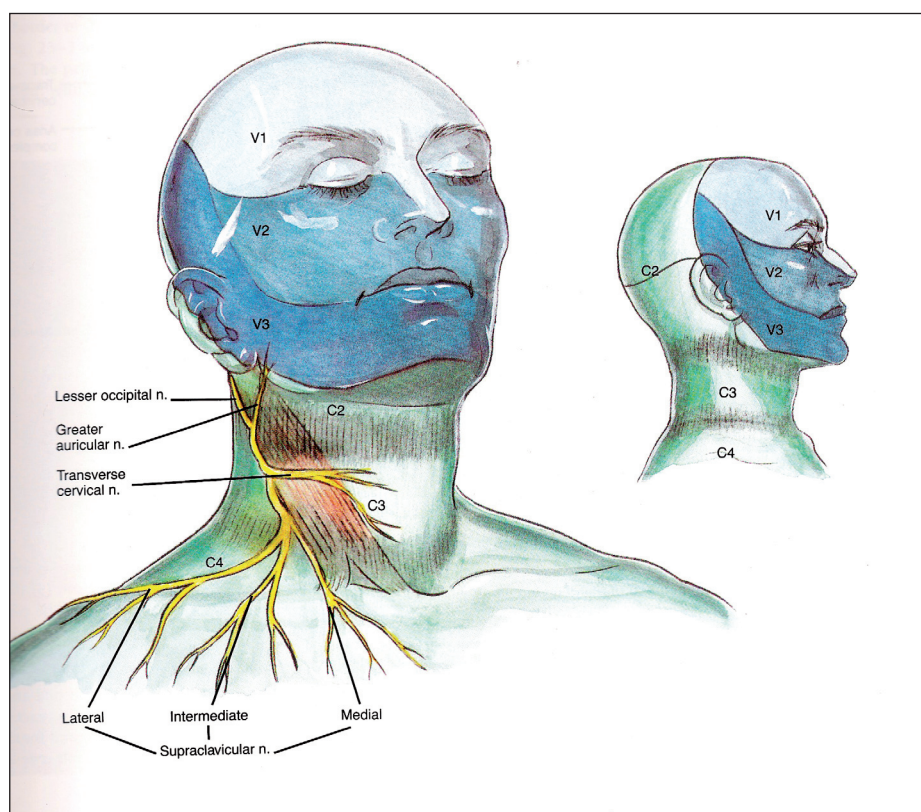


Fig. 1(b). Cutaneous distribution of the superficial cervical plexus.

Central nervous system toxicity usually precedes cardiovascular toxicity: patients become restless and anxious, they have circumoral numbness or tingling, tinnitus and diplopia.

Toxicity

Central nervous system toxicity usually precedes cardiovascular toxicity: patients become restless and anxious, they have circumoral numbness or tingling, tinnitus and diplopia. Higher plasma levels result in convulsions and coma. Cardiovascular toxicity manifests as atrioventricular (AV) block, bradyarrhythmias, asystole, ventricular fibrillation, hypotension, and ultimately cardiac arrest.

Management of the patient is by discontinuing the injection, giving oxygen, and resuscitating according to ACLS protocols. Continue resuscitation for over 1 hour in cases of long-acting local anaesthetic toxicity. Treat seizures with benzodiazepines, thiopentone or small doses of propofol.

Intralipid 20% (Fresenius Kabi) reverses local anaesthetic toxicity. It is given as a bolus of 1.5 ml/kg over 1 min (i.e. 100 ml in a 70 kg patient), followed by an infusion of 0.25 ml/kg/min (400 ml over 20 min). The bolus can be repeated twice at 5-min intervals if circulation has not been restored. It is recommended that Intralipid be available wherever regional anaesthesia is practised.¹²⁻¹⁴ Propofol is *not* an acceptable alternative – it has myocardial-depressant effects and inadequate lipid content. Insulin-glucose-potassium infusions may be useful.¹⁵

Some useful blocks

Superficial cervical block

The superficial cervical plexus is formed from ventral roots of C2 - C4. The nerves emerge from behind the mid-point of the posterior border of the sternocleidomastoid to supply sensation, as shown in Fig. 1.¹⁶ The block is a useful analgesic adjuvant for procedures performed on the neck, e.g. Hickman line placement, tracheotomy, thyroidectomy (bilateral blocks), and on the posterior third of the ear. Local anaesthetic (10 - 15 ml) is

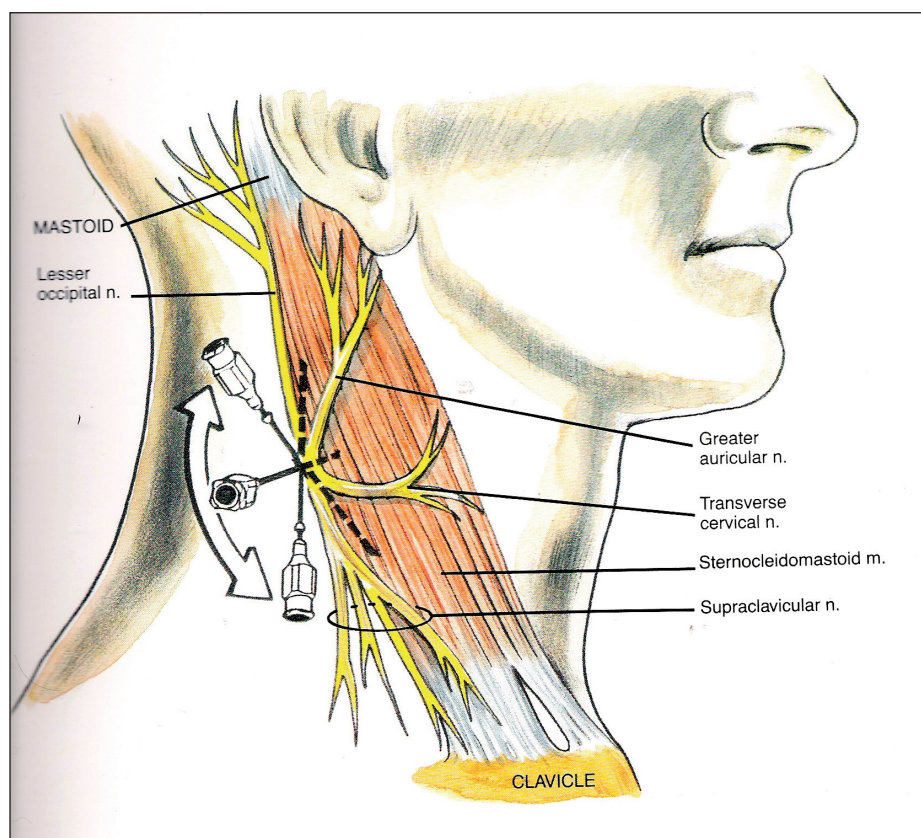


Fig. 2. Superficial cervical plexus block – anatomy and technique.

injected midway up and down the posterior border of the sternocleidomastoid, just below the fascia (Fig. 2).¹⁷ Beware of the external jugular vein which crosses the sternocleidomastoid at this point!

Coracoid block

This blocks the brachial plexus at cord level, avoids the neurovascular structures of the neck, has minimal risk of pneumothorax, and provides analgesia for surgery below the shoulder. The axillary, musculocutaneous, antibrachial and brachial cutaneous nerves, often missed by axillary blocks, are usually included by the coracoid approach. Remember that the skin on the inner aspect of the arm is supplied by the intercostobrachial nerve, T2, which is outside the brachial plexus. For surgery, e.g. the creation of AV fistulas, this nerve must be blocked separately via a subcutaneous wheal from the insertion of the pectoralis major muscle to the long head of the triceps. From the medial border of the coracoid process measure 2 of the patient's fingerbreadths medially and 2 inferiorly onto the upper border of the pectoralis minor muscle in the delto-pectoral groove. The groove is identified by marking the line between the subclavian pulse in the neck and the axillary artery pulse. The plexus lies beneath the pectoralis muscles, the thickness of which is palpated when the axillary pulse is felt, indicating the depth at which the plexus lies. Abduction of the arm to 45°, with the hand on the abdomen, makes palpation of the upper border of the pectoralis minor muscle easier, but it is not essential. The

block is feasible without moving the arm. The needle must be inserted perpendicular to the skin. The first nerve stimulated is usually the musculocutaneous nerve. Local anaesthetic (5 - 10 ml) is administered to block this nerve before re-positioning the needle slightly more caudad to stimulate the lateral cord (median nerve). The success of the block is improved by a multiple stimulation technique (volume 30 - 40 ml) (Fig. 3).¹⁸

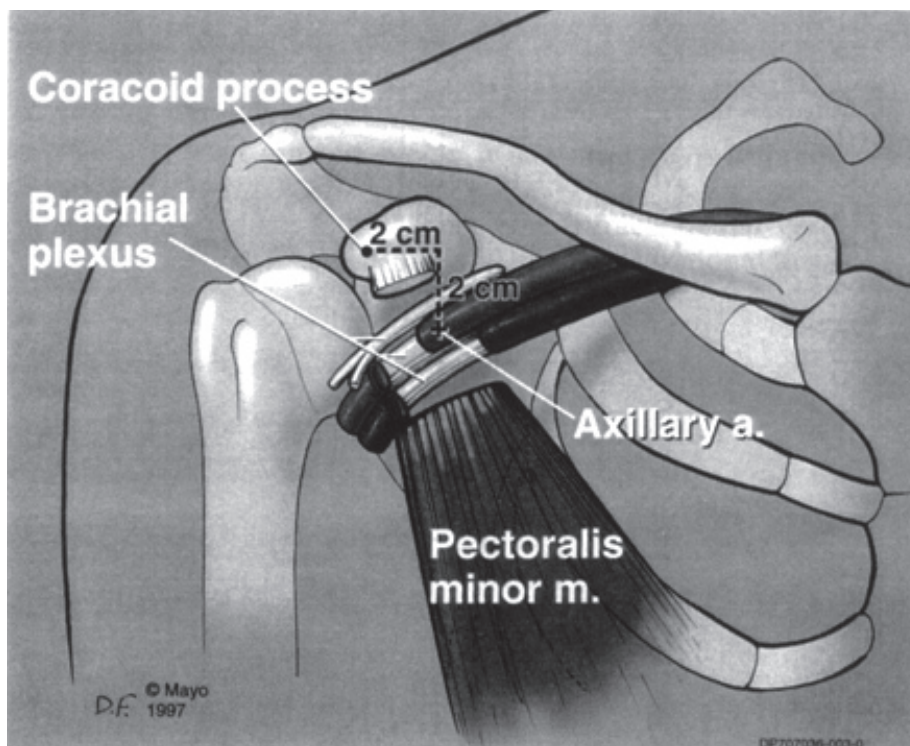


Fig. 3. Anatomy of coracoid block.

Axillary block

This is a block of brachial plexus branches. Abduct the arm to 90°, palpate the brachial artery in the axilla, and insert the needle at 30° to the skin, parallel to the artery. Anterior and posterior branches should be sought. Relative to the artery, the median nerve is above and anterior, the ulnar nerve is anterior and below, and the radial nerve is posterior. The musculocutaneous nerve is within the body of the coracobrachialis. If the axillary artery is inadvertently punctured the needle should be directed through the artery, and half of the local anaesthetic should be placed behind the artery before withdrawing the needle and placing the other half in front of the artery. Aspirate every 3 ml to avoid intravascular injection. Puncture of the artery should not be specifically sought (toxicity will be increased) (Figs 4 and 5).

Bier's blocks

These are suitable for soft-tissue and distal orthopaedic arm surgery. Their major attraction is technical ease, requiring only venous cannulation and an intact venous system. The limb to be blocked is exsanguinated with an Esmarch bandage or with elevation for 4 - 5 min. A tourniquet is then inflated to 50 mmHg above systolic pressure. A double tourniquet technique is preferable, the most proximal tourniquet being inflated first. Forty to fifty millilitres of 0.5% (=5 mg/ml) lignocaine (maximum 3 mg/kg) without vasoconstrictors are injected slowly. Five minutes later the distal tourniquet is inflated and the proximal one deflated. The area under the tourniquet will now be anaesthetised and tourniquet tolerance will be improved. Block onset

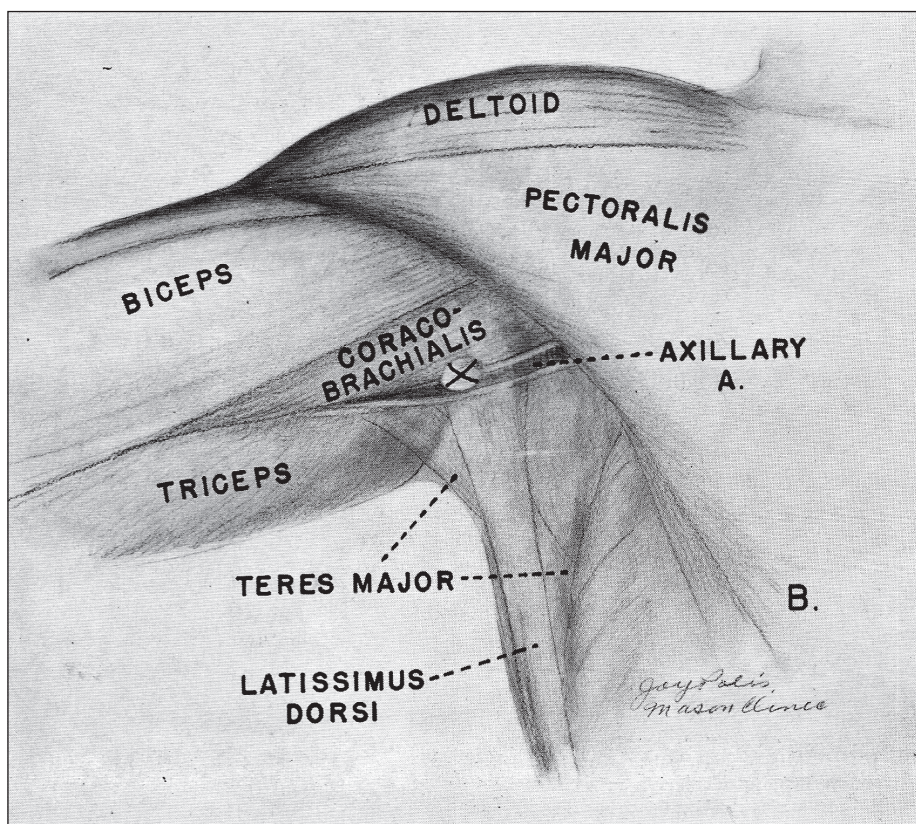


Fig. 4. Axillary block anatomy.

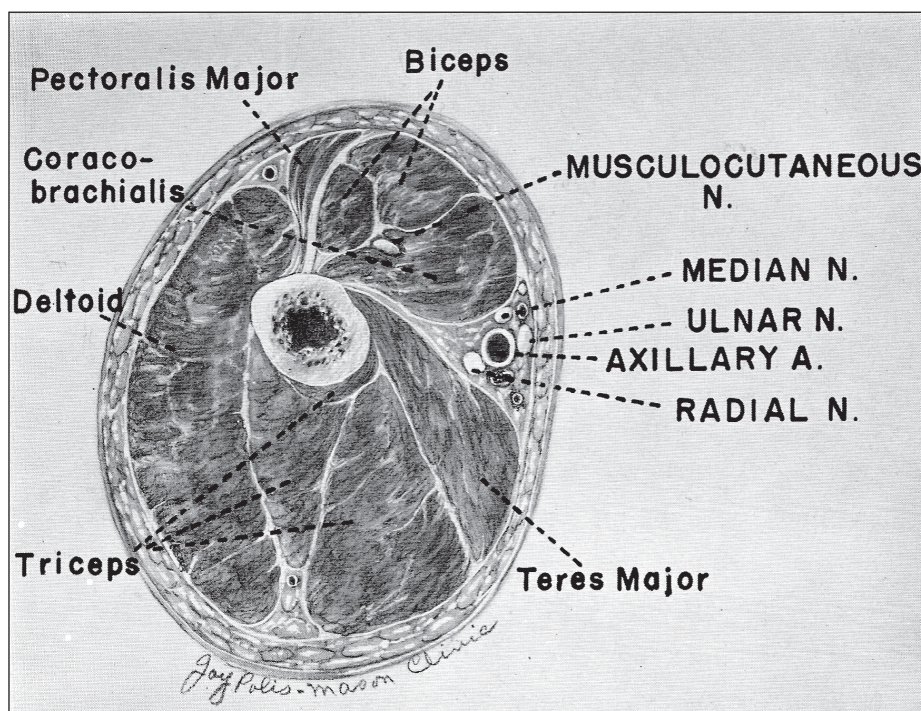


Fig. 5. Cross-sectional anatomy of the upper arm at approximately the point where the axillary block is executed. Note position of musculocutaneous nerve.

is 10 min. The lignocaine probably blocks nerves running parallel to the veins, or may diffuse to the nerve branches in the tissues. Tourniquet pain usually limits block duration to 45 - 60 min. Tourniquet integrity is imperative: if a reliable tourniquet is not available the block should not be performed. Toxicity is a serious problem if the tourniquet leaks. It must remain inflated for at least 30 min after lignocaine injection so that the local anaesthetic has time to bind to tissues. Premature deflation leads to severe toxicity.

The block must not be performed with bupivacaine, levobupivacaine or ropivacaine because of the risk of toxicity. The block dissipates within 15 min of tourniquet deflation. There is no postoperative analgesia; therefore the block is inappropriate if intense postoperative pain is expected. Systemic venous access must be established in the non-blocked arm, and one must monitor carefully for toxicity (reported incidence 2 - 10%). Plexus blocks and nerve blocks are probably safer than Bier's blocks.

Lower limb blocks

The leg is supplied by the lumbar and sacral plexuses. Both plexuses must be blocked for leg surgery. The simplest method of blocking the lower limb is neuraxially, via spinal or epidural anaesthetic. Unilateral spinal anaesthesia is possible if small doses (3 - 5 mg) heavy spinal bupivacaine are injected slowly in the lateral decubitus position, with the operative side dependent, and the block is allowed to 'take' for 30 min before supine positioning. This causes less haemodynamic change than a bilateral spinal block.¹⁹

Femoral block

This is useful as an analgesic adjunct for fractured femurs, for transporting the patient, and to allow the patient to sit in order to place a spinal anaesthetic. The nerve is 1 - 2 cm lateral to the femoral artery at a depth of 2 - 4 cm. Nerve stimulation results in quadriceps contraction (Fig. 6).

Fascia iliaca block

This safe block requires no specialised equipment and has no risk of nerve injury. Local anaesthetic spreads below the fascia to block the femoral and lateral femoral cutaneous nerves. A line, representing the inguinal ligament, is drawn from the anterior superior iliac spine to the pubic tubercle, and divided into thirds. One centimetre below the ligament at the junction of the outer and middle thirds, the skin is cut with a sharp needle, and then a blunt pencil-point spinal needle is used so that the resistance of the fasciae can be appreciated. Loss of resistance is felt as the needle pierces the fascia - first from the needle passing the fascia lata, and then as the needle traverses the fascia iliaca. Local anaesthetic (10 ml) is injected below the fascia lata, and 20 - 30 ml is injected below the fascia iliaca. (Search for fascia iliaca block on 'Youtube' for a video demonstration.)

Resources

The most valuable resource is a good anatomy textbook! There are several excellent websites with detailed descriptions of regional anaesthetic blocks, including The New York School of Regional Anaesthesia site (www.NYSORA.com), the European Society of Regional Anaesthesia site (www.esra-learning.com), and the Ulm Rehabilitation Hospital site (www.nerveblocks.net).

References

1. Boezaart A. *Anaesthesia and Orthopaedic Surgery*. McGraw-Hill, 2006.
2. Hadzic A. Peripheral nerve stimulators - cracking the code. *Reg Anesth Pain Med* 2004; 29: 165-188.
3. Borgat A, Blumenthal S. Nerve injury and regional anaesthesia. *Current Opinion in Anaesthesiology* 2004; 17: 417-421.

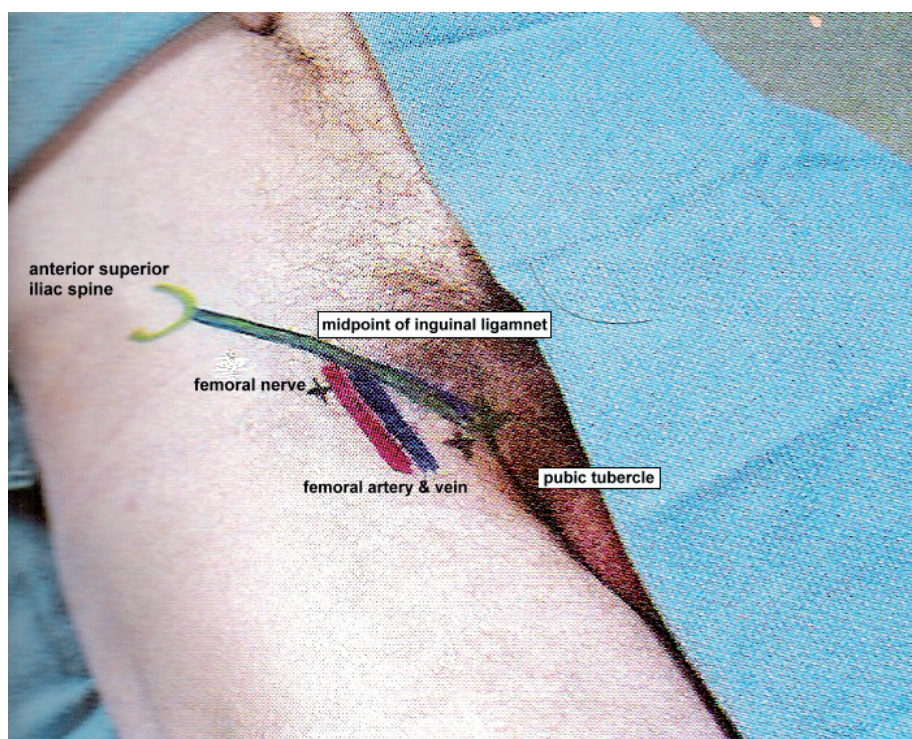


Fig. 6. Femoral nerve block – landmarks.

4. Stevens RA, Bray JG, Artuso JD, *et al.* Differential epidural blockade. *Regional Anesthesia* 1992; 17: 22-25.
5. Grossi P, Allegri M. Continuous peripheral nerve blocks: state of the art. *Current Opinion in Anaesthesiology* 2005; 18: 522-526.
6. Heavner J. Local anesthetics. *Current Opinion in Anaesthesiology* 2007; 20: 336-342.
7. Rosenberg PH, Veering B, Urmey WF. Maximum recommended doses of local

anaesthetics: A multifactorial concept. *Reg Anesth Pain Med* 2004; 29(6): 564-575.

8. Moggan GE, Mikhail MS. *Clinical Anesthesiology*. McGraw-Hill, 2005.
9. Lacassie HJ, Habib AS, Lacassie HB, Columb MO. Motor blocking minimal local anesthetic concentrations of bupivacaine, levobupivacaine, and ropivacaine and in labour. *Reg Anesth Pain Med* 2007; 32(4): 323-329.

10. Van de Velde M, Drelinck R, Dubois J, *et al.* Determination of the full dose-response relation of intrathecal bupivacaine, levobupivacaine, and ropivacaine, combined with sufentanil, for labour analgesia. *Anesthesiology* 2007; 106: 149-156.
11. Mather LE, Chang D. Cardiotoxicity with modern local anesthetics. Is there a safer choice? *Drugs* 2001; 61(3): 333-342.
12. Weinburg G. Lipid rescue resuscitation from local anesthetic toxicity. *Toxicology Review* 2006; 25(3): 139-145.
13. Picard J, Meek T. Lipid emulsion to treat overdose of local anesthetic – the gift of the glob. *Anaesthesia* 2006; 61(8): 107-109.
14. Corman SL, Skelder SJ. Use of lipid emulsion to treat local anaesthetic toxicity. *Annals of Pharmacology* 2007; 41(11): 1873-1877.
15. Kim JT, Jung CW, Lee KH. The effect of insulin on the resuscitation of bupivacaine induced severe cardiovascular toxicity in dogs. *Anesth Analg* 2004; 99: 728-733.
16. Adriani J. *Labat's Regional Anesthesia. Techniques and Clinical Applications*. WB Saunders, 1967.
17. Brown DL. *Atlas of Regional Anesthesia*. WB Saunders, 1992.
18. Wilson J, Brown D, Wong G, *et al.* Infraclavicular brachial plexus block: Parasagittal anatomy important to the coracoid technique. *Anesth Analg* 1998; 87(4): 870.
19. Casati A, Fanelli G, Aloegheri G, *et al.* Frequency of hypotension during conventional and asymmetric hyperbaric spinal block. *Reg Anesth Pain Med* 1999; 24 (3): 214-219.

In a nutshell

- Regional anaesthesia, from plexus blocks to skin infiltration, can be used to provide analgesia for most surgery.
- Cognisance must be taken of the following when choosing the dose of local anaesthetic agent:
 - potency and toxicity of the drugs
 - the site of injection
 - the volume needed for the block
 - the desired characteristics of the block (motor or sensory block)
 - the patient's physiology.