

MORE ABOUT....CURRENT CONCEPTS IN CARDIOLOGY

ROLE OF ECHO-CARDIOGRAPHY IN CARDIAC ASSESSMENT

EDMUND BRICE, MB ChB, PhD, FCP (SA)

Cardiologist, Tygerberg Academic Hospital, Parow Valley

Echocardiography has revolutionised the assessment of the cardiac patient, allowing more definitive evaluation of cardiac structure and function. Unfortunately, reliance on this new technology has often replaced careful clinical assessment. Consequently, uncritical appraisal of echocardiographic data, often by insufficiently experienced practitioners, can give rise to erroneous conclusions, occasionally with severe consequences for the patient. In this brief contribution I will attempt to cover a few of the common indications for echocardiographic assessment and highlight the potential pitfalls for the unwary.

Left ventricular function

Perhaps the commonest request for echocardiographic assessment is to define left ventricular function. The technique most often used is to place the M-mode across the base of the heart. This allows measurement of the thickening and movement of the basal free wall and interventricular septum of the left ventricle (LV). It is important that the M-mode interrogation line is perpendicular to the LV walls, as off-axis assessment will give rise to errors. It must also be realised that this measurement only focuses on the basal part of the LV. Regional wall motion abnormalities, for example a large anteroseptal myocardial infarction, will lead to reporting of a falsely elevated

LV function. In bundle branch block, or following myocardial infarction, paradoxical septal motion can be seen (i.e. the free and septal walls do not move towards each other in systole). In such a case, any attempt to assess LV function using the M-mode method would be wrong. A more accurate, and time-consuming, method to assess LV function (which overcomes many of the aforementioned problems) is the volumetric method. This works well if the LV endocardial border can be defined and traced in both a 4-chamber and 2-chamber view and the echocardiography machine's software will calculate an ejection fraction.

Aortic stenosis

An echocardiogram is often requested in suspected aortic stenosis. Continuous wave Doppler positioned across the aortic valve (AV) allows measurement of systolic peak velocity and the peak and mean gradients between the LV and aorta. Care must be taken to find the best transducer position (often the 'blind' continuous wave probe is useful) as off-axis assessment of the flow will tend to underestimate stenosis severity. Sometimes the best interrogation view is found from the sub-xiphoid, right chest or even the neck and one should not slavishly only assess from the apex, especially if the Doppler profile obtained from this position is suboptimal. Remember that the gradients across the AV are affected by LV function and that aortic stenosis severity will be underestimated with conventional Doppler assessment. To resolve this, assessment of valve area can be made using the continuity equation. Hence, by measuring pulse wave Doppler velocity on either side of the AV, and combining this with a measurement on the LV outflow tract diameter, the echocardiography machine's software will calculate an AV valve area. This result

should be reliable even in the face of poor LV function.

Pericardial effusions

Pericardial effusions and the need for pericardiocentesis is another source of requests for echocardiography. In most patients the presence of pericardial fluid can be determined relatively easily. If pleural fluid is also present, confusion as to whether a fluid collection is pleural or pericardial can result. Careful assessment of the parasternal long-axis view and the localisation of the descending aorta can help resolve this dilemma. Fluid seen anterior to the descending aorta is pericardial, pleural fluid collects posterior to the descending aorta in this view. While Doppler assessment can diagnose tamponade it must be remembered that this is a clinical diagnosis and, if significant pulsus paradoxus is present, an effusion should be drained. This is especially important in patients who have had cardiac surgery, where a small loculated pericardial effusion seen on echocardiography may cause profound and potentially life-threatening tamponade.

Endocarditis

Endocarditis can be diagnosed with the aid of echocardiography. If an independently mobile, echo-bright object is seen attached to the upstream aspect of a valve leaflet in a patient clinically suspected of having endocarditis then an echocardiogram helps clinch the diagnosis. Conversely, endocarditis cannot be excluded in a similar patient if vegetations are not seen. They may be too small to visualise on transthoracic echocardiography (and hence transoesophageal echocardiography may be required but may also fail to visualise vegetations). In such cases, clinical assessment and laboratory tests will be needed to exclude the diagnosis.

Conclusion

In these situations (and many others not covered here) training and experience is vital in order to use echocardiography effectively. Echocardiography remains an adjunctive evaluation, with the data obtained being operator dependent, and requiring interpretation in conjunction with a proper clinical assessment. While training in echocardiography for

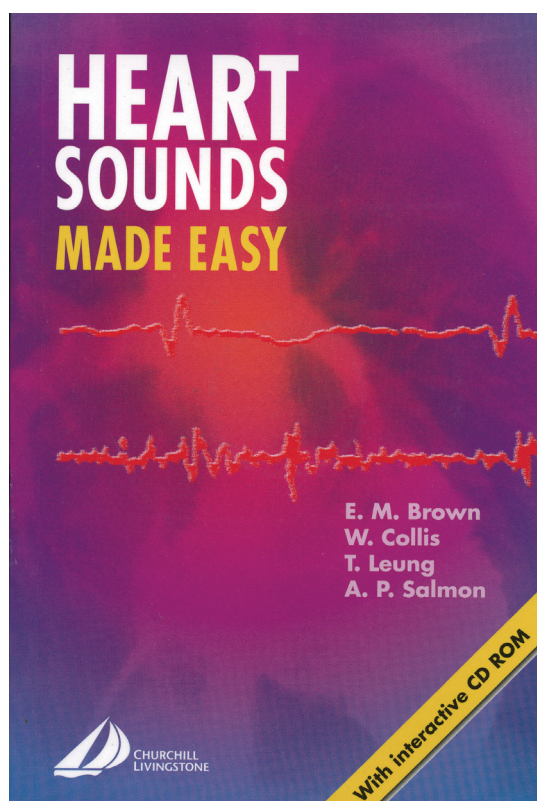
technologists and cardiologists is well established in South Africa, many medical practitioners perform studies without such a foundation. Unlike in the UK, the USA and some other countries, South Africa has no proficiency certification programme in place. Until one is available, I would urge practitioners performing echocardiograms to seek short attachments to training institutions or experienced echocardiographers to

improve their technique, increasing the reliability of their assessments for their patients' benefit.

Further reading

Oh JK, Seward JB. *The Echo Manual*. Philadelphia: Lippincott Williams & Wilkins, 1999.

Otto CM. *Textbook of Clinical Echocardiography*. Philadelphia: WB Saunders, 2004.



Heart sounds made easy

Price: R335.00
SAMA Member: R299.00

To order contact Carmen or Avril:
 Tel: (021) 530-6520
 Fax: (021) 531-4126
 email: carmena@hmpg.co.za or avrilm@hmpg.co.za

The South African Medical Association,
 Health & Medical Publishing Group
 1-2 Lonsdale Building, Gardener Way,
 Pinelands, 7405.



It's the **shell** that makes **Ecotrin** safer.

Safety-Coated
Ecotrin[®]
 81mg

The miracle of Aspirin made safer.

Each tablet contains Aspirin 81mg. Reg.No.: 29/2.7/0767
 Pharmalica (Pty) Ltd, 33 Hulbert Road, New Centre, Johannesburg 2001
 Under licence from Goldshield Pharmaceuticals Ltd. U.K.