

ROLE OF MULTISLICE COMPUTED TOMOGRAPHY IN CARDIAC IMAGING

Non-invasive coronary angiography along with multidetector computed tomography or magnetic resonance imaging is attracting increasing interest in affluent areas.

ELSJE DIRKS

MB ChB, MMed Rad (D), FCRad (D) (SA)

Radiologist in private practice

Kempton Park

Elsje Dirks received the MB ChB degree in 1996. She worked as a registrar at the Department of Radiology at the Pretoria Academic Hospital from 2001 to 2005.

After completing the requirements for FC Diagnosis Radiology she was admitted as a Fellow of the Colleges of Medicine of South Africa in 2004. In 2005 she received the degree MMed Rad (D) (Diagnostic Radiology) from the University of Pretoria.

Currently she is a consultant at a Gauteng-based radiology practice, practising at several hospitals in the area.

LEONIE SCHOLTZ

MB ChB, MMed Rad (D)

Radiologist in private practice

Pretoria

Leonie Scholtz received the MB ChB degree in 1980. From 1983 to 1984 she trained in echocardiography and cardiac interventional procedures at the Department of Cardiac Radiology, Stanford University School of Medicine. In 1987 she graduated Mmed Rad D (Diagnostic Radiology) at the University of Pretoria.

Leonie Scholtz is the founder member of a very large radiology practice, with multiple practices in Pretoria and the Lowveld. Until August 2005 she was Head of the Department of Diagnostic Radiology, University of Pretoria. She was the first woman to be elected as vice-president on the Exco of the Radiological Society of South Africa.

She has published papers on interventional radiology, contrast media and general radiology, and the interventional team, in which she plays a key role, has performed many 'first-ever procedures' in South Africa.

The USA spends more than one-third of its trillion-dollar health care economy treating end-stage cardiovascular disease. This includes approximately \$23 billion in the year 2000 on over 1.7 million diagnostic catheterisations in people suspected of suffering from coronary artery disease (CAD).

The current gold standard to assess stenoses in diseased coronary arteries is selective catheter-based angiography, yet roughly 40% of these tests are negative for CAD. One-third of all these procedures are undertaken with an interventional procedure in mind. This, along with the technique's inherent limits, and small but significant morbidity and mortality, has sparked interest in less expensive, non-invasive coronary angiography with multidetector computed tomography (MDCT) or magnetic resonance imaging (MRI). According to the American Heart Association there is a 0.5 - 1% risk of death from cardiac catheterisation.

This article provides a critical analysis of the possible indications and applications as well as advantages and disadvantages of MDCT in the diagnosis of CAD.

HISTORY AND BACKGROUND OF MDCT AND 64-SLICE CT

Examination of the function, perfusion and viability of the heart muscle as well as the morphology and function of the coronary arteries is of the utmost importance in the diagnostic assessment of CAD.

CT was first introduced by Sir Godfrey Hounsfield in the 1970s. CT-based coronary angiography is a new, non-invasive alternative for some patients, made possible by the development of high-speed MDCT scanners. These scanners have an array of detectors that collect data from 4-64 slices with one revolution of the CT gantry. Although 16-slice and 32-slice CT scanners have been available for a few years, 64-slice CT scanners were released only at the end of 2004.

These scanners acquire imaging data extremely rapidly, which allows selective imaging of the heart in a specific phase of the cardiac cycle, while a bolus of contrast agent passes through the arteries. Cardiac gating and short breath holds ensure that the images are free from motion

The current gold standard to assess stenoses in diseased coronary arteries is selective catheter-based angiography, yet roughly 40% of these tests are negative for CAD.

Scanning time is rapid enough to essentially stop cardiac motion, and therefore visualisation of extremely small structures such as calcium deposits within the walls of the coronary arteries is now possible.

Clinical studies have shown that coronary CT angiography (CTA) is reliable for non-invasive assessment of stenoses in the proximal and mid-regions of the coronary arteries, where the majority of stenoses are found.

artefacts. Scanning time is rapid enough to essentially stop cardiac motion, and therefore visualisation of extremely small structures such as calcium deposits within the walls of the coronary arteries is now possible. For general CT scanning, this faster capability can reduce the time that patients must stay still during the procedure, thereby reducing potential movement artefacts. Advanced images after processing contribute towards optimising its diagnostic capabilities through the routine use of volumetric reconstructions. Images can be viewed as cross-sections of the heart, 3D reconstructions, and 3D reconstructions that appear as planar images along the length of the arteries (Figs 1 and 2).

Compared with conventional CT scanning, MDCT can provide smaller pieces of information and can cover a larger area faster. Advanced MDCT technology (8-, 16-, 32-, 64-slice systems) is capable of producing more images in less time. The thinner

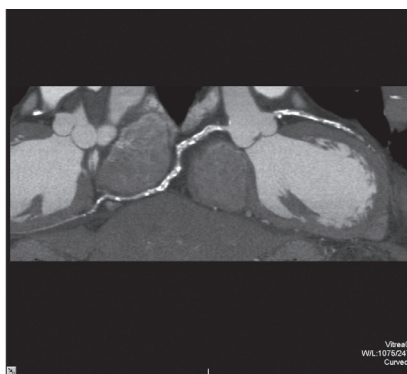


Fig. 1. Curved MIP reconstruction of the coronary arteries. (Courtesy Toshiba.)

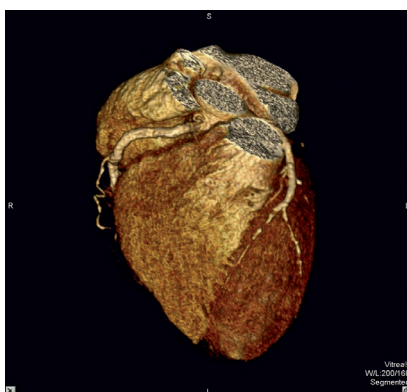

Fig. 2. Colour-coded 3D reconstruction of the heart. (Courtesy Toshiba.)

the image slice the better the image quality. MDCT therefore improves spatial and temporal resolution.

Clinical studies have shown that coronary CT angiography (CTA) is reliable for non-invasive assessment of stenoses in the proximal and mid-regions of the coronary arteries, where the majority of stenoses are found. Since 2003 approximately 150 articles on coronary CTA, some focusing on comparison with conventional angiography, have appeared in peer-reviewed journals. Most of these articles involved 16-slice scanners.

The sensitivity and specificity for the detection of clinically significant stenoses alluded to in the literature is about 90%.

APPLICATIONS FOR CORONARY CTA

The clinical indications for coronary CTA are not yet completely

established. In contrast to angiography, which often fails to detect plaque accumulation, coronary CTA exploits its cross-sectional capability to evaluate the vessel wall.

MDCT not only detects and quantifies coronary artery calcium but also grades the degree of coronary artery stenosis and assesses plaque burden (and hopefully, in the 64-slice scanners, identifies vulnerable plaque), with a sensitivity and specificity approaching 90%.

Applications for both contrast-enhanced and non-contrast cardiac CT examinations mentioned in the literature include:

- looking for significant coronary stenoses in patients with atypical-type chest pain
- assessing emergency department patients who present with a variety of chest pain syndromes
- avoiding direct cardiac catheterisation in patients with equivocal stress tests
- defining coronary bypass graft status and stent patency (Figs 3 and 4)
- noting early atherosclerosis
- performing calcium scoring to identify and characterise plaque
- picking up mildly stenotic or 'soft' plaque
- seeing arterial wall remoulding
- establishing calcium scoring as part of a preventive cardiac programme.

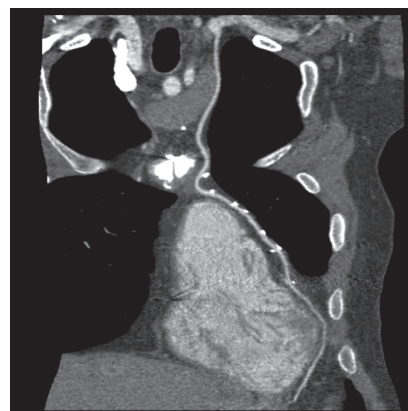

Fig. 3. Internal mammary artery bypass graft as seen on a MIP reconstruction. (Courtesy Toshiba.)

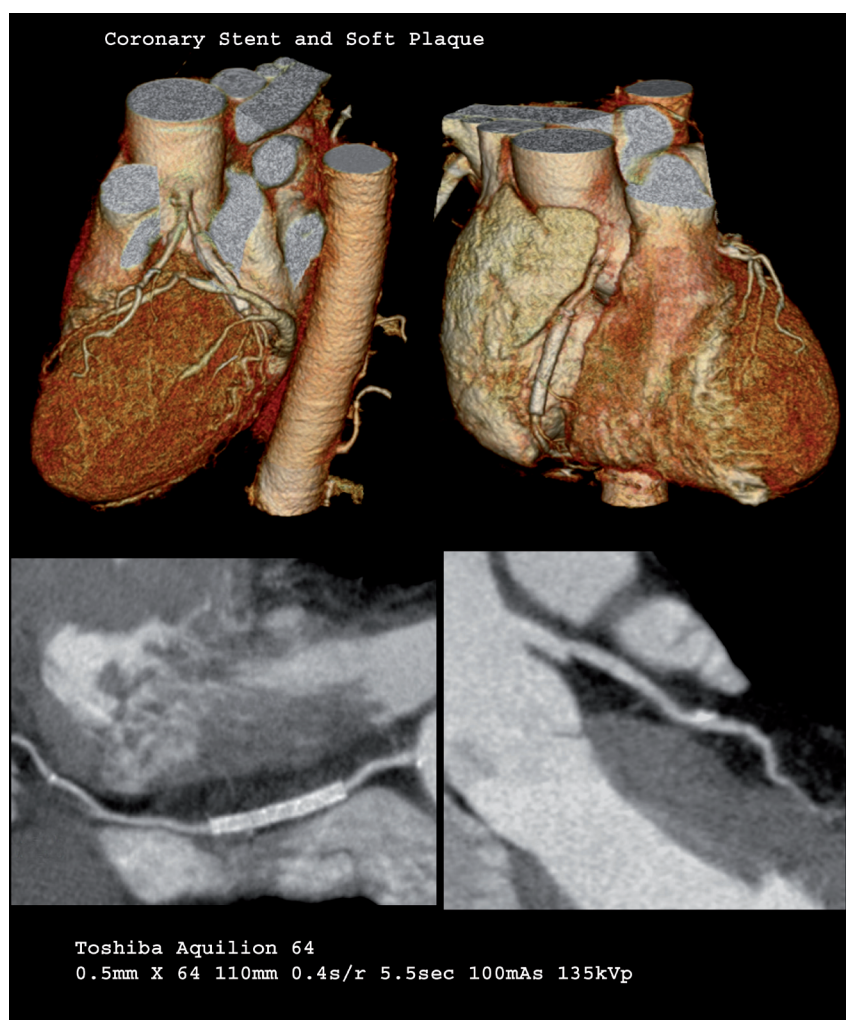

Fig. 4. Post-stent multislice CT evaluation. (Courtesy Toshiba.)

Additional applications allow one to use cardiac CT to examine the heart and its chambers specifically, as well as to define left ventricular and right ventricular function, including:

- assessing and treating hypertrophic cardiomyopathies
- defining the right ventricle in patients suspected of arrhythmogenic right ventricular dysplasia – potentially going to MRI if an equivocal reading is found
- looking at the heart chambers as a whole, such as in patients with atrial fibrillation or other rhythm problems
- evaluating patients before and after radiofrequency ablation to define any changes to the pulmonary veins
- identifying left atrial clots.
- CTA can also aid in electrophysiology through imaging of the venous anatomy before ablation or biventricular pacemaker placement.
- CT may play a role in monitoring response to statin therapy.

CT is establishing itself as a screening tool in high-risk patients, and MDCT scanners can also help to clarify findings of other non-invasive and more traditional cardiology tools, such as nuclear perfusion scans and echocardiography.

PATIENT PREPARATION AND PROCEDURES

Preparation

- In order for the coronary artery CTA to be successful, the heart rate must be less than 65 bpm. Therefore, if a patient's heart rate is more than 70, a beta-blocker must be administered the evening before and the morning of the scan.
- No food or drink should be consumed during the last 4 hours before the scan.
- As a precaution when using contrast agents, all patients must recently

have had their serum creatinine level determined.

- Pregnant patients and those with poor renal function (creatinine > 118 mmol/ml), multiple myeloma, or a history of anaphylactoid reactions to iodinated contrast agent may be excluded.
- Patients may take their regular medication, with the exception of metformin (Glucophage), which should be discontinued for at least 48 hours before the scan.

Procedures

It takes approximately 10 - 15 minutes to perform the CTA. As the heart is scanned, 50 - 100 ml of non-ionic iodinated contrast agent is injected via an intravenous line at a rate of 3 - 5 ml/s to maintain homogeneous vascular contrast throughout the scan. During the scan the patient will be asked to hold his/her breath 3 - 4 times for approximately 15 - 20 seconds. (Some institutions include calcium scoring routinely before the contrast administration.)

A great deal of time is spent after the procedure to process the data, which are analysed using maximum intensity projection (MIP), multiplanar reformatting (MPR) and volume rendering (VR). Curved MPR tools can be used to stretch out the vessel and analyse stenoses in detail (Fig. 5).

ADVANTAGES AND DISADVANTAGES OF CORONARY CTA

Coronary CTA has some advantages over catheter-based angiography. It is non-invasive and can evaluate aspects of arterial disease that angiography cannot evaluate. Coronary CTA can image blood-vessel walls and the anatomy of the heart and can therefore be used to assess the pericardium, cardiac chamber size and shape, and to detect ventricular aneurysms. MDCT can also rule out coronary stenoses with high accuracy. In addition, both calcified and non-calcified atherosclerotic plaques can be seen on coronary CTA images and it is therefore possible to assess

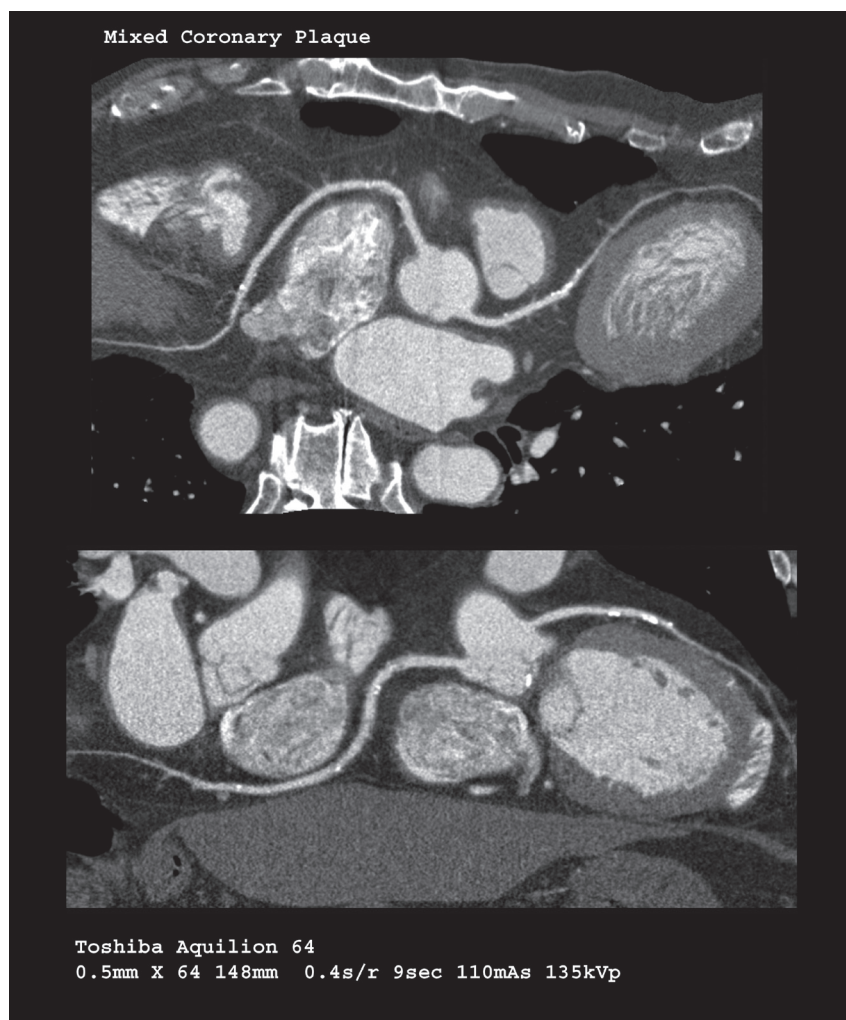


Fig. 5. Mixed plaque seen on a curved MIP reconstruction. (Courtesy Toshiba.)

a patient's total calcified and non-calcified plaque burden as high, medium or low. It is not yet possible to distinguish between lipid-rich and fibrous plaques, and predict which lesions are more likely to rupture and cause an acute cardiac event.

Procedural times are extremely short (to scan the entire heart a 16-slice scan takes 15 - 18 seconds and a 64-slice scan 5 - 10 seconds). The entire heart can be assessed in only 5 beats. The increased scan speed, which permits an entirely ECG-gated thorax study, allows the three most life-threatening critical conditions in chest pain – aortic dissection, pulmonary embolism and CAD – to be ruled out (or in) in one single scan. It can also exclude other intrathoracic causes for chest pain.

More images are obtained in less time, producing fewer movement artefacts. MDCT can also be used to map the pulmonary veins before pulmonary vein ablation for atrial fibrillation or biventricular pacemaker placement.

Specific advantages of 64-slice scanners are the following:

- thinner slices allow for more precise measurement of stenosis and visualisation of smaller branch vessels
- ability to acquire high-quality images in obese patients
- shorter breath holds and acquisition times
- reduction in volume of contrast media
- better characterisation of soft-tissue plaque and less blooming artefacts from arterial calcification.

LIMITATIONS

There are some limitations associated with coronary CTA. Firstly, patients with cardiac arrhythmias, such as atrial fibrillation, may not be successfully imaged with coronary CTA owing to image degradation caused by motion artefacts. Secondly, for patients with extensive coronary artery calcification, it may be impossible to characterise stenosis accurately owing to obscuration by calcium. Thirdly, intravascular stents cause blooming artefacts, which may prevent visualisation of the stented lumen of the vessel. In-stent stenosis in smaller stents can be difficult to assess with coronary CTA. This was noted in the 16-slice scanners but is largely eliminated in the 64-slice scanners.

Dense calcifications can also cause blooming artefacts in high-grade stenoses that may result in overestimation of lesion size. Other limitations are low temporal resolution and high radiation dose, which equals that of a nuclear scan.

CT differentiates very well between calcified and non-calcified lesions but cannot always reliably differentiate between lipid-rich tissue and fibrous tissue. Because of the limitation in spatial resolution it cannot be expected to assess a thin fibrous cap that is approximately ten times beyond the current resolution of a multislice CT (MSCT). In addition, contrast uptake as an indicator of an inflammatory process in the arterial wall is unlikely to be detected by MSCT.

Pacemakers can also sometimes cause artefacts. MRI again is regarded as superior in evaluating myocardial viability, masses and thrombi. The radiation dose of a cardiac MDCT study equals that of a nuclear scan, and cannot be ignored. The time required for post-processing must not be underestimated; more time is demanded by the radiologist to report on these cases.

SUMMARY

In summary, cardiac MDCT is a rapidly evolving technology. It moves CT beyond the traditional imaging of static anatomy to the imaging of dynamic motion. Highly detailed and reproducible images of the circulation can be produced by 64-slice CTA in a non-invasive manner. This technique may replace diagnostic cardiac catheterisation in many circumstances and promises to become a primary tool for detecting CAD in 'at risk' and symptomatic patients. With the rapid advancement of CT imaging, more widespread use of CT for functional evaluation of the heart can be expected. CTA is excellent for ruling out disease.

If cardiologists view this not as a threat, but as something likely to produce more interventional catheter studies and procedures, MDCT will eliminate a significant number of unnecessary invasive cardiac studies.

Clinicians now have the tools to identify the presence of CAD in the pre-symptomatic phase and to help to identify the aetiology of pain syndromes in patients presenting with atypical and obscure symptoms and who are suffering from obstructive CAD, aortic dissection, pulmonary emboli or other pathological processes.

Will the CT scanner become the next stress test?

Further reading

Becker CR. Total assessment of coronary artery with CT. *Vascular Imaging* 2002; July: 773-781.

Elliot LP. *Cardiac Imaging in Infants, Children and Adults*. Philadelphia: J B Lippincott, 2001.

Radiol Clin North Am 2004; **42**: (whole issue).

Schoepf UJ. *CT of the Heart*. Humana Press, 2005.

IN A NUTSHELL

Tables I and II provide a summary of some of the advantages and disadvantages of coronary CTA and coronary angiography.

Table I. **Coronary CTA**

Advantages	Disadvantages
Non-invasive	Not suitable for patients with irregular heart beat or those with contraindications for iodine
Can rule out coronary stenoses with high accuracy	Need beta-blocker to lower HR to < 65
Can establish patency of bypass grafts and stented arteries	Difficult to assess in-stent re-stenosis
Can assess calcified and non-calcified plaque burden	Patients must hold breath 15 - 20 s, 3 - 4 times
Can visualise cardiac and coronary venous anatomy	

Table II. **Coronary angiography**

Advantages	Disadvantages
Well-established 'gold standard'	No visualisation of wall structures
Can perform interventions (e.g. angioplasty, stent placement)	Cannot detect early disease before lumen narrowing
	Risk of groin haematoma, pseudoaneurysm, or arteriovenous fistula (1 - 3%)
	Risk of heart attack or stroke