

# MORE ABOUT...NEUROLOGY

## VASCULAR DEMENTIA

**VIVIAN FRITZ**, MB BCh, FCP (SA), PhD (Wits), FRCP (LOND), FC NEUROL (SA)

**Emeritus Professor of Neurology**, University of the Witwatersrand, Johannesburg

### Definition

Vascular dementia (multi-infarct dementia) is a disease in which the ability to remember, understand, communicate and control behaviour declines because of brain damage due to strokes. Unlike other forms of dementia, vascular dementia can be prevented by correcting or eliminating the risk factors for strokes. A stepwise deterioration and a fluctuating course are the characteristic historical features. Focal neurological signs (e.g. unilateral weakness, sensory loss, asymmetric reflexes or Babinski's sign) are found in over 85% of patients. Patients with Alzheimer's disease usually have a slowly progressive course and no focal signs.

There are a number of different types of vascular dementia. Two of the

most common types are multi-infarct dementia and Binswanger's disease.

### Multi-infarct dementia

This is probably the most common form of vascular dementia and is caused by a number of small strokes or transient ischaemic attacks (TIAs). The strokes cause damage to the cortex of the brain – the area associated with learning, memory and language. A person with multi-infarct dementia is likely to have better insight in the early stages of the disease than a person with Alzheimer's disease and parts of his/her personality may remain relatively intact for longer. Symptoms may include severe depression, mood swings and epilepsy.

### Binswanger's disease

Binswanger's disease is also known as subcortical vascular dementia. This condition was initially thought to be rare but is now being reassessed and may in fact be relatively common. As with the other vascular dementias, it is associated with stroke-related changes.

The 'white matter' deep within the brain is affected. The disease is

caused by high blood pressure, thickening of the arteries and inadequate blood flow. Symptoms often include slowness and lethargy, difficulty in walking, emotional ups and downs, and lack of bladder control early in the course of the disease. Most people with Binswanger's disease have or have had high blood pressure.

In the Western world, vascular disease is thought to be the second most common cause of dementia after Alzheimer's disease. Vascular disease is at least partially preventable and treatable. Therefore, increasing awareness of this association may decrease the incidence of dementia.

Vascular disease may produce a range of cognitive deficits – from mild to severe – and early recognition of a deficit allows the clinician to intervene before the dementia occurs. It has long been known that cognitive deficits may result from a stroke, yet only recently have studies shown that dementia occurs in approximately one-fourth to one-third of stroke cases.

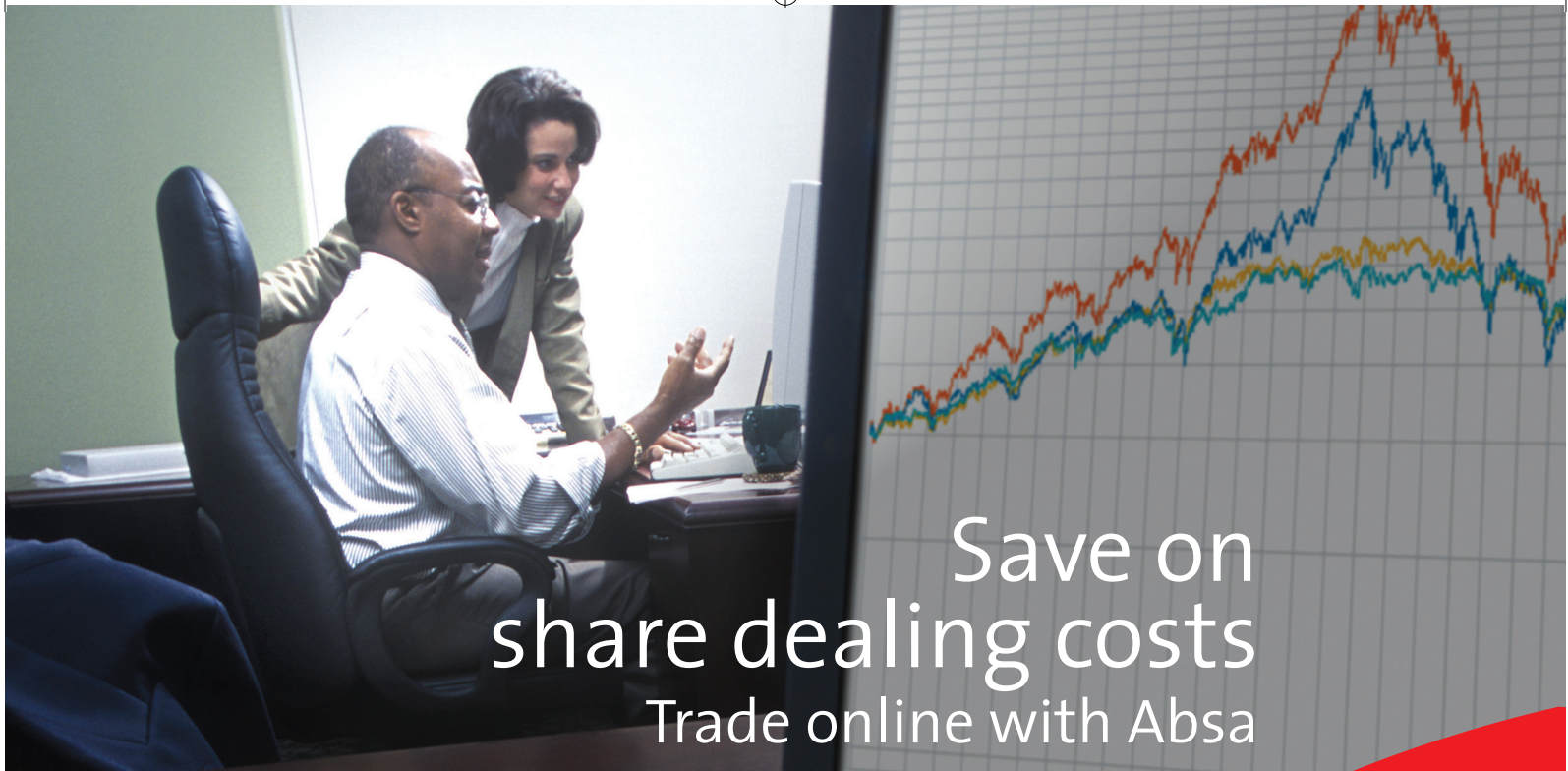### Risk factors

The risk factors for vascular disease are well established. However, little is known about those for vascular dementia. Traditionally, risk factors for the latter have been directly extrapolated from the vascular disease literature:

- Increasing age is the only well-established risk factor for vascular dementia.
- The gender status is controversial and a recent study found men and women to be equally affected.
- Genetics play a role. Cerebral arteriopathy with subcortical infarcts and leukoencephalopathy (CADASIL) is a genetic disease that involves notch3 mutations leading to the presence of subcortical infarcts and dementia in 90% of affected persons who die with the condition.

Table 1. Differences between dementia of the Alzheimer's type (DAT) and vascular dementia

| Criteria                   | DAT                                     | Vascular dementia  |
|----------------------------|---|--|
| History of previous stroke | Unusual                                 | Common   |
| Onset                      | Insidious                               | Abrupt   |
| Progress                   | Progressive deterioration               | Stepwise deterioration   |
| Insight                    | Lost early                              | May remain intact for longer   |
| Cognitive                  | Early impairment of short-term memory   | Recognition memory preserved. Executive function impaired early  |
| Neurological examination   | No focal features                       | Focal neurological abnormalities   |
| CT/MRI                     | Normal scan or diffuse cerebral atrophy | Multiple or strategic single infarcts, haemorrhages, multiple lacunes, extensive white-matter lesions or combinations of these |



Save on  
share dealing costs  
Trade online with Absa

## Absa Stockbrokers

Flat brokerage rate of 0,4% (minimum R120 + VAT per deal)

[www.absa.co.za](http://www.absa.co.za)

Member of the  **BARCLAYS** Group

Absa Stockbrokers (Pty) Limited (reg. no. 1973/010798/07). A member of the JSE Limited.



*Today, tomorrow, together.*

29902/Mortimer Harvey/E/Save on share/CME



## 2nd Clinical Sports Medicine Conference "Practical Clinical Techniques in Sports Medicine"

incorporating the: FIMS Sports Rehabilitation Course  
**Preliminary Programme**  
Wednesday 4 to Friday 6 October 2006


Hosted by: UCT/MRC Research Unit for Exercise Science and Sports Medicine, Department of Human Biology, Faculty of Health Sciences,  
University of Cape Town, South Africa

In conjunction with the: International Federation of Sports Medicine (FIMS)  
South African Sports Medicine Association (SASMA)  
Biokinetics Association of South Africa (BASA)  
Sports Interest Group of the South African Society of Physiotherapy

Venue: Vineyard Hotel, Newlands, Cape Town  
Congress Coordinator: Deborah McTeer of the University of Cape Town  
Conference Management Centre.

Please indicate if you would like to receive further information by sending an email to  
[mcollin@curie.uct.ac.za](mailto:mcollin@curie.uct.ac.za) or [deborah@curie.uct.ac.za](mailto:deborah@curie.uct.ac.za)

Please direct all other enquiries to Ms Marta Collins or Ms Deborah McTeer at:  
Telephone: 021 406-6348 Fax: 021 448-6263



- A history of prior stroke is an important risk factor for vascular dementia. Not only is the size and number of infarcts relevant, but also the location of even a single strategically placed lesion may be sufficient to cause dementia. The presence of prior ischaemic stroke on brain imaging has been associated with a nine-fold increase in the development of dementia.

**Vascular disease and Alzheimer's disease**

The prevalence and severity of dementia are increased in patients with cerebral infarcts compared with those without infarction. The two processes may share common risk factors. Hypertension, diabetes mellitus and smoking have been associated with both vascular disease and Alzheimer's disease. Furthermore, ApoE4 appears to increase the risk of development of Alzheimer's disease and of dementia in stroke patients. Hyperhomocysteinaemia, a well-documented vascular risk factor, is also associated with Alzheimer's disease.

Vascular and degenerative pathology may interact to lead to cognitive decline. Atherosclerosis is increased in both conditions. Amyloid deposits may occur in certain conditions associated with vascular disease, such as hereditary cerebral haemorrhage with amyloidosis. Amyloid deposits also play a pivotal role in the pathogenesis of Alzheimer's disease.

Further studies are required to clarify the mechanisms whereby vascular and degenerative processes interact.

Various factors in the history and physical examination of patients with suspected vascular disease resulting in dementia appear to be characteristic enough that an 'ischaemic score' has been devised by Hachinski *et al.* to help to differentiate between these patients and those with Alzheimer's disease. Table I lists the differences between Alzheimer's disease and vascular dementia.

It is beyond the scope of this article to discuss management of vascular

dementia (see Further reading – Black SE).

**Further reading**

Black SE. Vascular dementia. Stroke risk and sequelae define therapeutic approaches. *Postgrad Med* (Symposium on Stroke). 2005; **117**: (1).

Gorelick PB. Status of risk factors for dementia associated with stroke. *Stroke* 1997; **28**(2): 459-463.

Hachinski VC, Iliff LD, Zilhka E, *et al.* Cerebral blood flow in dementia. *Arch Neurol* 1975; **32**(9): 632-637.

Joutel A, Corpechot C, Ducros A, *et al.* Notch3 mutations in cerebral autosomal dominant arteriopathy with subcortical infarcts and leukoencephalopathy (CADASIL), a mendelian condition causing stroke and vascular dementia. *Ann NY Acad Sci* 1997; **826**: 213-217.

Slooter AJC, Tang MX, Van Duijn CM, *et al.* Apolipoprotein E epsilon 4 and the risk of dementia with stroke. A population-based investigation. *JAMA* 1997; **277**: 818-821.

**NEUROLOGICAL COMPLICATIONS OF HIV INFECTION**

**CM SCHUTTE, MB ChB, MMed (Neur), MD**

**Professor and Head, Department of Neurology, University of Pretoria**

Around 40 million people worldwide are infected with HIV, and the largest number of these live in the developing countries. In South Africa, many patients still present with opportunistic infections and tumours at a late stage of HIV infection without having been diagnosed as HIV-positive

Table I. **Common neurological complications of HIV**

- Due to HIV
  - Distal sensory peripheral neuropathy
  - HIV dementia
  - Vacuolar myelopathy
  - Polymyositis
- Opportunistic infections
  - Toxoplasmosis
  - Cryptococcal meningitis
  - Tuberculosis
  - Cytomegalovirus
  - Progressive multifocal leucoencephalopathy
- Tumours
  - Primary CNS lymphoma
  - Metastatic systemic lymphoma
- Drug-related
  - Peripheral neuropathy
  - Myopathy

From: Manji H, Miller R. The neurology of HIV infection. *J Neurol Neurosurg Psychiatry* 2004; **75**: 25-35.

before. However, with the advent of antiretroviral therapy (ART), reductions in mortality and morbidity are expected. Table I shows the common neurological complications of HIV infection.

**Complications due to HIV Seroconversion syndromes**

Up to 70% of patients develop a glandular fever-like disease at HIV seroconversion. This may be accompanied by neurological disorders, e.g. aseptic meningitis, encephalitis, transverse myelitis and Guillain-Barré syndrome (with CSF lymphocytic pleocytosis).

**Distal sensory peripheral neuropathy (DSPN)**

Clinically, about a third of patients develop DSPN. Painful feet, distal hyperpathy and impaired sensation with depressed reflexes and mild distal weakness are found. Treatable causes for neuropathy (e.g. vitamin B<sub>12</sub>, glucose) should be excluded.

**HIV-associated dementia (HAD) or strokes**

HAD should be considered in any young person (< 50 years) who presents with cognitive problems. Patients develop a depression-like picture which progresses to memory loss and personality changes. On MRI, atrophy and diffuse white matter changes occur. Patients tend to stabilise when ART is introduced. Worldwide, ART has decreased the incidence of HAD by 50%.

Strokes may be caused by a vasculitic or thrombophilic syndrome, but a recent study from Johannesburg showed that protein S deficiency in HIV-positive patients with stroke is probably an epiphenomenon of HIV infection, not related to coagulopathies.

**Vacuolar myelopathy**

Up to a third of AIDS patients have vacuolisation in the thoracic cord on postmortem studies, but clinical manifestations only occur when the myelin loss is very prominent in the lateral and posterior columns, causing



a progressing spastic paraparesis, sphincter dysfunction and vibratory and position sense loss. The disorder is often associated with HAD and patients may benefit from ART.

### **HIV polymyositis**

Progressive proximal muscle weakness with muscle atrophy may be seen in HIV polymyositis. The creatine kinase values are usually elevated and muscle biopsy remains the gold standard for the diagnosis. Cautious treatment with steroids is beneficial.

## **Opportunistic infections**

### **Meningitis**

HIV-positive patients may have meningitis without the typical clinical picture – only a third of patients have photophobia, neck stiffness and a Kernig's sign. The index of suspicion for meningitis should be high in an HIV-positive patient presenting with headache, and a lumbar puncture following imaging studies should be performed. However, the CSF can be completely normal owing to the immunosuppressed state. This is especially true for cryptococcal meningitis – cryptococcal antigen and Indian ink stains should always be performed. Even so, some cases are only diagnosed after 2 - 3 days when the CSF culture is known. The normal rules for CSF results also do not apply; HIV-positive patients with pneumococcal meningitis often have very few cells in the CSF, and protein levels may be normal. In addition, dual infections often exist, making treatment difficult. Tuberculous meningitis is arguably the most difficult to diagnose, and a high index of suspicion should be maintained, especially in South Africa, where TB is very prevalent.

Brain imaging studies may show basal enhancement of the meninges, usually in chronic meningitis, and hydrocephalus and cryptococcomas/tuberculomas may be visible. Patients often develop complications such as cranial nerve deficits and progressive loss of vision, which may be due to high intracranial pressure responding to repeated lumbar puncture.

Treatment for cryptococcal meningitis is usually by intravenous amphotericin B for 2 - 4 weeks, followed by fluconazole 400 mg per day for 6 weeks, and lifelong fluconazole maintenance therapy to prevent relapses. Tuberculous meningitis is treated in the standard manner for a year, while pneumococcal meningitis often requires addition of vancomycin to a third-generation cephalosporin for 14 days.

### **Toxoplasmosis**

Reactivation of toxoplasmosis is common in HIV-infected patients and usually presents with progressive focal neurological symptoms and signs. Brain imaging shows multiple mass lesions at the grey-white interface, or in the basal ganglia, surrounded by oedema. Toxoplasmosis serology is positive in 85% of cases but seronegativity does not exclude the diagnosis. Treatment is usually empiric, with pyrimethamine and sulfadiazine, or high-dose co-trimoxazole.

### **Other infections**

Cytomegalovirus infection can cause encephalitis, retinitis (usually in a setting of very low CD4 counts), and lumbar polyradiculopathy. Progressive multifocal leucoencephalopathy (PML), caused by a reactivation of the JC-virus, presents with a progressive hemiparesis, hemianopia, ataxia and cognitive dysfunctions. On imaging, parieto-occipital and frontal lobes are most commonly affected by white matter lesions with typical scalloping at the grey-white junction without mass effect. Diagnosis is by brain biopsy or PCR in the CSF. ART combined with alpha-interferon or cidofovir may stabilise the condition, but further studies are still awaited.

## **Tumours**

### **Primary CNS lymphoma**

Patients usually present with subacute progressive focal deficits. Imaging studies commonly show a single lesion, often adjacent to the ventricles. The prognosis is grave, although radiation therapy may be of some value.

## **Complications due to ART**

### **Immune restoration inflammatory syndrome (IRIS)**

This syndrome refers to a paradoxical deterioration of the clinical picture due to immunological recovery after the initiation of ART. Within a few weeks after starting treatment, PML, cryptococcal meningitis and cytomegalovirus syndromes develop. In the Pretoria Academic Hospital, an association with the development of TB meningitis has been anecdotally noted.

### **Peripheral neuropathy/myopathy**

Nucleoside reverse transcriptase inhibitors, e.g. didanosine, zalcitabine and stavudine, may cause a peripheral neuropathy with very painful feet and a rapid progression. Discontinuing the drug does not necessarily resolve the situation and chronic treatment with amitriptylene, gabapentin or lamotrigine may be necessary. Use of zidovudine in high doses may cause a myopathy with typical proximal weakness.

### **Further reading**

- Manji H, Miller R. The neurology of HIV infection. *J Neural Neurosurg Psychiatry* 2004; **75**: 25-35.
- Mochan A, Modi M, Modi G. Protein deficiency in HIV-associated ischaemic stroke: an epiphenomenon of HIV infection. *J Neural Neurosurg Psychiatry* 2005; **76**(10): 1331.
- Modi M, Mochan A, Modi G. Management of HIV-associated focal brain lesions in developing countries. *QJM* 2004; **97**(7): 413-421.
- Schutte CM. Clinical, CSF and pathological findings and outcomes in HIV-positive and HIV-negative patients with TB meningitis. *Infection* 2001; **29**(4): 213-217.
- Schutte CM, Van der Meyden CH, Magazi DS. The impact of HIV on meningitis as seen at a South African Academic Hospital. *Infection* 2000; **28**(1): 3-7.
- Subsai K, Kanoksri S, Siwaporn C, Helen L, Kanokporn O, Wantana P. Neurological complications in AIDS patients receiving HAART: a 2-year retrospective study. *Eur J Neurol* 2006; **13**(3): 233-239.