

LIVER TRANSPLANTATION: AN UPDATE

D KAHN, MB ChB, ChM, FCS (SA)
MRC/UCT Liver Research Centre and
Department of Surgery, University of
Cape Town

C W N SPEARMAN, MB ChB, MMed
(Med), FCP (SA)
MRC/UCT Liver Research Centre and
Department of Medicine, University of
Cape Town

M McCULLOCH, MB ChB, FCPaed
Department of Paediatrics, University of
Cape Town

A NUMANOGLU, FCS (SA)
Department of Surgery, University of
Cape Town

The first human liver transplant was performed by Tom Starzl in Denver in 1963. Liver transplantation (LTx) has now become established as the treatment of choice for most patients with end-stage liver failure and is performed routinely in most major centres throughout the world. The long-term outcomes are now comparable with transplantation outcomes for kidneys and hearts.

Indications

The indications for liver transplantation, as shown in Table I, include the chronic liver diseases, fulminant liver failure, hepatic malignancies, and metabolic liver diseases.^{1,2}

The chronic liver diseases consist of the hepatocellular diseases such as autoimmune liver disease, cirrhosis caused by hepatitis B virus (HBV) or hepatitis C virus (HCV) infection, alcoholic liver disease, and cryptogenic cirrhosis, and the cholestatic liver diseases such as primary sclerosing cholangitis, primary biliary cirrhosis, and biliary atresia in children. The recurrence of HBV after transplantation is almost universal but relatively easily managed with antiviral agents¹ and immunoprophylaxis. Unfortunately the treatment is prohibitively expensive

and not affordable locally. The recurrence of HCV remains a problem. Patients with alcoholic liver disease, previously excluded from liver transplantation, have to undergo a very careful evaluation including a psychosocial assessment because of the problems of recidivism and non-compliance after transplantation.³ Most programmes require that patients demonstrate the ability to abstain from alcohol for at least 6 - 12 months. The result of liver transplantation in alcoholic liver disease is no different from that in other indications.

Patients who undergo liver transplantation for hepatoma have a very high risk of recurrence in the new liver. However, certain subgroups of patients with a hepatoma have been shown to have a more favourable prognosis after liver transplantation.

Table I. Indications for liver transplantation

Chronic liver diseases

Hepatocellular
Viral-induced cirrhosis
Autoimmune liver disease
Cryptogenic cirrhosis
Alcoholic liver disease
Cholestatic
Primary sclerosing cholangitis
Primary biliary cirrhosis
Biliary atresia

Fulminant liver failure

Viral-induced liver failure
Drug-induced liver failure
Toxins

Liver cancer

Hepatoma
Cholangiocarcinoma
Metastatic cancer

Metabolic liver disease

Liver failure
Wilson's disease
Tyrosinaemia
 α_1 -antitrypsin deficiency
Liver – normal
Hyperoxaluria
Hypercholesterolaemia

These include certain histological subtypes of hepatoma, such as the fibro-

lamellar tumours. Patients with small tumours (< 5 cm), with fewer than 3 tumours, and without vascular invasion have a better prognosis. Although there have been a few reports of a favourable outcome after liver transplantation for cholangiocarcinoma, the latter remains a contraindication for transplantation. Endocrine tumours in the liver and metastatic liver cancer are also contraindications for liver transplantation.

The metabolic liver diseases include α_1 -antitrypsin deficiency and tyrosinaemia, which results in liver damage. Because of liver failure these patients undergo liver transplantation. In contrast there are diseases in which the liver, although morphologically normal, contains an enzyme defect which results in damage to another organ. For example, patients with hyperoxaluria present with renal failure; therefore a replacement kidney will be damaged. These patients require a combined liver and kidney transplant.

Timing

Because of the significant improvement in the outcomes after liver transplantation, patients are being referred earlier.⁴ Patients with very advanced liver disease tend to have a more complicated postoperative recovery because of poor general condition. Patients with liver disease should therefore be referred to a liver transplant centre for assessment sooner rather than later, and especially if there has been a complication of the liver disease, such as variceal bleeding, severe ascites, encephalopathy, pruritus or spontaneous bacterial peritonitis.

Surgical technique

Donor hepatectomy

The donor liver is removed from the cadaver donor as part of a multiple-organ harvest which includes the heart and kidneys, and increasingly, the lungs and pancreas.⁵ After cannulation of the aorta and inferior mesenteric vein, the liver is perfused with ice-cold preservation solution via the hepatic artery and portal vein. The

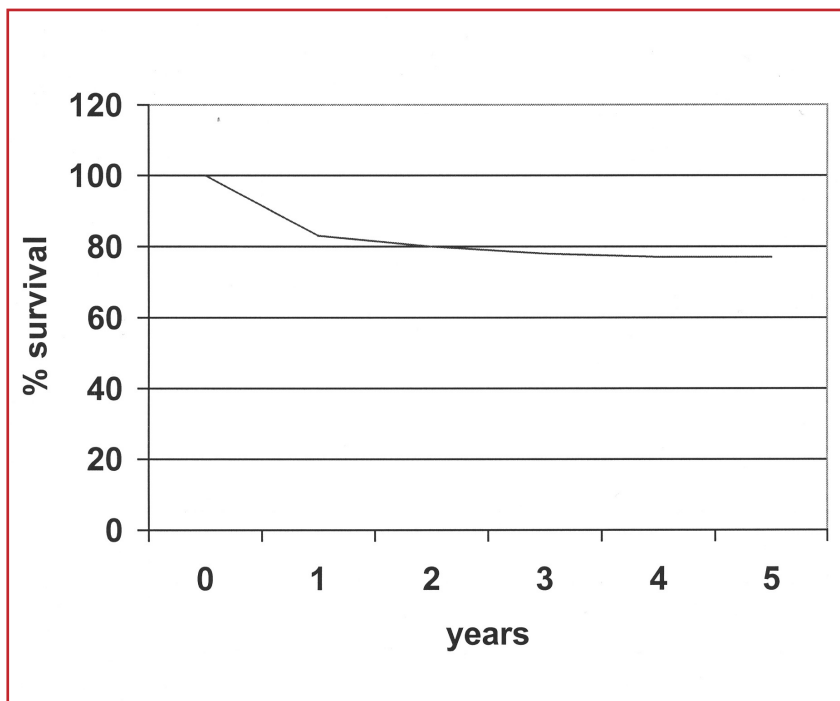


Fig. 1. Survival after liver transplantation.

liver is removed *en bloc* and the vital vascular and biliary structures are dissected out on the backtable.

Preservation

Currently, the University of Wisconsin solution (Viaspan) is the gold standard for liver preservation.⁶ Donor livers can be preserved quite safely for 12 - 18 hours. The newer preservation solutions, including HTK and Celsior, have been shown to be equivalent to Wisconsin solution.

Recipient operation

The removal of the diseased recipient liver remains the most difficult part of the transplant procedure because of the ligamentous attachments of the liver and portal hypertension. The use of the venovenous bypass in the early days of liver transplantation was an important improvement in the surgical technique. However, it is now used only selectively.

Implantation of the new liver consists of suprahepatic venacaval anastomosis, along with the portal vein and hepatic artery. The biliary anastomosis is completed either by a duct-to-duct choledochocholangiostomy or choledochojunostomy.

Reduced-size liver transplant

Because of the critical shortage of suitable paediatric donors, reduced-size adult livers are routinely used in children. The liver can be divided into 2 halves or 8 segments, based on its blood supply and hepatic venous and biliary drainage, and transplanted into children.

Split-liver transplant

A single donor liver can also be divided into 2, usually a left lateral segment

It's the shell that makes Ecotrin[®] safer.

Safety-Coated
Ecotrin[®]
81 mg

The miracle of Aspirin made safer.

Each tablet contains Aspirin 81 mg. Reg No.: 29/2.7/0767
Pharmatica (Pty) Ltd, 33 Hulbert Road, New Centre, Johannesburg 2001
Under licence from Goldshield Pharmaceuticals Ltd, U.K.

and a right half, and transplanted to paediatric and adult recipients, respectively. These techniques have been introduced to address the critical shortage of donor livers. The liver can be split either *in situ* in the donor, or *ex situ* after it has been removed from the donor.

Living-donor liver transplant

Living-donor liver transplants are now performed routinely in many centres throughout the world. It usually involves removing the left lateral segment from a parent for transplantation into a child. Adult-to-adult living-donor transplantation requires the removal of the right lobe of the liver from the donor and transplantation into the recipient.

Immunosuppression

Conventional immunosuppression consists of steroids, a calcineurin inhibitor (either cyclosporin or tacrolimus), and a lymphocyte proliferation inhibitor (azathioprine or mycophenolate mofetil). Induction therapy with a polyclonal antibody (ATG) or a monoclonal antibody (OKT3, Basiliximab or Daclizumab) is also an option. All immunosuppressive agents have side-effects, and alternatives to conventional immunosuppression, such as steroid-free or calcineurin-free protocols, have been described.

Complications

Technical complications after liver transplantation are now relatively uncommon. The usual technical complications include hepatic artery thrombosis and bile duct leak or stenosis. Most of the problems following liver transplantation are related either to inadequate immunosuppression or over-immunosuppression. The former results in acute rejection, which can be managed relatively easily with bolus doses of methylprednisolone or conversion to alternative immunosuppressive therapy.

Infectious complications related to over-immunosuppression result in significant morbidity and occasional mortality. Cytomegalovirus (CMV) infection and

disease tend to be a problem in recipients who have not had previous exposure to CMV. Patients who are at high risk of CMV infection can be given prophylaxis with intravenous ganciclovir.

Lymphoproliferative disease, especially in children, seems to be related to lack of previous exposure to Epstein-Barr virus (EBV) and over-immunosuppression. The management of this complication can be difficult since the immunosuppressive therapy has to be virtually withdrawn.

Locally, tuberculosis has also been a problem, not only because of the infection itself, but also because of the side-effects of the antituberculosis drugs.

Results

The long-term results after liver transplantation are excellent (Fig.1). With better patient selection and newer, more potent immunosuppression protocols, 1- and 5-year survival figures in excess of 90% and 80%, respectively, are reported.

References available on request.

DIAGNOSIS OF PORPHYRIA IN SOUTH AFRICA

PETER N MEISSNER, BSc (Med)
Hons, PhD

Head: *Lennox Eales Porphyria Laboratories*

Co-director: *MRC/UCT Liver Research Centre, Department of Medicine, Groote Schuur Hospital, Cape Town*

RICHARD J HIFT, MB ChB, MMed (Med), PhD, FCP (SA)

Professor, *MRC/UCT Liver Research Centre, Department of Medicine, Groote Schuur Hospital, Cape Town*

All forms of porphyria arise from partial deficiencies in one of the enzymes of the haem biosynthetic pathway. These deficiencies may result in a specific pattern of porphyrin accumulation

and a characteristic clinical syndrome. The three forms of porphyria most frequently encountered in South Africa are variegate porphyria (VP), acute intermittent porphyria (AIP) and porphyria cutanea tarda (PCT). Other forms are occasionally seen. Both VP and AIP are inherited but PCT is usually an acquired disorder associated with alcohol abuse, iron overload, oestrogen therapy, viral infection (particularly hepatitis C virus and HIV) and liver disease.

Clinically the porphyrias are characterised by two principal features: photosensitive skin disease and acute neurovisceral attacks (which may result in a potentially fatal motor neuropathy). AIP is characterised by acute attacks only, PCT by skin disease only and VP may be accompanied by both. Both VP and AIP show low clinical penetrance, and 60 - 80% of those who carry the gene remain clinically asymptomatic throughout life. It cannot be predicted which individuals will fall into this category. Essentially, these three disorders never present with symptoms or with biochemical changes prepubertally, despite inheritance of a disease-associated mutation.

It is important to diagnose VP and AIP timeously and correctly because of the risk of the acute attack. Diagnosis of PCT is important because it is often fully reversible when the underlying causative factors are correctly identified, reversed and appropriate treatment is given.

Although VP has an exceptionally high incidence in South Africa, because of the R59W founder gene, AIP and PCT are regularly encountered and frequently misdiagnosed or misidentified as VP. The diagnosis of AIP and PCT may also be missed and delayed. Every South African doctor must apply a sensible diagnostic approach to:

- establish whether a patient has porphyria
- to assess whether the presenting symptoms are indeed caused by the porphyria