

CLINICAL EXAMINATION OF THE PATIENT WITH RHEUMATIC DISEASE

Rheumatic diseases cause a large burden on society in terms of direct costs and indirect cost from psychosocial and economic factors.



DAVID GOTLIEB

MB ChB, FCP (SA)

Rheumatologist

Constantiaberg Medi-Clinic
Cape Town

Dr Gotlieb is a registered rheumatologist in private practice at Constantiaberg Medi-Clinic, Cape Town. He received under- and postgraduate training at the University of Cape Town. He is a former President of the South African Rheumatism and Arthritis Association (SARAA) (2001 - 2003), a former Chairman of the Western Cape Physicians Association, and a former Vice-Chairman of SAMA – Cape Western Branch region. He is an ongoing member of the Western Cape Peer Review and Ethics Committee. Dr Gotlieb has a particular interest in clinical rheumatology. His other major interests include an internet rheumatology teaching facility through his website www.arthritis.co.za, which receives a 'readership' of approximately 50 000 a month, making it one of the largest physician-based internet sites on the web.

Early diagnosis and treatment of inflammatory arthropathy influences long-term outcome. Without a diagnosis, no treatment is possible. New imaging techniques enable a specific diagnosis. However, they do not replace the basic clinical examination, since radiographs and blood tests may be normal in the presence of disease.

There are well over 100 musculoskeletal conditions. The starting point is to determine the difference between inflammatory and mechanical or degenerative process (Fig. 1). Thereafter one can make an anatomical diagnosis of the precise articular or extra articular structures involved and finally a pathological diagnosis.

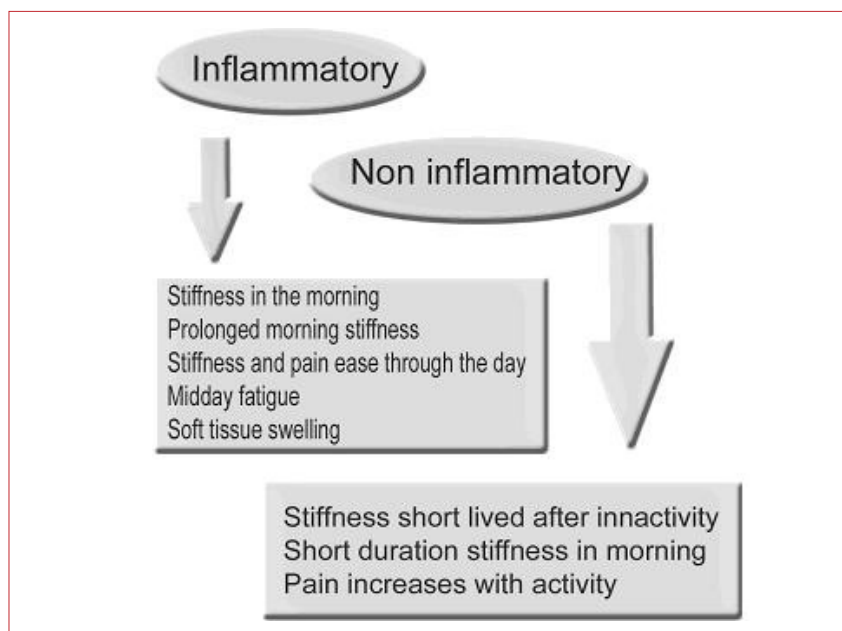


Fig. 1. Differentiation of inflammatory from non-inflammatory disease.

THE HISTORY (TABLE I)

A comprehensive history of the presenting complaint, as well as the general medical and systematic history are obtained. Past history and family history should be obtained, as well as a list of medications and allergies.

Pain

Pain is the most common presenting complaint. Chronology and aggravating factors provide clues to pain origin. These include, e.g. prior trauma, or even preceding infections causing reactive arthritis. Pain can be acute and almost instantaneous or over hours, as in gout compared with pseudogout, in which pain may occur over weeks, or osteoarthritis, where the pain can gradually increase over years. Thirty per cent of rheumatoid patients present with pain of acute onset. Pain may wax and wane over days in cycles over months as in palindromic rheumatism.

There are well over 100 musculoskeletal conditions. The starting point is to determine the difference between inflammatory and mechanical or degenerative process.

Inflammatory pain is usually maximal in the morning and increases again at the end of the day. Mechanical pain is maximal with use and activity. Night pain and rest pain may frequently be seen in bone diseases such as Paget's disease, but is also seen in malignancy. Neuralgic pain is usually diffuse in a dermatomal distribution worsened by specific activity, whereas referred pain is unaffected by local movement. Diffuse, unrelenting pain is often associated with fibromyalgia. The description of pain may be very subjective. Joint pain is often described as aching, while nerve entrapment is frequently described as being like an electric shock.

Stiffness

The duration of the stiffness is proportional to the amount of inflammation. Degenerative processes result in short-duration morning or post-rest stiffness. The stiffening of the joints is called 'gelling'. Inflammatory disease causes

prolonged morning stiffness, often of more than an hour.

Locking

Locking implies mechanical derangement of a joint or tendon. In the case of the flexor tendons of the hands, irregularity of the tendons within the tendon sheath may cause tendon entrapment and locking of the fingers. Joint locking occurs most classically in the knee owing to meniscus injury, and in the spine with disk or apophyseal joint disease.

Swelling

Subjective complaints of swelling are common and should be differentiated from the objective finding of swelling in joints or soft tissues on examination.

Fatigue

Midday fatigue is a frequent complaint in inflammatory arthritis. The presence of overwhelming fatigue is also extremely common with fibromyalgia.

Cracking and clicking of joints

Joint clicking is usually a benign phenomenon and does not aggravate disease or progressive degeneration. Crepitus however may be felt especially with mechanical change or cartilage irregularity.

Constitutional symptoms

This includes fever, sweats and loss of appetite and weight, as seen in inflammatory arthritis, but may be seen in systemic diseases or malignancy.

Systematic inquiry

Inquire about skin rashes, especially psoriasis, photosensitivity or Raynaud's disease. Mouth and genital ulcers, diarrhoea or genitourinary infections may provide clues to spondyloarthritis. There is a close relationship between several rheumatic diseases and the eye, including Sjögren's or inflammatory disease.

Impact on daily life

Inquire about the effect on daily life and other psychosocial effects.

Function can be graded as follows:

- Grade 1 – fully independent
- Grade 2 – able to do most things
- Grade 3 – able to manage self-care
- Grade 4 – dependent for care.

Various scales, such as the health assessment questionnaire (HAQ), are derived for rheumatoid arthritis. Occupational history is also required.

THE EXAMINATION

Differentiate between articular and extra-articular source. Every joint should be assessed individually, and soft-tissue and contractile structures around the joint examined. The technique requires the classic 'look - feel-move' approach of Apley and application of the concept of the capsular pattern of Cyriax.

Look

- Gait
- Swelling
- Redness in joints or tendons
- Skin changes - examine for psoriasis, Raynaud's phenomenon, ulceration of skin and rashes
- Wasting of regional muscles
- Deformity or contractures.

Feel

Palpate the margins of each joint. Synovial thickening is felt as a 'soft spongy' texture with the additional presence of fluid identified by fluctuant swelling. Each joint is palpated in turn and the presence or absence of synovial thickening is recorded.

Move

This technique is the most useful in localising the pathology. There are three techniques of movement in the joint examination.

- **Active movement.** The patient uses his/her own muscles and contractile structures to move a particular joint through its range of movement. This tests the joint as well as the contractile structures.
- **Passive movement.** Here the patient is encouraged to relax and the examiner moves the joint through its accepted range of movement. By ensuring that the joint muscles are relaxed, this checks the actual joint capsule itself. The joint range of movement may be found to be reduced. This suggests age-indefinite involvement of the joint. Reproduction of the pain on passive movement confirms the joint as

Table 1. **History of the presenting complaint**

| |
|------------------------------------|
| Onset |
| Progression |
| Distribution of disease |
| Description of complaint |
| Presence of complaint |
| Presence or absence of stiffness |
| Timing of stiffness or pain |
| Duration of pain or stiffness |
| Aggravating or relieving factors |
| Presence or absence of fatigue |
| Impact of complaint on function |
| General systematic medical history |
| Past medical and surgical history |
| Family history |
| Medication history |
| Allergic history |

source of the complaint. If the pain is not reproduced by movement within the capsular pattern, then the cause lies elsewhere.

- **Resisted movement.** This isolates the cause to a particular tendon or bursa. The joint is made to relax, then force is applied by the patient against resistance of the examiner. Reproduction of the pain confirms the source to be the contractile soft-tissue structure.

The capsular pattern is a range of movement that is affected by disease of the joint. In the case of active joint inflammation, passive movement in the capsular pattern will be painful. Should the complaint be reproduced in this manner, then the joint itself is the source of the pain. Restriction in the capsular pattern suggests age-indeterminate disease of that joint (Table II).

Hand

Examine all the hand and thumb joints (Fig. 2). Note swelling and range of movement. The finger flexor tendons are then examined by feeling the tension in the pulps at the base of each finger. Tightness suggests tenosynovitis (Saville sign). The flexors are palpated for nodules in the palm while flexing and extending the fingers. These nodules may cause locking.

Wrists

Palpate as a single bony unit for signs of swelling and range of movement. Restriction suggests an inflammatory arthritis. Hypermobility may be examined by extending the 5th finger to more than 90° and by moving the

thumb against the volar aspect of the wrist. Tendonitis of the abductor pollicis longus and extensor pollicis brevis; De Quervain’s syndrome, presents as thumb, wrist and forearm pain, and is checked by holding the thumb in a closed hand and stretching the tendon by adducting the wrist (Finkelstein’s test). Check for sensory signs and for tap tenderness over the median nerve, while extending the wrist – Tinel’s sign.

Elbow

Palpate the radial and ulna margins for synovial thickening. Palpate for nodules or tophi on the extensor surface of the elbows. Restriction, contracture or deformity is noted. Passive flexion and extension pain suggests elbow joint involvement. Lateral epicondylitis (tennis elbow) is tested by extending the wrist against resistance, with the arm extended at the elbow. Medial epicondylitis (golfer’s elbow) is tested by resisted flexion of the wrist with the arm extended. Bicipital tendonitis is found by flexing the supinated forearm against resistance, while palpating the tendon insertion at the elbow.

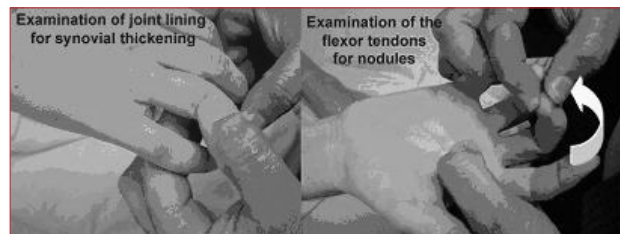

Fig. 2. Examination of the hand.

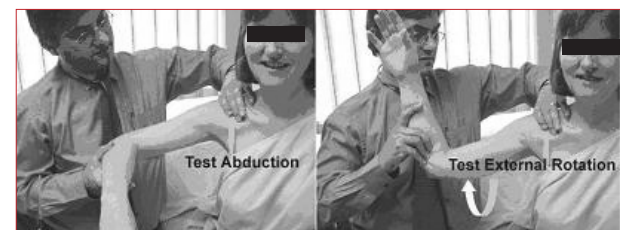

Fig. 3. Examination of the shoulder joint.

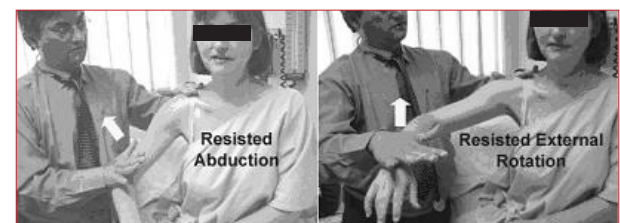

Fig. 4. Examination of the rotator cuff at the shoulder.

Shoulder

Painful passive movement in the capsular pattern – abduction and external rotation with or without restriction at the joint – suggests the shoulder joint as a cause of pain. The shoulder and scapula should be steadied when examining to ensure that the movement tested is glenohumeral (Fig.3).

Painful resisted abduction and external rotation is suggestive of rotator cuff disease (Fig. 4). The rotator cuff consists of the teres minor, supraspinatus, deltoid and infraspinatus muscles. This presents with pain at the shoulder, radiating down the outer aspect of the arm. Pain with abduction weakness may suggest a partial or full thickness tear of the tendon.

Global painful restriction of the shoulder of unknown aetiology is suggestive of adhesive capsulitis. The term ‘frozen shoulder’ applies to such restriction with underlying shoulder or rotator cuff pathology.

Resisted internal rotation tests subscapularis tendonitis. Resisted flexion of the supinated elbow with the shoulder in the neutral position tests biceps

Table II. The capsular pattern and normal range of movement

| Joint | Primary movement |
|----------|-----------------------------|
| Wrist | Flexion/extension |
| Elbow | Flexion/extension |
| Shoulder | Abduction/external rotation |
| Neck | All movement except flexion |
| Thoracic | Extension |
| Lumbar | Lateral flexion/flexion |
| Hips | Flexion/internal rotation |
| Knees | Flexion |
| Ankle | Plantar flexion |
| Subtalar | Varus |

tendonitis. Tenderness may be elicited in the bicipital groove.

Acromioclavicular joint

This presents with pain over the supraclavicular region. Test by passive movement of the shoulder to extremes of movement – especially abduction, external rotation and adducting the arm in front of the chest.

Cervical spine

Neck disease with root symptoms may radiate to the shoulder, but active shoulder movement will not affect pain arising from the neck itself. A neurological assessment is required. The neurocentral joints are most sensitive to extension, while the facet joints are most sensitive to lateral flexion and rotation.

Thoracic spine

Pain in the thoracic spine should always be properly assessed for cause. Feel for bony tenderness and pain on active and passive movement, including extension, lateral flexion and rotation. Chest expansion should be greater than 4 cm. Examination of the superficial muscles may reveal trigger points as seen in fibromyalgia.

Lumbar spine

Check for lordosis or loss of lordosis and scoliosis. Pelvic tilt may be noted and leg lengths should be measured from the anterior superior iliac spine to the medial malleolus at the ankle. A difference of 1 cm is acceptable. Forward flexion and lateral flexion may aggravate root symptoms, while extension will often aggravate symptoms of spinal stenosis. A positive straight leg-raising test suggests root entrapment.

Capsular joint problems, seen in inflammatory arthritis, produce symmetrical pain and restriction to all ranges of motion. Forward flexion is measured by the Shober test. A line is measured 10 cm above and 5 cm below the 'dimples of venus' and then remeasured in full flexion. The increase should be at least 5 cm.

Table III. **Acute disease**

| Acute monoarthritis | Acute polyarthritis |
|--|---|
| <p>Inflammatory Crystal disease Infectious disease Spondyloarthropathy Rheumatoid arthritis</p> <p>Mechanical/inflammatory Trauma Avascular necrosis</p> | <p>Infectious Bacterial HIV</p> <p>Non-infectious Rheumatoid arthritis Spondyloarthropathy Other connective tissue disease Crystal Sarcoid Hypertrophic pulmonary osteoarthropathy Malignancy/leukaemia Sickle cell</p> |

Hypermobility is tested by ability to flex and place the palms flat against the floor.

Sacroiliac joint

Palpate the joint itself, or apply lateral compression to the pelvis.

Hip joint

As a general rule, while spinal pain may radiate below the knee, hip pain will not. Observe the patient's gait. Pelvic tilt may reflect leg length shortening or compensation for hip or spine disease. With an antalgic gait, weight bearing occurs with the patient leaning to the diseased side. Weak abductors result in Trendelenburg's gait, with the pelvis tilting downward on the affected side.

Restriction in internal rotation is a sensitive method of assessing joint involvement (Fig. 5). The hip and knee are flexed to 90° with the patient lying flat, and the hip is rotated by holding the knee and moving the foot outward from the midline. This movement constitutes the capsular pattern and will reproduce pain for active hip joint involvement with or without restriction of range of movement.

Movement against resistance is used to detect soft-tissue problems (Fig. 6). Trochanteric bursitis presents with lateral thigh pain when lying on the affected side. It is detected by abducting the thigh against resistance.

Table IV. **Intermittent disease**

| Intermittent mono/polyarthritis |
|--|
| <p>Inflammatory Palindromic rheumatism Rheumatoid arthritis Polymyalgia rheumatica</p> <p>Mechanical Osteoarthritis Loose bodies Ligamentous/cartilage tears</p> <p>Crystal Gout Pseudogout Hydroxyapatite</p> <p>Infectious Lyme/TB</p> |

Palpation at the greater trochanter confirms tenderness. Ilio-psoas bursitis is detected as painful resisted flexion.

Knee

The knee is inspected for swelling, deformity and posteriorly for popliteal (Baker's) cyst (Fig. 7). Regional quadriceps atrophy is common in knee disease. Feel for heat or swelling in the joint. Swelling can be bony or soft with synovitis. Foreign bodies may be felt.

Test for knee stability. The lateral ligaments are tested by applying valgus

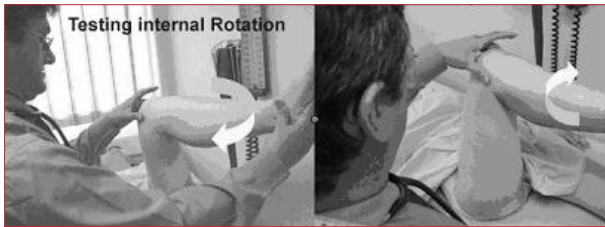


Fig. 5. Examination of the hip joint.

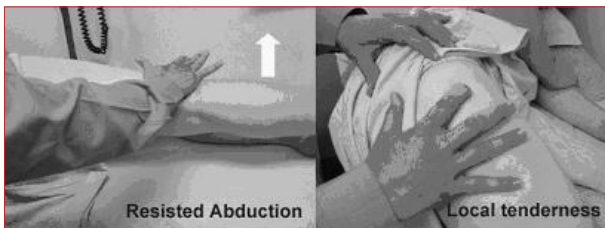


Fig. 6. Examination of the trochanteric bursa.

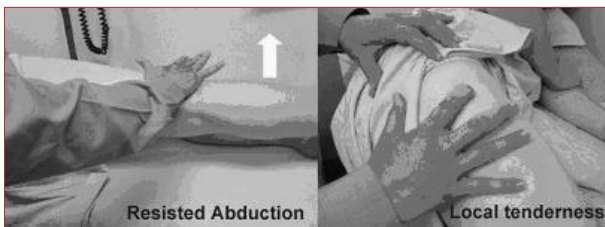


Fig. 7. Examination of the knee.

and varus stresses to the extended leg. The cruciates are tested using the 'drawer test'. The knee is flexed to 90° with the hip at 45°. The leg is held around the calf and the tibia pulled forward. More than 6 mm of movement suggests an anterior ligament tear. The tibia is pushed backwards and more than 6 mm of displacement suggests a posterior cruciate tear. Meniscus injury causes locking and clicking with mobility. The medial and

lateral margins of the joint may be tender and flexion of the knee to 90° while rotating the lower leg internally produces pain.

Examination of the soft tissues include the supra- and infra-patellar tendons which may be tender locally and aggravated by resisted knee extension. The anserine bursa is located medially below the joint margin and may exhibit local tenderness.

Ankle and subtalar joint

Inspect for swelling and deformity. Palpate for swelling

and examine the range of movement. Passive movement will test for regional inflammation of the ankle by flexing and extending the ankle and inverting and everting the subtalar joint.

The peroneal tendons are found laterally and extend the ankle and pronate the foot. The medial tendons plantar-flex the ankle and supinate the foot. Resisted movement tests the respective

tendons. Stability of the medial and lateral ligaments and derangement of the joint must be tested by weight bearing. The Achilles tendon is inspected and palpated locally for tenderness.

Tarsus

This is examined as a single unit. Inspect for deformity and swelling. Palpate for synovial or bony thickening, and check movement for tenderness and restriction. The plantar fascia is palpated at the calcaneus for local tenderness.

Toes

Inspect for deformity, nodules or bony or soft-tissue swelling. The capsular pattern consists of flexion and extension. Extension is the most sensitive. The metatarsals are examined successively for callus, synovial thickening or tenderness. The metatarsals can be tested by squeezing them together to elicit pain. Bony swelling or bunions are noted.

CONCLUSION

The history and examination provide the main information to making a diagnosis. The distribution of the problem, combined with the information regarding presence or absence of inflammation, are then correlated and interpreted. These, together with the pattern of presentation, are vital clues to the definitive diagnosis (Tables III, IV and V).

The severity of the problem is quantified and the effect on function and daily life is then factored to determine aggression of therapy. Analgesics do not alter the progression of inflammatory disease. The main focus of therapy should be aimed at early disease modification.

With the presence of increasingly familiar imaging techniques, early changes are visible on magnetic resonance imaging (MRI) that are otherwise seen as normal on radiographs. Normal laboratory tests and radiographs do not replace a good examination. The fundamentals of examination remain the cornerstone of rheumatology.

References available on request.

| Table V. Chronic disease | |
|--|--|
| Chronic monoarthritis | Chronic polyarthritis |
| <p>Inflammatory</p> <ul style="list-style-type: none"> Crystal Infectious – TB/fungal/Lyme Spondyloarthropathy Rheumatoid arthritis | <p>Inflammatory</p> <ul style="list-style-type: none"> Rheumatoid arthritis Spondyloarthropathy Other connective tissue disease |
| <p>Non-inflammatory</p> <ul style="list-style-type: none"> Osteoarthritis Avascular necrosis Mechanical derangement/loose body Neuropathic arthropathy Synovial proliferation – villonodular | <p>Mechanical</p> <ul style="list-style-type: none"> Osteoarthritis <p>Crystal</p> <p>Metabolic</p> <ul style="list-style-type: none"> Infiltrative/metabolic Hypothyroidism <p>HPOA/malignancy</p> |