

Case report

Beware of the rapidly rising creatinine in diabetic patients

A 73-year-old woman with a longstanding history of type 2 diabetes, complicated by hypertension and hypercholesterolaemia, presented to the casualty department with a 3-week history of malaise, worsening cough with dyspnoea and episodic minor haemoptysis. She had good glycaemic control; her most recent HbA_{1c} was 7.1.

Examination revealed a blood pressure of 160/85 mmHg, grade 1 hypertensive retinopathy and features of congestive cardiac failure (CCF), but mild pulmonary oedema. She did not have a peripheral neuropathy.

Biochemistry showed markedly abnormal renal function (Table I) and a normocytic anaemia (Hb 7.4, mean corpuscular volume 90.0). Ultrasound showed normal-sized kidneys. No urinalysis was documented. She was assessed as having worsening CCF and chronic renal failure secondary to longstanding diabetes and hypertension, and was admitted for symptomatic treatment and subsequently discharged.

A month later her symptoms had worsened and her creatinine had doubled (Table I). She was admitted to the renal unit with a similar clinical picture. Urinalysis showed an active urine with blood, red cell casts and heavy proteinuria. Renal biopsy showed fibrocellular crescents and little evidence of diabetic glomerulosclerosis (Fig. 1). Serology results showed a markedly elevated p-ANCA (352). ANCA-associated rapidly progressive glomerulonephritis was diagnosed and she was immediately started on corticosteroids and cyclophosphamide. Despite immunosuppressive therapy and acute dialysis, there was no improvement in renal function.

This case illustrates the importance of being aware of non-diabetic renal disease in the diabetic patient (incidence between 10% and 30%).

Diabetic nephropathy shows:

- strong concordance with retinopathy and neuropathy
- the hallmark finding of an inactive urine with heavy proteinuria.

Diabetic patients with rapidly deteriorating renal function, in the setting of good glycaemic control, the absence of diabetic

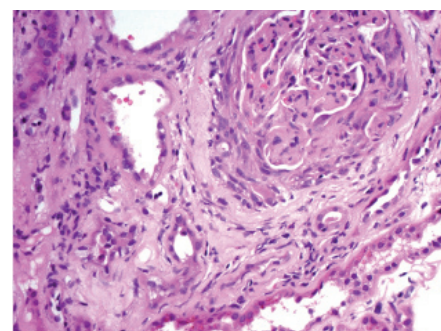


Fig. 1. Biopsy demonstrating fibrocellular glomerular crescent.

retinopathy and an active urine (blood and cellular casts), warrant further investigation for non-diabetic and potentially treatable renal diseases. Early identification and treatment is essential as outcome is dependent upon initial glomerular filtration rate and extent of chronic histological changes at biopsy.

J G PETER, MB ChB

C R S SWANEPOEL, MB ChB, FRCP (Edin)

Division of Nephrology
Department of Medicine
University of Cape Town and
Groote Schuur Hospital

Table I. Renal function

Date	10/01/05	27/06/05	03/05/06	29/05/06	12/06/06	13/06/06
Urea	7.3	9.1	17.8	29.8	30.4	31.6
Creatinine	89	88	489	820	879	920