

MANAGEMENT OF VAGINAL DISCHARGE

Vaginal discharge may be entirely normal, or a sign of infection. In either case, it is a relatively common presentation in general practice and deserves some attention.



A A HOOSEN

MSc, MB ChB, MMed, FCPATH

Chief Specialist and Head

Department of Microbiological Pathology
MEDUNSA

Professor Anwar Hoosen is currently Head of the NHLS's Microbiology Laboratory for the Northern Branch. He has conducted numerous clinical trials and has a research interest in infectious diseases with special emphasis on sexually transmitted infections. He is a recipient of the NRFs grant for research in sexually transmitted diseases and is also the principal investigator for a phase III vaginal microbicide study to be conducted at GaRankuwa and Soshanguve.

The normal anatomy, physiology and microbial ecology of the vagina are age-dependent as are the sources of vaginal infections. In the neonatal period, the vagina is influenced by maternal oestrogen and has a stratified squamous epithelium. Later, and until puberty, the vagina is lined by cuboidal cells and the pH is around 7.0. Following puberty, oestrogen causes a change to stratified squamous epithelium. The predominant microbial flora at this age are lactobacilli such as *L. crispatus* and *L. jensenii*, which produce lactic acid, and the pH falls to 4.0 - 4.5. The other vaginal flora include diphtheroids, β -haemolytic streptococci, coliforms and coagulase-negative staphylococci.¹

VAGINAL DISCHARGE IN PRE-PUBERTAL GIRLS

Vaginal symptoms including a discharge in pre-pubertal girls ought to be investigated microbiologically as the sexually transmitted (ST) pathogens *Neisseria gonorrhoeae* and *Chlamydia trachomatis* may be isolated.²

Other non-ST pathogens include β -haemolytic streptococci Group A (*S. pyogenes*), *Shigella flexneri* and *Enterobius vermicularis*.

VAGINAL DISCHARGES IN POST-PUBERTAL WOMEN

Vaginal infection is one of the top 25 reasons for women to consult doctors in the USA. The 3 most common types of vaginal infections include bacterial vaginosis, trichomoniasis and candidiasis and these may or may not be associated with cervical infection. Other vaginal syndromes are due to chemical toxins or physical agents (Fig. 1).

VAGINAL DISCHARGE IN POSTMENOPAUSAL WOMEN

In this age group, the vaginal epithelium becomes thin along with an increase in pH. Besides ST pathogens, a number of chronic vulvovaginal syndromes occur. An important one is desquamative inflammatory vaginitis, a syndrome associated with purulent vaginal discharge, vaginal cell exfoliation, increase in pH and Gram-positive cocci being observed in vaginal fluid. This syndrome responds to 2% clindamycin cream intravaginally.³

VAGINAL DISCHARGE IN ADULT WOMEN

Of the 3 common infective causes of vaginal discharge, bacterial vaginosis is the commonest. However, in certain populations trichomoniasis may be as common. Yeast infections also occur commonly and host factors ranging from genetic to acquired such as pregnancy, diabetes mellitus, use of corticosteroids, immunosuppressive therapy and systemic antimicrobials may predispose to colonisation and infection.

A summary of the symptoms, signs and diagnostic features of common vaginal infections in adult women is presented in Table I.

Vaginal symptoms including a discharge in pre-pubertal girls ought to be investigated microbiologically as the sexually transmitted (ST) pathogens *Neisseria gonorrhoeae* and *Chlamydia trachomatis* may be isolated.

Of the 3 common infective causes of vaginal discharge, bacterial vaginosis is the commonest. However, in certain populations trichomoniasis may be as common. Yeast infections also occur commonly and host factors ranging from genetic to acquired such as pregnancy, diabetes mellitus, use of corticosteroids, immunosuppressive therapy and systemic antimicrobials may predispose to colonisation and infection.

Bacterial vaginosis

Bacterial vaginosis (BV) is the result of overgrowth of the resident vaginal flora, which comprises *Gardnerella vaginalis*, *Mobiluncus*, *Bacteroides*, and *Prevotella* species and *Mycoplasma hominis*. There is simultaneous loss of the normal resident lactobacilli of the vagina. There is no inflammation of the vaginal epithelium and therefore BV represents a change in the vaginal ecosystem. The cause for this overgrowth is unknown. It is felt that normal vaginal lactobacilli are hydrogen peroxide (H₂O₂)-producing and this restricts proliferation of the organisms associated with BV. A loss in H₂O₂-producing lactobacilli leads to the development of BV.

The bacterial overgrowth in BV results in production of amines by anaerobes and when potassium hydroxide is added to the vaginal fluid, a typical fishy odour is produced. The bacterial amines together with organic acids such as acetic and succinic are cytotoxic leading to exfoliation of vaginal epithelial cells. *G. vaginalis* adheres to exfoliated epithelial cells and this creates shaggy-looking clue cells, which are a characteristic feature of BV.

BV was previously considered to be merely an inconvenience for women. However, there is increasing evidence linking BV with adverse outcomes in pregnancy, such as chorioamnionitis, preterm labour, prematurity and post-partum fever.^{4,5}

The diagnosis of BV is made using bedside tests fulfilling at least 3 of the following criteria:

- presence of grey, white homogeneous discharge
- positive amine test (addition of 1 drop of 10% KOH to 1 drop of vaginal secretions releasing a characteristic fishy odour)
- vaginal pH > 4.5 and presence of clue cells on microscopic examination of vaginal secretions or by performance of a Gram stain on vaginal secretions and using a scoring system proposed by Nugent *et al.*⁶ A score of 7 is diagnostic of BV; 3 is negative and 4 - 6 indicates an indeterminate diagnosis. Cultures of *G. vaginalis* do not offer any advantage for diagnosis, as they are positive in nearly 60 - 70% of women without infection.

Ampicillin has been used with some success. However, the drug of choice

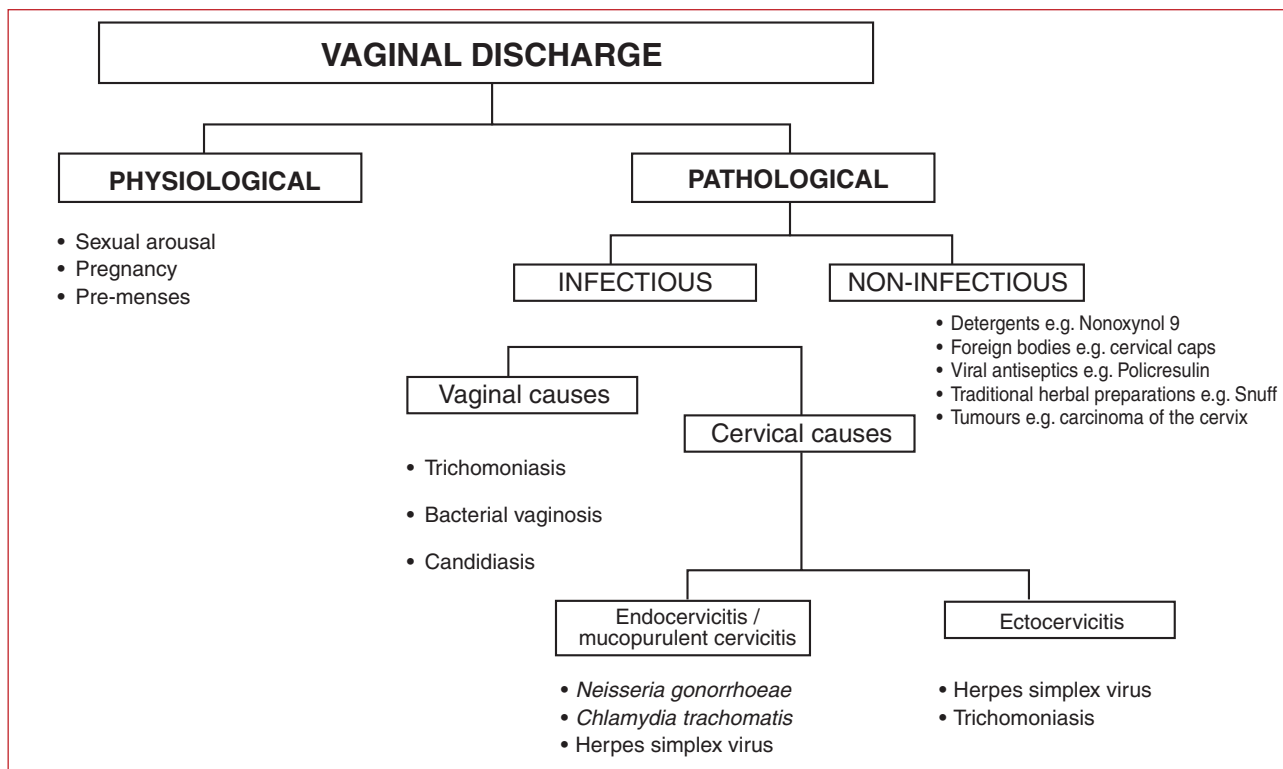


Fig. 1. Overview of the aetiology of vaginal discharge in adult women.

Table I. Diagnostic features of vaginal discharge in adult women

	Normal	Candidiasis	Trichomoniasis	Bacterial vaginosis
Microbiology	Mainly lactobacilli <i>L. jensenii</i> , <i>L. crispatus</i>	<i>Candida albicans</i> <i>C. glabrata</i>	<i>Trichomonas vaginalis</i>	Associated with <i>Gardnerella vaginalis</i> , <i>Mycoplasma hominis</i> , <i>Mobiluncus</i> species <i>Bacteroides</i> and <i>Prevotella</i>
Symptoms	None	Vulval itching and irritation	Purulent discharge	Malodorous discharge
Discharge characteristics • amount • colour • consistency	Scant/none Clear Non-homogenous	Scanty to moderate White Curd-like, adherent	Profuse Yellow Frothy	Moderate Grey/milky Homogenous, non-adherent
Vaginal epithelium	Normal	Erythema	Erythema	No inflammation
pH	Usually < 4.5	> 4.5	> 5.0	> 4.5
Amine/whiff test with 10% KOH	Negative	Negative	May be positive	Positive
Microscopy	Normal epithelial cells, lactobacilli	Leucocytes, epithelial cells, ovoid budding yeast and mycelia	Leucocytes, motile trichomonads	Clue cells, mixed flora predominantly Gram-variable bacilli including curved rods

is metronidazole (Table II). The majority of studies have shown better response and fewer recurrences with multiple-dose therapy, rather than a single 2 g dose.

The treatment of asymptomatic BV is recommended in pregnancy especially in women with poor obstetric histories.

Trichomoniasis

Trichomoniasis is a sexually transmitted infection (STI). The prevalence of trichomoniasis in South African women ranges from 5% to 49% in the different groups studied. Higher prevalences appear to occur in pregnant women. Being an STI, trichomoniasis commonly occurs together with gonorrhoea and chlamydia.

The main vaginal defence mechanism is production of local vaginal leucocytes, which attempt to kill the causative agent. The virulence mechanism of *Trichomonas vaginalis* is poorly understood and it is felt that the pro-

tozoan destroys epithelial cells by direct contact.

The clinical features of infection range from asymptomatic to profuse malodorous vaginal discharge. The characteristic feature is a frothy greenish-yellow, purulent discharge. The vaginal walls are erythematous and in severe infection, punctuate haemorrhages on the ectocervix give the cervix a strawberry appearance. Untreated trichomoniasis in pregnancy may predispose to premature rupture of membranes.

Diagnosis is by demonstration of the organism by wet smear microscopy or staining techniques such as acridine orange, Giemsa, etc. or by culture in media such as modified Diamond's. Wet smear microscopy relies on visualisation of flagellated, pear-shaped protozoa with their characteristic jerky movement in the presence of numerous leucocytes (Table I).

Treatment of trichomonal infection is with metronidazole or tinidazole. Metronidazole is the commonest nitroimidazole currently used for therapy. Oral therapy is preferred because there is concurrent infection of the urethra and periurethral glands. Single-dose therapy of 2 g oral metronidazole has shown cure rates of greater than 90% and is preferred as it ensures compliance. Disadvantages of the single-dose regimen are nausea, a metallic taste in the mouth, disulfiram-like effect with alcohol and also the need to treat sexual partners simultaneously. Treatment in early pregnancy is a problem because of the safety of metronidazole, and in such a setting the use of vaginal clotrimazole or povidone iodine may be beneficial.

Candidiasis

Prevalence studies from developed countries show yeast infections to be the second most common cause of vaginal infections while these appear to be the least common of the 3 main

Table II. Regimens for the treatment of bacterial vaginosis

Oral regimens
Metronidazole 400 mg po bid for 7 days 200 mg po tid for 7 days 2 g po as a single dose
Clindamycin 300 mg po bid for 7 days
Vaginal regimens
Clindamycin 2% vaginal cream, 5 g vaginally nightly for 7 days
Metronidazole* 0.75% vaginal gel, 5 g vaginally bid for 5 days
*Not available in South Africa.

causes of infection in women in developing countries. *Candida albicans* is the most common species of yeast isolated from the vagina ($\pm 90\%$) while *C. glabrata* and *C. tropicalis* are found less frequently. The germination of yeast forms enhances colonisation and tissue invasion. Pregnant women are predisposed to infection, especially in the third trimester, as are women on oral contraceptives, systemic antibiotics, corticosteroid or immunosuppressive therapy and those with uncontrolled diabetes mellitus.

The common presenting symptom is vulval itching and irritation. There

may also be soreness, vulval burning, dyspareunia and dysuria.

Recurrent candidal vaginitis may be due to a number of factors but it is difficult to identify the exact precipitating mechanism. More than one host factor may be involved and there is no evidence of defect in local immunity. For the prevention of recurrent candidiasis in women using systemic antibiotics, an oral antifungal should be used weekly, e.g. 100 mg fluconazole.⁷

The discharge of candidiasis is curd-like and adherent due to direct hyphal invasion of epithelial tissues resulting

in erythema of the vaginal epithelium. Clinical diagnosis is easily confirmed by doing a wet saline mount or 10% potassium hydroxide (KOH) preparation (Table I). Cultures may be performed in cases where microscopy is negative.

For the management of vulvovaginal candidiasis various topical formulations such as creams, pessaries, tablets, ovules, etc. are available. There is no evidence favouring any particular formulation or any particular azole preparation. However, in the presence of vulval inflammation local application of a cream is beneficial. There is also a marginal benefit of using azole preparations over the polyene, nystatin. For ensuring compliance, there is a trend towards using higher antifungal doses for a shorter duration. Some commonly available preparations are shown in Table III.

The oral agents for the treatment of vulvovaginal candidiasis include ketoconazole (400 mg for 5 days), itraconazole (200 mg bd for 1 day) and fluconazole (150 mg single dose).⁷ The latter is the only single-dose regimen recommended. These agents may be preferred by patients for convenience but should not be prescribed in pregnancy. Ketoconazole has been associated with hepatotoxicity and caution should be exercised when using this agent.

Women who have recurrent vulvovaginal candidiasis may have predisposing factors, which need to be addressed. However, in many women with recurrent infection, no underlying or predisposing factors are identified. These women are best managed with long-term suppressive prophylaxis and this may be achieved with a weekly dose of 100 mg fluconazole or weekly vaginal insertion of 500 mg clotrimazole.

CERVICITIS

Cervicitis implies an infection of the cervix and this may be either an ectocervicitis due to ST pathogens such as

Table III. Commonly available topical treatment regimens for vaginal candidiasis

Agent	Formulation	Regimens
Clotrimazole	Vaginal cream, tablets	5 g nightly for 6 - 12 days 2 tabs (200 mg) nightly for 3 days Single dose 500 mg
Miconazole	Vaginal cream, capsules	200 mg capsule or 5 g cream nightly for 7 days Single dose 1 200 mg capsule
Econazole	Vaginal cream, ovules	50 mg ovule/night for 14 days 150 mg ovule/night for 3 days Depot ovule 150 mg single dose
Nystatin	Vaginal cream, tablets	1 tablet/day for 14 days 4 - 8 g cream/night for 14 days

Table IV. Diagnostic tests for confirmation of endocervicitis

	<i>Neisseria gonorrhoeae</i>	<i>Chlamydia trachomatis</i>	Herpes simplex virus
Culture	Gold standard	Sensitivity varies and at best 60 - 70% accurate	Gold standard
Antigen tests	Not accurate, poor sensitivity	Variable, some tests showing 70 - 80% accuracy	Fairly accurate, but not widely used
Molecular tests	Commercial assays e.g. PCR and strand displacement assay (SDA) available and currently recommended as tests of choice for <i>C. trachomatis</i> diagnosis. Can also be performed on non-invasive specimens such as initial stream of urine and self-administered swabs		No commercial assay on the market yet

herpes simplex virus or *T. vaginalis* or an endocervicitis also called mucopurulent cervicitis (MPC) due mainly to *N. gonorrhoeae* and *C. trachomatis*. The presence of a purulent exudate from the cervical os has been highly associated with *N. gonorrhoeae* and *C. trachomatis* infection. An important pathogen which also infects the cervix is the human papillomavirus but this is not associated with cervicitis.

The risk factors for endocervical infection are the same for all ST pathogens, namely young age, unmarried persons, lower socioeconomic status, increased number and recent changes in sexual partner, prostitution and drug use. Cervicitis may be asymptomatic and detected only during speculum examination, or it may be recognised in the presence of concurrent vaginal discharge. However, occasionally mucopurulent cervicitis may produce a vaginal discharge on its own. A clinical diagnosis may be helped by detecting friability of the cervix or contact bleeding when examining with a swab and with the visualisation of a greenish-yellow exudate. The two-swab test has also been proposed for symptomatic women, i.e. the use of the first swab for removal of cervical mucus and insertion of the second swab into the endocervical canal, then removing it and observing for a colour change against a white background.

The laboratory test for diagnosing MPC is based on a simple Gram stain of the cervical exudate, which yields

≥ 30 polymorphonuclear cells per high-power field. To detect the underlying cause one has to use more definitive tests such as culture, antigen detection and molecular assays such as DNA probe tests and polymerase chain reaction (PCR). The diagnosis of gonococcal infection can easily be made with culture, but for diagnosing chlamydial infection, culture alone is not sensitive. The newer molecular tests such as PCR are popular as they are more sensitive, specific and even allow for testing on non-invasive specimens such as urine, self-administered swabs and tampons (Table IV).

Antimicrobial agents currently recommended for the management of endocervicitis or mucopurulent cervicitis are as follows:

- For *N. gonorrhoeae* — either a quinolone in a single-dose regimen, e.g. ciprofloxacin 500 mg, ofloxacin 400 mg or a parenteral preparation, e.g. ceftriaxone 125 mg as an intramuscular injection.
- For *C. trachomatis* — oral preparations of a macrolide, e.g. erythromycin 500 mg qid for 7 days or tetracycline, e.g. doxycycline 100 mg bd for 7 days or a single 1 g dose of azithromycin.
- For herpes simplex infection — acyclovir 400 mg tid for 10 days for a primary episode and for 5 days for recurrence, or valaciclovir 500 mg bd for 10 days and for 5 days for recurrence.

MANAGEMENT PROTOCOL

Comprehensive investigation and management

All patients with a complaint of vaginal discharge ought to have a speculum examination to determine whether the vagina alone or the vagina and cervix are affected. This also assists in specimen collection for bedside and laboratory tests. These investigations and the respective management strategies have been discussed above.

Syndromic management

In view of the inability to carry out extensive, comprehensive assessment of patients presenting to primary health care facilities in many public health clinics, there is a dire need to provide adequate care in an organised, structured manner. Syndromic management has been widely advocated world-wide for developing communities, and allows management of patients at the time of first contact, ensuring treatment of the most likely causes. This also allows time to comply with the 4Cs for prevention of STIs: counselling, condom promotion, contact management and encouraging compliance.

The protocol for syndromic management of vaginal discharge according to the National Department of Health (Directorate for HIV/AIDS and STDs) is presented in Fig. 2.

References available on request.

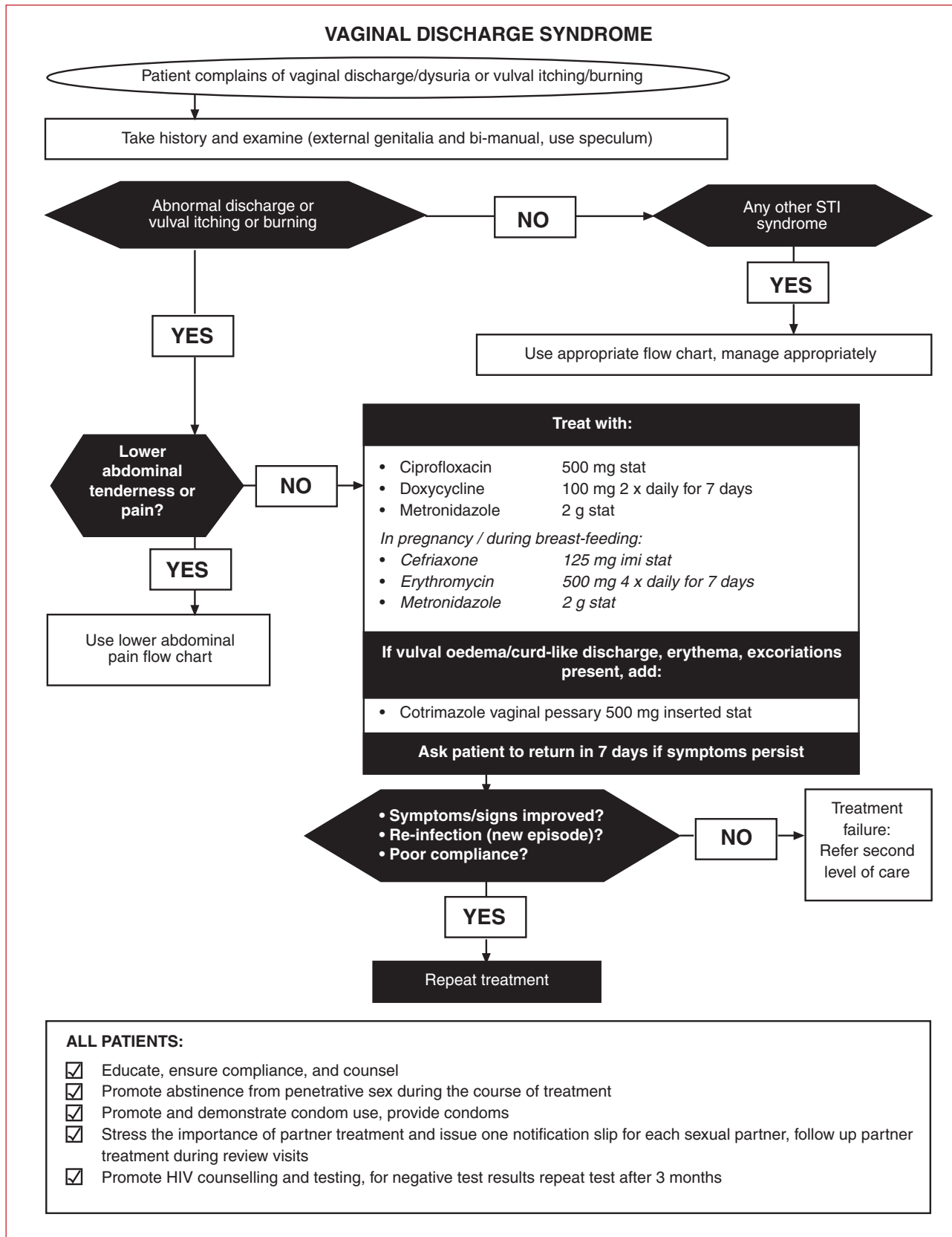


Fig. 2. Protocol for syndromic management of vaginal discharge.

IN A NUTSHELL

Vaginal discharges are a common problem in adult women.

The discharges may be physiological or pathological.

The common pathological causes are due to infection occurring in the cervix (cervicitis) or in the vagina (vaginitis and vaginosis).

The common causes of endocervicitis are the sexually transmitted pathogens of *Neisseria gonorrhoeae* and *Chlamydia trachomatis*.

The important causes of vaginal infection are trichomoniasis due to *Trichomonas vaginalis*, candidiasis due to *Candida albicans* and bacterial vaginosis due to proliferation of endogenous vaginal flora of *Gardnerella vaginalis*, anaerobes and *Mycoplasma hominis*.

Bedside tests of pH determination, whiff test and wet smear microscopy can easily diagnose vaginal infection.

Laboratory tests are required to confirm the causes of endocervicitis or mucopurulent cervicitis (MPC).

Syndromic management of vaginal discharge attempts to treat both cervical and vaginal causes.

Syndromic management is widely acclaimed for use in developing communities as it covers the common causes of infection at the point of first contact.

SINGLE SUTURE

CANNABIS RELIEVES SYMPTOMS OF MS — BUT ONLY JUST

In what has been described as a 'limited victory for medical cannabis' Zajicek and colleagues have published a paper in *The Lancet* which claims that cannabis relieves the subjective symptoms of multiple sclerosis (MS). Patients with MS received either a delta-9-tetrahydrocannabinol (THC), or cannabis extract or placebo. Standard objective tests to measure spasticity suggested that the drugs were no more effective than placebo. But, 60% of patients receiving cannabis reported improvements in spasticity compared with 46% on placebo. Pain relief was also an important effect noted by those on cannabis.

As Zajicek points out, there is now as much evidence to support the use of cannabis as there is for more conventional treatments such as baclofen. *The Lancet* asks the question — will attitude continue to limit the use of cannabis? Difficult to say, particularly when use and possession of cannabis is still illegal in most countries.

Zajicek J, et al. *Lancet* 2003; **362**: 1517-1526.