

# VII NERVE PALSY — EVALUATION AND MANAGEMENT

*The eye cannot close and constantly weeps. The mouth dribbles, the speech is interfered with and mastication impaired. The delicate shades of continence are lost. Joy, happiness, sorrow, shock, surprise, all conditions have for their common expression the same blank stare. (Brunnell, 1927<sup>o</sup>.)*



## SHAMLAN K NAIDOO

MB BCh, FCORL (SA)

### Consultant Otorhinolaryngologist

Department of Otorhinolaryngology and

Head and Neck Surgery

Nelson Mandela School of Medicine

University of KwaZulu-Natal

Durban

*Shamlan Naidoo is a consultant otorhinolaryngologist in the Department of Otorhinolaryngology and Head and Neck Surgery at the Nelson Mandela School of Medicine, King Edward VIII and Inkosi Albert Luthuli Central hospitals. His interests are head and neck surgery and otology.*

Facial nerve palsy is a devastating and readily visible nerve injury. Loss of tone and movement is disfiguring and causes a functional disability to eye closure, chewing, speech and facial expression.

The prevalence of facial palsy in the general population is about 1:5 000, making it a common-enough clinical entity for all general practitioners to be familiar with.<sup>1,2</sup> In most cases no definite aetiology is identified (idiopathic/Bell's palsy). The diagnosis of an idiopathic palsy however can only be made by excluding all other potential causes of facial palsy. The routine assumption that *all* facial palsies are idiopathic means that many correctable causes, e.g. of otological origin, might be left too late to achieve any favourable outcome.

## ANATOMY

The facial nerve leaves the brainstem and enters the internal auditory canal with the auditory nerve. Within the temporal bone it has three branches:

- greater superficial petrosal nerve — to lacrimal glands and glands within nasal and palatal mucosa
- chorda tympani — to taste buds and anterior two-thirds of the tongue
- stapedia nerve — stapedius muscle in middle ear.

As it exits the skull, it divides into branches within the parotid gland to supply the muscles of facial expression.

## AETIOLOGY

Facial paralysis is a diagnostic challenge, with a wide differential diagnosis (Table I). Nevertheless, every effort must be made to determine a treatable cause.

### Idiopathic/Bell's palsy

Between 50% and 80% of all facial paralysis is idiopathic.<sup>2,3</sup> There is no sex predilection but the incidence rises in pregnant women. Bell's occurs at any age, with a slight preponderance in patients over 65 years. Ten per cent may be bilateral.<sup>3,4</sup> Although idiopathic, compelling research supports an infectious cause, namely herpes simplex virus.<sup>5</sup>

Typically, sudden-onset unilateral facial paresis progresses to paralysis over 1 - 5 days.<sup>3</sup> The prognosis for Bell's is generally good, with most patients (85 - 90%) recovering completely within 1 month.<sup>2,3</sup> The remaining 15% will not usually show signs of recovery for 3 - 6 months.<sup>2,3</sup> A protracted recovery over a period of months increases the likelihood of sequelae such as facial weakness, tics, spasms and synkinesis.

The palsy is not Bell's if there is/are:

- signs of trauma
- vesicles on the head and neck
- multiple cranial nerve involvement

Table I. Differential diagnosis of facial nerve palsy

Idiopathic	Tumours	Systemic/metabolic
Bell's palsy Melkerson-Rosenthal	Parotid Cholesteatoma CP angle tumour Glomus Carcinoma (1°/2°) Facial nerve neuroma Leukaemia	Diabetes mellitus Pregnancy Sarcoidosis Autoimmune disorders Porphyria
Trauma	Congenital	Infection
Temporal bone fractures Iatrogenic injury Birth trauma Facial injuries Penetrating wounds to the ear Barotrauma	Compression injury Mobius syndrome Dystrophia myotonica	Herpes zoster oticus Otitis media Mastoiditis Diabetic otitis externa TB Lyme disease HIV Infectious mononucleosis

- otological infection
- other CNS lesions
- facial palsy at birth.

### Trauma

Trauma is the second most common cause of facial nerve paralysis. These patients may present with bloody otorrhoea, haemotympanum, dizziness and deafness. Longitudinal fractures of the temporal bone comprise 80% of all temporal bone fractures and facial nerve injuries occur in 10 - 20% of these. Transverse fractures comprise only 20% of fractures, yet the incidence of facial nerve injuries is 50%.<sup>4</sup> Other causes of traumatic paralysis include iatrogenic, birth canal trauma/forceps delivery, penetrating parotid or middle ear trauma and facial fractures.

### Infections

The most common cause is herpes zoster oticus (Ramsay-Hunt syndrome). Reactivation of the varicella zoster virus causes severe otalgia, deafness, facial paralysis and a vesicular eruption on the ear, face, neck or oral cavity. Patients may also have varying degrees of deafness and vestibular symptoms. Only about 50% of patients regain normal facial function. Other infections include TB, otitis media, otitis externa, syphilis, Lyme disease, etc.

Facial paralysis as a complication of HIV infection has been reported, particularly in the early stages of HIV and occasionally as the first manifestation of the infection.<sup>6</sup>

Acute otitis media with a dehiscent facial canal in the middle ear can lead to inflammation along the nerve, causing paralysis. Chronic otitis media may also cause facial paralysis secondary to cholesteatoma or inflammation of the nerve.

Facial palsy in children is TB otitis media until proven otherwise. By no means does this infer that TB treatment should be commenced without an ENT assessment to exclude life-threatening causes like cholesteatoma or leukaemia.

Malignant/diabetic otitis externa is a life-threatening osteitis of the temporal bone, causing facial palsy and otalgia, usually due to *Pseudomonas aeruginosa*. The diagnosis is made on clinical suspicion in susceptible patients (diabetics, immunosuppressed, patients on chemotherapy, etc.), and is confirmed by a positive bone scan.

### Tumours

About 5% of facial nerve palsies are due to tumours — parotid tumours,

cholesteatoma, facial nerve neuroma, ear and cerebellopontine angle (CPA) tumours.<sup>2,4</sup> Suspicious symptoms include slowly developing paresis over a period of more than 3 weeks, facial twitching, other cranial nerve deficits, recurrent ipsilateral paresis and a parotid mass.

The most common malignant tumours causing facial paralysis are mucoepidermoid and adenoid cystic carcinomas of the parotid.

## CLINICAL EVALUATION

### History

A thorough history is paramount to narrowing the differential diagnosis:

- onset of palsy (sudden/delayed)
- duration and rate of progression
- complete or incomplete palsy
- associated symptoms (hearing loss, otorrhoea, otalgia, vertigo, vesicles, CNS symptoms)
- medical history (diabetes, pregnancy, CVA, previous ear/parotid disorders)
- history of trauma or previous surgery (e.g. ear, parotid).

### Examination

A complete head and neck examination, including assessment of the ears, parotids, eyes (keratitis), upper aerodi-

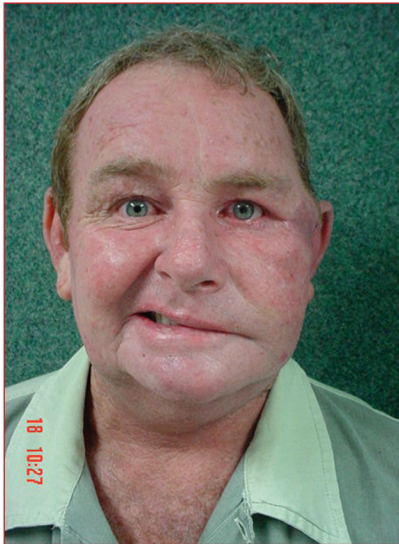

Fig. 1. Lower motor neuron lesion.

gestive tract and neurology (cranial nerves) is mandatory. The next step is to assess whether the nerve injury is complete or incomplete, upper motor neuron (UMN) or lower motor neuron (LMN):

- UMN lesions (e.g. CVA) — upper 3rd of the face is spared
- LMN lesion — weakness or paralysis of the entire face (Fig. 1).

Typical findings in peripheral nerve palsy:

- At rest — less prominent wrinkles on the affected side, eyebrow droop, flattened nasolabial folds, and corner of the mouth turned down.
- Inability to wrinkle forehead, raise eyebrows, purse lips, show teeth, or whistle. Eye closure may be incomplete.

As a rule all LMN facial palsies will require an ENT referral to complete the more specialised aspects of examination and investigation.

**INVESTIGATIONS**

Owing to the specialised nature of these studies this section will deal only briefly with which investigations are performed and why.

- All patients with facial paralysis require formal audiological testing (pure tone, air and bone conduction, speech, reflexes and tympanometry). Asymmetry on the audiogram warrants an MRI scan to exclude CPA lesions.
- Electrophysiological tests, e.g.

nerve excitability (NET), maximal stimulation test (MST), electroneurography (ENOG) and electromyography (EMG) are useful in patients who have complete paralysis to determine the prognosis for return of facial function.

- The once popular topognostic tests (Schirmer's, stapedial reflex, salivary flow assessment) are based on the principle that lesions distal to a branch of the facial nerve will spare the function of that branch. These are now considered to be of historical interest only and of little use in determining site of lesion, or in predicting outcome.
- Radiological evaluation — performed in patients with a history of recurrent paralysis, CNS symptoms, suspected CPA lesions, otological findings, history of trauma and in patients with delayed nerve recovery. Gadolinium-enhanced MRI is the procedure of choice to exclude CPA lesions or brain lesions. CT

provides excellent bony assessment of temporal bone fractures, the middle ear and mastoid.

- Other tests to exclude specific illnesses, e.g. diabetes, sarcoidosis, autoimmune disease, etc.

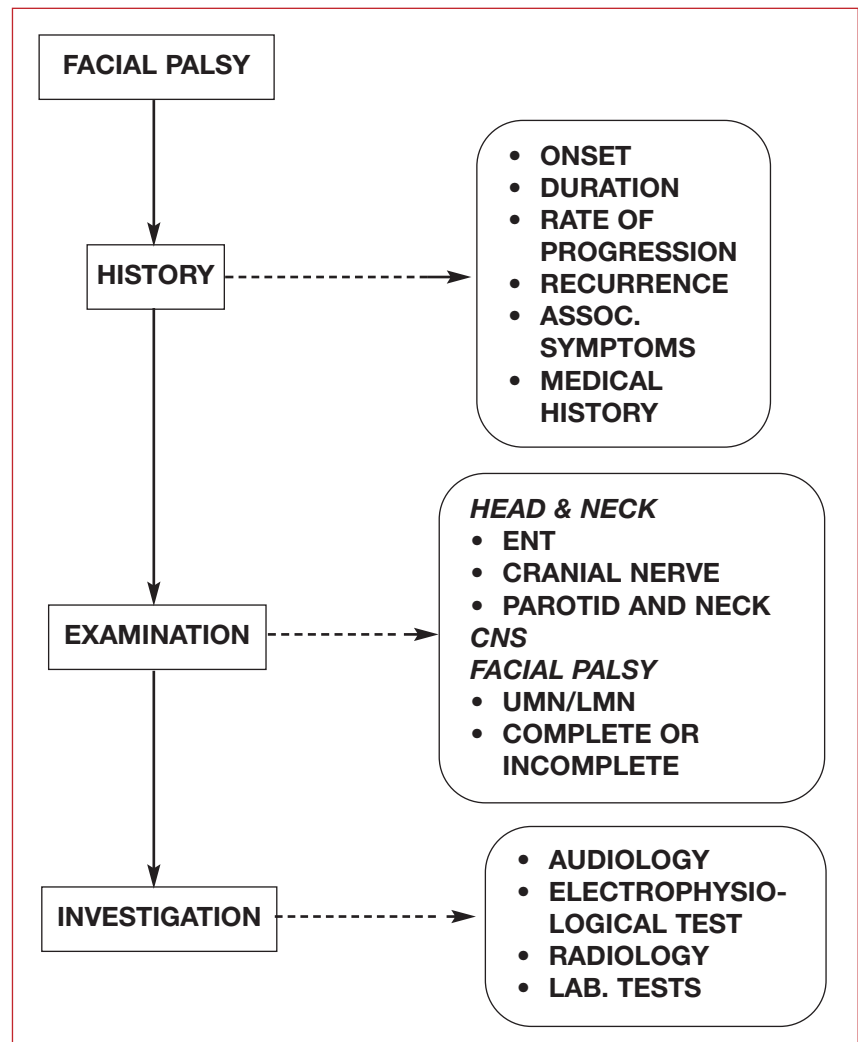
**MANAGEMENT**

Treatment of facial paralysis depends on its cause. The role of the emergency physician is to:

- provide adequate eye protection
- exclude obvious causes
- initiate appropriate therapy
- seek timeous ENT referral.

**Eye protection**

Poor upper eyelid closure and diminished lacrimation may lead to corneal dryness, punctate keratopathy, ulceration and ultimately decreased vision. Patients should use artificial tears liberally during the day, and close the eye with a patch after application of an eye ointment at night. They should avoid dust, and wear eye protection



*The prevalence of facial palsy in the general population is about 1:5 000, making it a common enough clinical entity for all general practitioners to be familiar with.*

*The routine assumption that all facial palsies are idiopathic means that many correctable causes, e.g. of otological origin, might be left too late to achieve any favourable outcome.*

*The prognosis for Bell's is generally good, with most patients (85 - 90%) recovering completely within 1 month.*

*Facial palsy in children is TB otitis media until proven otherwise. By no means does this infer that TB treatment should be commenced without an ENT assessment to exclude life-threatening causes like cholesteatoma or leukaemia.*

when outdoors (patch/glasses). Counselling and early aggressive treatment usually prevent complications, but if symptoms persist an ophthalmic consultation is advised. These measures are adequate for palsies of short duration.

In patients with delayed nerve recovery or permanent palsies, more permanent eye protection is required. Lateral tarsorrhaphy is successful in correcting mild lagophthalmos. In severe cases, a gold weight implant or upper eyelid spring is indicated.

### **Bell's palsy**

The treatment of Bell's remains controversial. The effectiveness of any med-

ical regimen in altering the natural history of the palsy (85 - 90% complete recovery in 1 month) remains unproven. Despite this, experts believe that early oral prednisone (1 mg/kg/day) may decrease degeneration, reduce synkinesis (mass movement), relieve pain, and promote earlier recovery.<sup>7</sup> Patients should be evaluated within 5 days of starting steroid therapy. If some function is present, taper the steroids over the next 5 days. If no improvement is noted, the full dose should be administered for 10 days, tapered over the last 5 days.

With mounting evidence implicating the herpes simplex virus, many clinicians cite the study by Adour *et al.*, using acyclovir and prednisone, claiming decreased neural degeneration.<sup>8</sup> Adour recommended prednisone (1 mg/kg/day) and acyclovir (200 mg 5 times daily) for 10 days.

Surgical decompression of the facial nerve in patients with Bell's palsy is controversial. It has not been shown to alter the natural history of the disease and is currently not favoured by most clinicians.

It must be emphasised that the diagnosis of Bell's can only be made when an otorhinolaryngologist has excluded all other causes of facial palsy. May *et al.*, in their study of 1 675 patients with 'Bell's palsy', found that 13% of patients had been incorrectly diagnosed.<sup>3</sup> A space-occupying lesion along the course of the facial nerve was discovered in 38% of patients.

### **Trauma**

In temporal bone fractures it is crucial that the onset (immediate/delayed) of the palsy is ascertained. A full head and neck, and neurological evaluation must be followed by close assessment of the facial palsy (complete/incomplete) and inspection of the external auditory canal (EAC) and tympanic membrane (T/M). Common findings in the ear are blood/laceration of the EAC, T/M perforation, ossicular disruption and haemotympanum.

Immediate complete facial paralysis with a demonstrable fracture on CT scan necessitates surgical exploration and repair of the nerve as soon as possible, after audiological and neurological assessments. In incomplete or delayed-onset palsies with temporal bone fractures, facial nerve testing is obtained on day 4. If advanced degeneration has occurred the nerve is surgically explored and decompressed.

Gunshot wounds of the temporal bone cause paralysis in about 50% of cases. The nerve may be transected or secondarily injured by kinetic energy from the bullet or by bony spicules. In complete paralysis surgical exploration and repair is undertaken when the patient is medically stable.

Following iatrogenic injury, the transected nerve must be repaired immediately. If paralysis occurs postoperatively and the surgeon is confident that the nerve was intact at the end of the operation, tight ear packing is removed and the patient is observed to allow local anaesthetic agents to wear off. The patient is re-assessed and if the palsy persists, high-resolution CT scan is performed to demonstrate the nerve, and electrical testing is conducted on day 4. If advanced degeneration is noted, the nerve is explored and decompressed or repaired. If there is any question about the integrity of the nerve, exploration is undertaken as soon as possible, preferably by another surgeon.

Penetrating facial injuries with immediate facial paralysis are usually explored and repaired as soon as possible.

### **Infection**

Herpes zoster oticus is characterised by severe otalgia, vesicular eruptions and varying degrees of deafness. These patients require an audiogram to assess hearing loss. Treatment is with acyclovir, 800 mg, 5 times per day, for 1 week, and potent analgesics.<sup>2,3</sup> The role of corticosteroids is controversial, due to the risk of herpes spread and meningoencephalitis.

Paralysis in acute otitis media is treated with myringotomy to drain the middle ear space, and antibiotics for Gram-positive cocci and *Haemophilus influenzae*. Facial paralysis with mastoiditis, however, is treated with intravenous antibiotics and surgical drainage (mastoidectomy). Nerve compression by cholesteatoma or inflammation in chronic otitis media necessitates a CT scan. These patients undergo mastoidectomy with facial nerve exploration and decompression.

Tuberculous otitis media is usually diagnosed by obtaining aspirates or biopsies from the middle ear. Chest X-rays often show no evidence of pulmonary tuberculosis. These patients are treated with systemic antituberculosis treatment. Only in some cases is surgery indicated to remove sequestra and improve drainage.<sup>4</sup>

Malignant otitis externa causing facial nerve palsy is a life-threatening condition. These patients are treated with a combination of intravenous piperacillin, amikacin and metronidazole until the bone scan is negative, usually 6 weeks.<sup>2,4</sup>

### Tumours

The management of facial nerve paralysis caused by tumours depends on the location, extent and malignant potential. It may include transposition

of the nerve, division and re-anastomosis, interposition grafting and facial nerve crossover. The misdiagnosis of a tumour somewhere along the course of the facial nerve, as a Bell's palsy is catastrophic. Findings not to miss are a slowly evolving facial paresis, facial twitching, middle ear mass or conductive deafness. A parotid mass with a facial nerve paralysis is malignant until proven otherwise.

### Facial palsy in the newborn

The broad differential diagnosis is either traumatic or congenital. In congenital paralysis patients are left untreated until late childhood when cosmetic surgery (muscle transfer/facial slings) is performed. Trauma is usually evident by facial contusion, ecchymoses over the mastoid, haemotympanum, etc. The patient with complete paralysis should undergo electrical testing of the facial nerve in the first 3 days after birth to ascertain the integrity of the nerve and to plan further treatment.

### CONCLUSION

Although Bell's palsy is the commonest cause of facial palsy, it is crucial that all causes are excluded to avoid overlooking life-threatening conditions. A thorough history and examination is essential to narrow the differential diagnosis.

The information in this article should provide the appropriate first steps in evaluation and management of facial palsies, and emphasises the importance of a specialist consultation.

*References available on request.*

### IN A NUTSHELL

Early and adequate eye care is paramount.

Bell's palsy — a diagnosis of exclusion! 'Bell's palsy' of longer than 3 months warrants re-evaluation.

Diagnostic clues in facial palsy:

- vesicles — Ramsay-Hunt syndrome
- parotid mass — consider malignancy
- children — TB (acute otitis media/cholesteatoma)
- diabetic — diabetic/malignant otitis externa
- trauma - fractured temporal bone.

Refer all facial palsies to an otorhinolaryngologist.