

are then applied to one or both ends of the wound to approximate it as any other linear incision and to avoid puckering (Fig. 6).

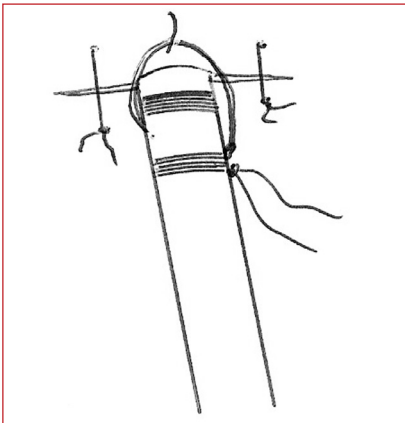


Fig. 6. Completed secure fastening.

For removal, the suture is cut just proximal to the knot. This will allow the anchoring stitch to be tied easily when the drain is removed.

**Conclusion**

Adequate anchoring of an intercostal drain is essential to avoid complications such as sepsis, patient discomfort, accidental dislodgement, creation of pneumothorax on removal, and unacceptable cosmetic results.

**Further reading**

Chan L, Reilly KM, *et al.* Complication rates of tube thoracostomy. *Am J Emerg Med* 1997; **15**(4): 368-370.  
 Gilbert TB, Mc Grath BJ, *et al.* Chest tubes: indications, placement, management and complications. *J Intensive Care Med* 1993; **8**(2):  
 Rashid MA, Wilkstrom T, Ortenwall P. A simple technique for anchoring chest tubes. *Eur Respir J* 1998; **12**: 958-959  
 Schmidt U, Stalp M, Maull K, *et al.* Chest tube decompression of blunt chest injuries by physicians in the field: effectiveness and complications. *J Trauma*; **44**: 98-100.  
 Simon RR, Bailey TD, *et al.* A new technique for securing a chest tube: *Ann Emerg Med* 1982; **11**: 619-621.

**TRAUMA IN PREGNANCY IN A NUTSHELL**

**KEN BOFFARD**, BSc (Hons), MB BCh, FRCS, FRCS (Edin), FRCPS (Glasg), FCS (SA), FACS

**Chief Specialist and Head:** Department of Surgery, Johannesburg Hospital

**Professor:** Department of Surgery, University of the Witwatersrand, Johannesburg

The risk to a fetus in pregnancy even in 'minor' or non-catastrophic trauma is still significant, with preterm labour occurring in 8%, abruption in 1% and fetal death in 1% of cases. In major trauma, the fetal death rate approaches 20%. Oxygen transport in the fetal placental unit is intimately tied to maternal blood flow. Because of the passive uptake of oxygen, fetal oxygenation is only as high as that in the uterine vein.

The patterns of injury to pregnant women differ slightly from those to non-pregnant women, with injuries to the abdomen more common than those to the head or chest. The ABCDE priorities of trauma management in pregnant patients are the same as those in non-pregnant patients.

Anatomical and physiological changes occur in pregnancy which are extremely important in the assessment of the pregnant trauma patient. These affect both the mother and the fetus.

**Anatomical changes**

- Size of the uterus gradually increases and it becomes more vulnerable to damage both by blunt and penetrating injury:
  - at 12 weeks of gestation the fundus is at the symphysis pubis
  - at 20 weeks it is at the umbilicus and
  - at 36 weeks at the xiphoid.
- At first the fetus is well protected by the thick-walled uterus and large amounts of amniotic fluid.

**Physiological changes**

- Increased tidal volume and respiratory alkalosis
- Increased heart rate
- 30% increased cardiac output
- Blood pressure usually 15 mmHg lower
- Blood volume higher than in the non-pregnant state
- Aortocaval compression in the third trimester with hypotension.

**Pitfall**

- Because the blood volume is higher, more bleeding will take place before shock intervenes. The volume of blood loss is commonly underestimated.
- Aortocaval compression must be prevented in resuscitation of the traumatised pregnant woman. If she is > 32 weeks pregnant, there is a danger of aortocaval compression and, if possible, she should be tilted in the left lateral position to prevent it.

**Special issues in the traumatised pregnant patient**

- Blunt trauma may lead to:
  - uterine irritability and premature labour
  - partial or complete rupture of the uterus
  - partial or complete placental separation (up to 48 hours after trauma)
  - severe blood loss potential with pelvic fractures.

It is not unusual in these patients, such is the severe mechanism of injury, for the equivalent of an entire blood volume to be lost. Unless this is anticipated, the resulting hypotension may result in the death of the fetus.

**What are the priorities?**

- Assessment of the mother according to the ABCDE.
- Resuscitation in left lateral position to avoid aortocaval compression.
- Vaginal examination (speculum) for vaginal bleeding and cervical dilatation.
- Marking of fundal height and palpation of tenderness.

- Monitoring of the fetal heart rate as appropriate.

### Conclusion

After injury in pregnancy, the key to a successful outcome for both mother and child is prompt and adequate initial resuscitation of the mother.

All patients with major trauma should be kept under observation for at least 24 hours.

They should be referred to an institution where they can benefit from a multi-team approach. Careful fetal monitoring is essential once fetal viability has been established.

Resuscitation of the mother may save the baby. There are times when the mother's life is at risk and the fetus may need to be sacrificed in order to save the mother. If resuscitation of the mother fails, urgent perimortem caesarean section may be useful with short CPR times.

## CHILD RESTRAINT — HOW WE DO IT!

**GRAEME J PITCHER, MB BCH, FCS (SA)**  
**Senior Specialist and Adjunct Professor:** *Division of Paediatric Surgery, Johannesburg Hospital and University of the Witwatersrand, Johannesburg*

**TIMOTHY N ROGERS, MB BCH, FCS (SA)**  
**Fellow in Paediatric Surgery:** *Division of Paediatric Surgery, Johannesburg Hospital and University of the Witwatersrand, Johannesburg*

Consideration for the safety of child passengers in motor vehicles is relatively recent. Only in the last 20 years has the necessity for child restraint in vehicles been recognised and effective devices become readily available. Most of today's medical practitioners were probably transported without restraint devices as children. In South Africa, the implementation of child restraint systems in vehicles has been

woefully slow and is further hampered by absence of appropriate enforcing legislation. Further complicating the situation is the rapid development of very sophisticated safety equipment aimed at protecting adult occupants from injury in the event of a collision. Air bags, in particular, have been shown to reduce the severity of injury to a correctly restrained adult passenger but are potentially lethal to infants and children who are in their proximity when they deploy and cause a now well-recognised pattern of injuries.<sup>1</sup>

Motor vehicle accidents are the leading cause of death among children older than 1 year. Seventy per cent of these fatalities occur in unrestrained children. The risk of death and non-fatal injury are markedly reduced in children who have been appropriately restrained.

It is the duty of all health care practitioners to provide accurate advice about child restraint to their patients. We describe practical guidelines for age-appropriate child restraint devices for those who are responsible for transporting children.<sup>2</sup>

### INJURY PATTERNS

Injury patterns related to the incorrect use of restraint equipment are now well recognised. Ejection is the most dangerous scenario and is associated with a dramatic increase in mortality<sup>3</sup> and severe injury, especially of the head. Other recognised injury complexes include:

#### The lap belt complex

This is caused by rapid forced hyperflexion of the upper torso against a fixed lower lumbar spine. Components are the following:

- typical transverse bruising of the belt over the lower abdominal wall
- bowel injury, typically to the duodenojejunal junction or other points of retroperitoneal fixation
- flexion — distraction injuries of the lumbar spine.

#### Air bag injury complex

Air bag deployment can cause severe injury, especially to young children.

The most dangerous scenario is the rear-facing infant in the front seat of a vehicle equipped with a passenger air bag. In this situation the air bag fractures the rear headrest of the child seat, often causing fatal head and neck injuries. Other typical air bag injuries are e.g. cervical spine injuries,<sup>4</sup> including atlanto-occipital dislocation, and blunt facial and thoracic injuries.

### Forward-facing infant injury complex

In this situation the infant tends to sustain rapid and severe cervical flexion and 'submarines' under the harness straps. Typically, head and flexion cervical injuries occur with liver and spleen injuries due to subcostal pressure of the harnesses.

### CHILD RESTRAINT RECOMMENDATIONS

Unlike the restraint systems used by adults, which are usually standard fittings, those required by children are usually purchased separately and must be installed by the owner. Also, unlike adult restraints where 'one size fits all', different restraint devices are required for children of different ages and sizes.

The purpose of any restraint system is to prevent ejection of the occupant from the vehicle and to minimise contact with the vehicle's passenger compartment in the event of a crash. Forces are distributed widely over the body's anatomically strongest components.

#### Below 10 kg

The child should always face the rear of the vehicle, secured in an appropriately sized car seat. Neonatal inserts are available to comfortably house even the smallest baby. These can be removed as the child grows. The seat should be tilted at an angle of 45° to ensure that the baby's head is adequately supported and that the forces are directed through the baby's back.

#### Above 10 kg

The child must be restrained in an appropriate car seat and may face